

Decompressive Craniectomy for Large Hemispheric Ischemic Stroke: Surgical Results in Nine Patients

Yousouf Sogoba¹, Seybou Hassane Diallo², Boubacar Sogoba¹, Moussa Diallo¹, Mamadou Diallo¹, Oumar Coulibaly³, Daouda Sissoko³, Mangané Moustapha Issa⁴, Alméimoune Hamidou⁴, Diop Thierno Madane⁴, Salimata Diallo², Drissa Kanikomo¹

¹Department of Neurosurgery, Gabriel Toure Teaching Hospital, Bamako, Mali

²Department of Neurology, Gabriel Toure Teaching Hospital, Bamako, Mali

³Department of Neurosurgery, Hospital of Mali, Bamako, Mali

⁴Department of Emergency and ICU, Gabriel Toure Teaching Hospital, Bamako, Mali

Email: sogobayoussouf@yahoo.fr

How to cite this paper: Sogoba, Y., Diallo, S.H., Sogoba, B., Diallo, M., Diallo, M., Coulibaly, O., Sissoko, D., Issa, M.M., Hamidou, A., Madane, D.T., Diallo, S. and Kanikomo, D. (2025) Decompressive Craniectomy for Large Hemispheric Ischemic Stroke: Surgical Results in Nine Patients. *World Journal of Neuroscience*, 15, 1-7.

<https://doi.org/10.4236/wjns.2025.151001>

Received: October 5, 2024

Accepted: December 20, 2024

Published: December 23, 2024

Copyright © 2025 by author(s) and Scientific Research Publishing Inc. This work is licensed under the Creative Commons Attribution International License (CC BY 4.0).

<http://creativecommons.org/licenses/by/4.0/>



Open Access

Abstract

Introduction: Stroke is a worldwide leading cause of mortality and disability, and there are substantial economic costs for post-stroke. A large hemispheric ischemic stroke is a severe form of stroke that may occur in up to 10% of stroke cases. In these cases, decompressive craniectomy (DC) is an effective strategy to reduce early case fatality. In this study, the authors present their experience in the management of large hemispheric stroke in patients who underwent decompressive craniectomy. **Patients and Methods:** This study is a retrospective analysis of 9 patients who underwent decompressive craniotomy for large hemispheric stroke from February 2021 to January 2024. Demographic, clinical, and radiologic variables were collected from the hospital archives. All patients underwent head CT scan or MRI showing the involvement of the majority or complete middle cerebral artery distribution area. Hemicraniectomy with duraplasty was the main surgical procedure. The mortality and the outcome using Modified Rankin Scale (mRS) were reported. **Results:** A total of 9 patients with large hemispheric stroke who underwent DC were reviewed retrospectively. The mean age was 53 years with extremes of 39- and 67-year-old. There were 6 males and 3 females. The main risk factors of stroke were hypertension and diabetes in 5 and 3 cases, respectively. The large craniectomy was made and the dura was opened in the stellate fashion. Duraplasty was performed using epicrane in 7 patients and fascia lata aponeurosis in 2 patients. In the postoperative course, 4 (44%) patients died in 1 month and the mortality rate was 66.6% in 6 months. **Conclusion:** Decompressive craniectomy is a life-saving procedure used to manage cerebral edema after stroke onset. In our

study, the high mortality rate could be explained by many factors, such as patient selection criteria and timing of surgery. Early surgery within the first 48 hours in patients less than 60 years old with large hemispheric stroke is recommended.

Keywords

Decompressive Craniectomy, Ischemic Stroke, Hemispheric Infarction

1. Introduction

Stroke is a worldwide leading cause of mortality and disability, and there are substantial economic costs for post-stroke [1]. A large hemispheric ischemic stroke is a severe form of stroke that may occur in up to 10% of stroke cases [2] [3]. Patients present with symptoms and signs of large hemispheric stroke syndrome, including hemiplegia and deteriorating consciousness in the first 48 hours resulting from raised intracranial pressure [4] [5]. With conservative medical treatment, there is an 80% mortality rate within the first week after stroke [6]. In these cases, decompressive craniectomy (DC) is an effective strategy to reduce early case fatality in the setting of uncontrolled intracranial hypertension due to brain swelling [7]-[13]. It can allow brain tissue to expand, consequently facilitating control of increased ICP and reducing the risk of herniation, which may improve the outcome of patients. This technique appears to offer a clear survival advantage, reducing the risk of death or severe disability [14]-[18]. In this study, the authors present their experience in the management of large hemispheric stroke in patients who underwent decompressive craniotomy.

2. Patients and Methods

This study is a retrospective analysis of 9 patients who underwent decompressive craniotomy for large hemispheric stroke from February 2021 to January 2024. Demographic, clinical, and radiologic variables were collected from the hospital archives. All patients underwent head CT scan or MRI showing the involvement of the majority or complete middle cerebral artery distribution area. Hemicraniectomy with duraplasty was the main surgical procedure. The anteroposterior length of the craniectomy was more than 10 cm and the inferior part of the temporal bone to the floor of the middle cranial fossa was removed. Duraplasty was performed using epicrane or fascia lata aponeurosis. The mortality and the outcome using Modified Rankin Scale (mRS) were reported.

3. Results

A total of 9 patients with large hemispheric stroke who underwent DC were reviewed retrospectively. The mean age was 53 years with extremes of 39- and 67-year-old. There were 6 males and 3 females. The main risk factors of stroke were

hypertension and diabetes in 5 and 3 cases, respectively. Six of our patients were admitted with initial GCS at 15, whereas the preoperative GCS was less than 15 in all cases (Table 1). Diagnosis of stroke was made by head CT scan (Figure 1) in 7 patients and MRI (Figure 2) in 2 patients. Dominant hemisphere was involved in 3 cases. The mean time from stroke onset to craniotomy was 53 hours. The large craniectomy was made and the dura was opened in the stellate fashion. Duraplasty was performed using epicrane (Figure 2) in 7 patients and fascia lata aponeurosis in 2 patients. In the postoperative course, 4 (44%) patients died in 1 month, and the mortality rate was 66.6% in 6 months (Table 2).

Table 1. Demographic and clinical characteristics of 9 patients who underwent craniotomy for large hemispheric stroke.

Demographic and clinical characteristics	Patients								
	1	2	3	4	5	6	7	8	9
Age (years)	54	49	61	39	64	41	62	67	39
Gender	F	M	F	M	M	M	F	M	M
Risk factors	Hypertension diabetes	Hypertension	Hypertension		Hypertension diabetes	Smoker	-	-	Heart disease
Initial GCS	15	14	13	15	14	15	15	15	15
Preoperative GCS	10	10	9	13	11	9	8	11	12
Time from stroke onset to craniectomy (hours)	72	48	24	48	72	48	48	48	72

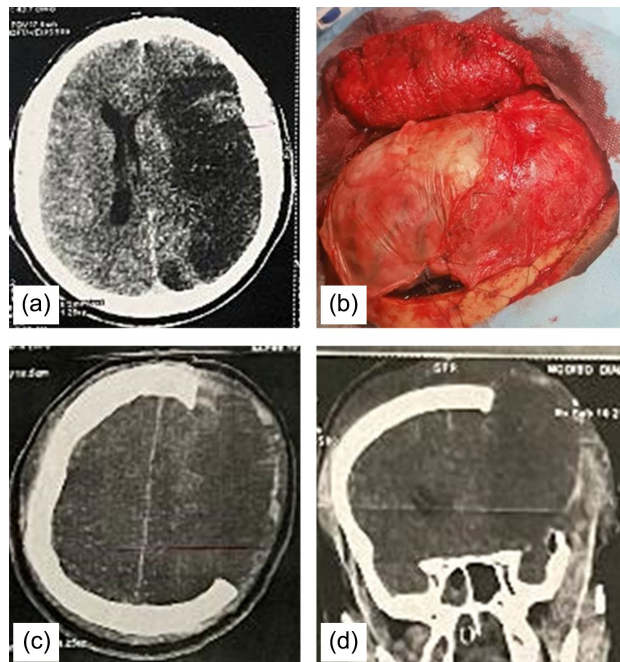


Figure 1. Preoperative CT scan 72 h after stroke onset (a) in patient 1 who underwent craniectomy with duraplasty (b). Postoperative CT scan in axial (c) and coronal (d) views.

Table 2. Mortality and functional outcome.

Mortality and functional outcome	Patients								
	1	2	3	4	5	6	7	8	9
1 month	mRS4	mRS4	Died	mRS1	Died	mRS4	Died	mRS4	Died
6 months	Died	mRS4	-	mRS1	-	mRS3	-	Died	-

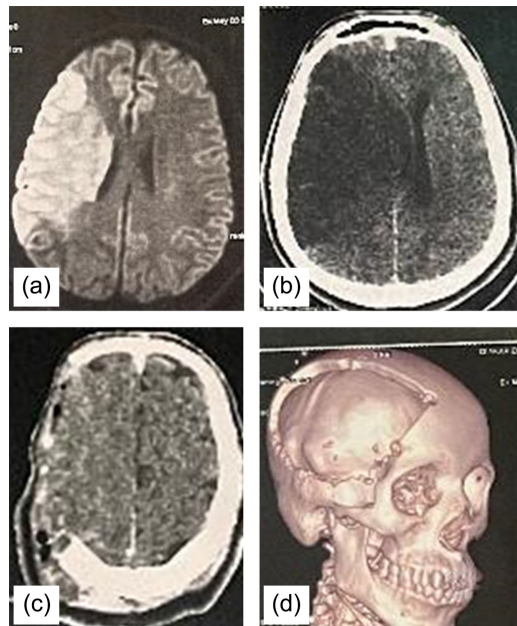


Figure 2. Early MRI (a) at stroke onset in patient 9 and preoperative CT scan 72 h later after worsening. Postoperative CT scan in axial (c) and 3D (d) views.

4. Discussion

Initially described by Kocher in 1901 for the treatment of posttraumatic brain edema [10], decompressive craniotomy has recently been applied to patients with massive hemispheric cerebral infarction [4]-[15]. Brain edema can develop after large ischemic stroke, leading to increased intracranial pressure and ensuing brain herniation. DC is a procedure whereby part of the skull is removed, and the underlying dura is opened, providing additional space for the swollen brain and mitigating the risk of ICP elevation and herniation.

Many studies in the literature [19]-[21] have proven the effectiveness of DC in terms of life-saving and quality of life. Decompressive craniotomy can reduce the mortality rate from 80% to 30%, and if the surgery is performed within 24 to 48 hours of stroke onset, the mortality rate can decrease to 10% [22]. In our study, the high mortality rate could be explained by many factors, such as patient selection criteria and timing of surgery.

The significant predictor factor of poor outcome and death after DC is elderly patients. In a systematic review, Gupta *et al.* [16] report a favorable outcome in patients less than 50 years old in whom DC was performed and mortality rate was 32%

in patients more than 50 years old compared to 14% in patients less than 50 years old. In our study, 5 of 9 patients were more than 50 years of age.

Another significant predictor factor of outcome is timing of surgery. Many studies suggest that DC must be done within the first 48 hours [23]. In a trial, in which patients were randomized up to 4 days after stroke, there was no benefit from DC when delayed from 48 to 96 hours after stroke onset [21]. In our study, the mean timing of DC was 53 hours after stroke onset and all of our patients experienced clinical worsening with GCS less than 15 before DC. This delay could be explained by the concern of patients and families about surgery.

Many other factors and comorbidities have been shown to be predictive of poor outcomes after DC, such as hypertension, coronary artery disease, cardiac arrhythmias, diabetes mellitus and arterial occlusive diseases [24].

5. Conclusion

Decompressive craniectomy is a life-saving procedure used to manage cerebral edema after stroke onset. In our study, the high mortality rate could be explained by many factors, such as patient selection criteria and timing of surgery. Early surgery within the first 48 hours in patients less than 60 years old with large hemispheric stroke is recommended.

Conflicts of Interest

The authors declare no conflicts of interest regarding the publication of this paper.

References

- [1] Rajsic, S., Gothe, H., Borba, H.H., Sroczyński, G., Vujicic, J., Toell, T., et al. (2018) Economic Burden of Stroke: A Systematic Review on Post-Stroke Care. *The European Journal of Health Economics*, **20**, 107-134. <https://doi.org/10.1007/s10198-018-0984-0>
- [2] Heinsius, T., Bogousslavsky, J. and Van Melle, G. (1998) Large Infarcts in the Middle Cerebral Artery Territory Etiology and Outcome Patterns. *Neurology*, **50**, 341-350. <https://doi.org/10.1212/wnl.50.2.341>
- [3] Hao, Z., Chang, X., Zhou, H., Lin, S. and Liu, M. (2015) A Cohort Study of Decompressive Craniectomy for Malignant Middle Cerebral Artery Infarction: A Real-World Experience in Clinical Practice. *Medicine*, **94**, e1039. <https://doi.org/10.1097/md.0000000000001039>
- [4] Hacke, W. (1996) 'Malignant' Middle Cerebral Artery Territory Infarction: Clinical Course and Prognostic Signs. *Archives of Neurology*, **53**, 309-315. <https://doi.org/10.1001/archneur.1996.00550040037012>
- [5] Ropper, A.H. (1984) Brain Edema After Stroke: Clinical Syndrome and Intracranial Pressure. *Archives of Neurology*, **41**, 26-29. <https://doi.org/10.1001/archneur.1984.04050130032017>
- [6] Wu, S., Yuan, R., Wang, Y., Wei, C., Zhang, S., Yang, X., et al. (2018) Early Prediction of Malignant Brain Edema after Ischemic Stroke: A Systemic Review and Meta-Analysis. *Stroke*, **49**, 2918-2927. <https://doi.org/10.1161/strokeaha.118.022001>
- [7] Hatashita, S. and Hoff, J.T. (1987) The Effect of Craniectomy on the Biomechanics of Normal Brain. *Journal of Neurosurgery*, **67**, 573-578.

- <https://doi.org/10.3171/jns.1987.67.4.0573>
- [8] Forsting, M., Reith, W., Schabitz, W., Heiland, S., von Kummer, R., Hacke, W., et al. (1995) Decompressive Craniectomy for Cerebral Infarction: An Experimental Study in Rats. *Stroke*, **26**, 259-264. <https://doi.org/10.1161/01.str.26.2.259>
- [9] Doerfler, A., Forsting, M., Reith, W., Staff, C., Heiland, S., Schabitz, W., et al. (1996) Decompressive Craniectomy in a Rat Model of "Malignant" Cerebral Hemispheric Stroke: Experimental Support for an Aggressive Therapeutic Approach. *Journal of Neurosurgery*, **85**, 853-859. <https://doi.org/10.3171/jns.1996.85.5.0853>
- [10] Kocher, T. (1901) Treatment of Intracranial Pressure. In: Hoelder, A., ED., *Concussions, Intracranial Pressure and Surgical Interventions for Brain Diseases*, Hoelder, 262-266.
- [11] Schwab, S., Steiner, T., Aschoff, A., Schwarz, S., Steiner, H.H., Jansen, O., et al. (1998) Early Hemicraniectomy in Patients with Complete Middle Cerebral Artery Infarction. *Stroke*, **29**, 1888-1893. <https://doi.org/10.1161/01.str.29.9.1888>
- [12] Rieke, K., Schwab, S., Krieger, D., von Kummer, R., Aschoff, A., Schuchardt, V., et al. (1995) Decompressive Surgery in Space-Occupying Hemispheric Infarction: Results of an Open, Prospective Trial. *Critical Care Medicine*, **23**, 1576-1587. <https://doi.org/10.1097/00003246-199509000-00019>
- [13] Delashaw, J.B., Broaddus, W.C., Kassell, N.F., Haley, E.C., Pendleton, G.A., Vollmer, D.G., et al. (1990) Treatment of Right Hemispheric Cerebral Infarction by Hemicraniectomy. *Stroke*, **21**, 874-881. <https://doi.org/10.1161/01.str.21.6.874>
- [14] Uhl, E., Kreth, F.W., Elias, B., et al. (2004) Outcome and Prognostic Factors of Hemicraniectomy for Space Occupying Cerebral Infarction. *Journal of Neurology, Neurosurgery and Psychiatry*, **75**, 270-274.
- [15] Wirtz, C.R., Steiner, T., Aschoff, A., Schwab, S., Schnippering, H., Steiner, H.H., et al. (1997) Hemicraniectomy with Dural Augmentation in Medically Uncontrollable Hemispheric Infarction. *Neurosurgical Focus*, **2**, E7. <https://doi.org/10.3171/foc.1997.2.5.7>
- [16] Gupta, R., Connolly, E.S., Mayer, S. and Elkind, M.S.V. (2004) Hemicraniectomy for Massive Middle Cerebral Artery Territory Infarction: A Systematic Review. *Stroke*, **35**, 539-543. <https://doi.org/10.1161/01.str.0000109772.64650.18>
- [17] Vahedi, K., Hofmeijer, J., Juettler, E., Vicaut, E., George, B., Algra, A., et al. (2007) Early Decompressive Surgery in Malignant Infarction of the Middle Cerebral Artery: A Pooled Analysis of Three Randomised Controlled Trials. *The Lancet Neurology*, **6**, 215-222. [https://doi.org/10.1016/s1474-4422\(07\)70036-4](https://doi.org/10.1016/s1474-4422(07)70036-4)
- [18] Cruz-Flores, S., Berge, E. and Whittle, I.R. (2012) Surgical Decompression for Cerebral Oedema in Acute Ischaemic Stroke. *Cochrane Database of Systematic Reviews*, No. 1, Article ID: CD003435. <https://doi.org/10.1002/14651858.cd003435.pub2>
- [19] Juettler, E., Schwab, S., Schmiedek, P., Unterberg, A., Hennerici, M., Woitzik, J., et al. (2007) Decompressive Surgery for the Treatment of Malignant Infarction of the Middle Cerebral Artery (Destiny): A Randomized Controlled Trial. *Stroke*, **38**, 2518-2525. <https://doi.org/10.1161/strokeaha.107.485649>
- [20] Vahedi, K., Vicaut, E., Mateo, J., Kurtz, A., Orabi, M., Guichard, J., et al. (2007) Sequential-Design, Multicenter, Randomized, Controlled Trial of Early Decompressive Craniectomy in Malignant Middle Cerebral Artery Infarction (DECIMAL Trial). *Stroke*, **38**, 2506-2517. <https://doi.org/10.1161/strokeaha.107.485235>
- [21] Hofmeijer, J., Kappelle, L.J., Algra, A., Amelink, G.J., van Gijn, J. and van der Worp, H.B. (2009) Surgical Decompression for Space-Occupying Cerebral Infarction (the Hemicraniectomy after Middle Cerebral Artery Infarction with Life-Threatening Edema Trial [HAMLET]): A Multicentre, Open, Randomised Trial. *The Lancet Neurology*, **8**,

326-333. [https://doi.org/10.1016/s1474-4422\(09\)70047-x](https://doi.org/10.1016/s1474-4422(09)70047-x)

- [22] Walz, B., Zimmermann, C., Böttger, S. and Haberl, R.L. (2002) Prognosis of Patients after Hemicraniectomy in Malignant Middle Cerebral Artery Infarction. *Journal of Neurology*, **249**, 1183-1190. <https://doi.org/10.1007/s00415-002-0798-x>
- [23] Powers, W.J., Rabinstein, A.A., Ackerson, T., Adeoye, O.M., Bambakidis, N.C., Becker, K., et al. (2019) Guidelines for the Early Management of Patients with Acute Ischemic Stroke: 2019 Update to the 2018 Guidelines for the Early Management of Acute Ischemic Stroke: A Guideline for Healthcare Professionals from the American Heart Association/American Stroke Association. *Stroke*, **50**, e344-e418. <https://doi.org/10.1161/str.0000000000000211>
- [24] Harscher, S., Reichart, R., Terborg, C., Hagemann, G., Kalff, R. and Witte, O.W. (2005) Outcome after Decompressive Craniectomy in Patients with Severe Ischemic Stroke. *Acta Neurochirurgica*, **148**, 31-37. <https://doi.org/10.1007/s00701-005-0617-0>