

Off-Pump CABG Using Bilateral *in Situ* Internal Mammary Arteries in a Dextrocardiac Patient: A Case Report

Jahangir Kabir¹, Md. Shadequl Islam¹, Sayedur Rahman Khan¹, Abu Hanif Samrat¹, Arif Ahmed Mohiuddin¹, Rafiur Rahman¹, Md. Arman Hossain¹, Md. Abir Tazim Chowdhury^{2*} 

¹Department of Cardiac Surgery, United Hospital Ltd, Dhaka, Bangladesh

²Department of Cardiothoracic and Vascular Surgery, Evercare Hospital Dhaka, Dhaka, Bangladesh

Email: *chowdhuryabir0@gmail.com

How to cite this paper: Kabir, J., Islam, Md.S., Khan, S.R., Samrat, A.H., Mohiuddin, A.A., Rahman, R., Hossain, Md.A. and Chowdhury, Md.A.T. (2025) Off-Pump CABG Using Bilateral *in Situ* Internal Mammary Arteries in a Dextrocardiac Patient: A Case Report. *World Journal of Cardiovascular Surgery*, 15, 91-97.

<https://doi.org/10.4236/wjcs.2025.154008>

Received: March 5, 2025

Accepted: April 5, 2025

Published: April 8, 2025

Copyright © 2025 by author(s) and Scientific Research Publishing Inc.

This work is licensed under the Creative Commons Attribution International License (CC BY 4.0).

<http://creativecommons.org/licenses/by/4.0/>



Open Access

Abstract

Background: Dextrocardia with situs inversus is a rare congenital anomaly where the heart and abdominal organs are mirrored. Coronary artery disease (CAD) in these patients occurs at a similar rate as in the general population, but surgical management requires modifications due to anatomical differences. **Aim:** To discuss the technical considerations and execution of off-pump coronary artery bypass grafting (OPCABG) using bilateral internal mammary arteries (BIMA) in a dextrocardia patient. **Case Presentation:** A 48-year-old male with chest pain for one week was diagnosed with dextrocardia and CAD. ECG showed ischemic changes, and echocardiography revealed mid-basal inferior and inferolateral wall hypokinesia. Coronary angiography demonstrated total LAD occlusion with retrograde RCA filling and significant RCA stenosis. OPCAB was performed via median sternotomy, using BIMA for total arterial revascularization. RIMA was grafted to the LAD, and LIMA to the RCA, ensuring optimal exposure and graft positioning. **Conclusion:** Surgical intervention in dextrocardia requires tailored techniques. The left-sided operating position enhances exposure, and BIMA use improves long-term outcomes. Meticulous preoperative planning and intraoperative modifications can lead to successful CABG in these complex cases.

Keywords

Dextrocardia, Situs Inversus, Off-Pump Coronary Artery Bypass Grafting (OPCABG), Bilateral Internal Mammary Artery (BIMA), Total Arterial Revascularization, LIMA-RIMA *in Situ*

1. Introduction

Dextrocardia with situs inversus is an uncommon congenital condition, occurring at an estimated incidence of 1 in 100,000 individuals [1]. Despite this anomaly, the prevalence of CAD remains similar to that in individuals with normal cardiac orientation [2]. The anatomical reversal in dextrocardia necessitates surgical adjustments, particularly in positioning and operative techniques. Traditionally, most surgeons prefer to operate from the left side of the patient. However, conventional positioning is also feasible with the right modifications [3]. In general, on-pump and off-pump coronary artery bypass grafting (OPCAB) procedures have similar outcomes in terms of survival rates, stroke risk, and the likelihood of myocardial infarction. As a result, the choice of technique often comes down to the surgeon's preference [4]. However, for patients with dextrocardia and abnormal cardiac anatomy, surgeons must carefully consider which approach to use in order to achieve the highest level of precision. Since only a small number of dextrocardia patients live long enough to develop coronary artery disease (CAD) and require surgery, there is limited data comparing the outcomes of conventional on-pump CABG versus OPCAB in this specific group of patients [5].

This case report details the technical considerations and successful execution of OPCAB using bilateral internal mammary arteries (BIMA) *in situ* in a patient with dextrocardia.

2. Case Summary

A 48-year-old male presented with a one-week history of chest pain. He had no prior medical or surgical history, nor had he undergone any interventions, except for a diagnosis of systemic hypertension. His electrocardiogram (ECG) showed ischemic changes. The patient's initial diagnosis of dextrocardia was incidental, first detected on a chest radiograph. The presence of a right-sided gastric fundus shadow further confirmed situs inversus (Figure 1). A detailed transthoracic echocardiogram (TTE) was performed, confirming the atrial situs and the alignment of atrioventricular (AV) and ventriculoarterial (VA) connections. Systemic and pulmonary venous drainage were found to be normal, with no intracardiac shunts or coronary artery anomalies detected. However, while overall biventricular function appeared normal, the echocardiogram revealed hypokinesia in the mid-basal segment of the inferior and inferolateral walls. Cardiac biomarkers were positive, guiding further evaluation through coronary angiography. Coronary angiography identified severe coronary artery disease, including total occlusion of the left anterior descending artery (LAD) with retrograde filling from the right coronary artery (RCA) and left circumflex artery (LCX) (Figure 1). Additionally, there was a 95% stenosis in the proximal RCA and 30% stenosis in the LCX. Apart from situs inversus totalis, the patient exhibited no other apparent cardiac or extracardiac anomalies.

Given the extent of the disease, the patient underwent off-pump coronary ar-

tery bypass grafting (OPCABG) via median sternotomy. The surgical team carefully assessed the coronary targets for revascularization using the left internal mammary artery (LIMA) and right internal mammary artery (RIMA). The LAD was found to be completely occluded, allowing a probe to pass easily beyond the arteriotomy site. Both LIMA and RIMA were skeletonized and harvested to optimize conduit length and mobility.

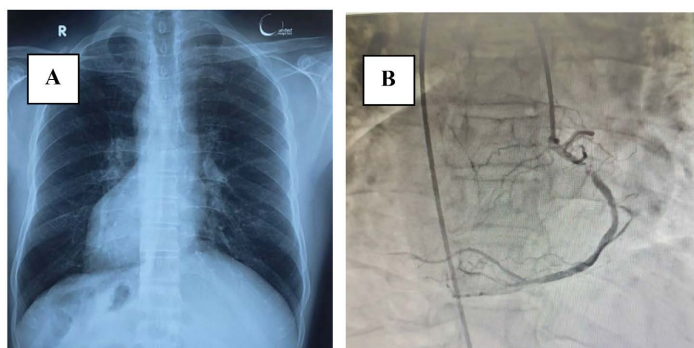


Figure 1. Preoperative imaging: (A) Chest X-ray (PA view) showing dextrocardia with situs inversus; (B) Coronary angiogram revealing 95% occluded RCA with retrograde filling of a totally occluded LAD.

The right internal mammary artery (RIMA) was grafted to the proximal left anterior descending (LAD) artery, requiring technical adjustments due to the patient's reversed anatomy. The surgeon, accustomed to grafting the left internal mammary artery (LIMA) to the LAD from the right side with clockwise anastomotic bites, had to adapt when operating from the left side in this case. This required reversing the usual technique by taking anastomotic bites in an anticlockwise direction (**Figure 2**).

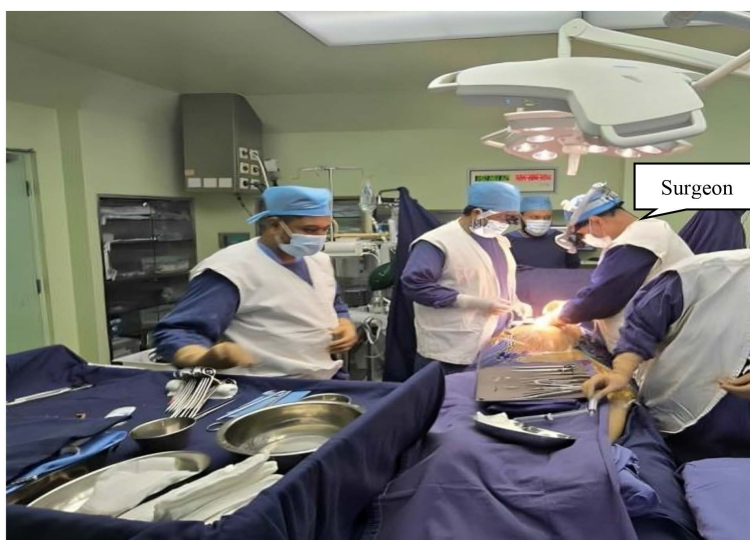


Figure 2. Showing the surgeon's position on the patient's left side during surgery, adapting to the mirror-image anatomy of dextrocardia.

The technical challenge was even greater when grafting the LIMA to the right coronary artery (RCA). To address this, the surgeon switched the approach to the right side. The LIMA was then grafted to the RCA *in situ*, effectively replicating the standard LIMA-to-LAD configuration seen in patients with normal anatomy.

In **Figure 3**, the right internal mammary artery (RIMA) is shown being grafted to the left anterior descending (LAD) artery *in situ*. Image (A) captures the grafting process, while image (B) depicts the completed anastomosis, ensuring optimal blood flow to the LAD.

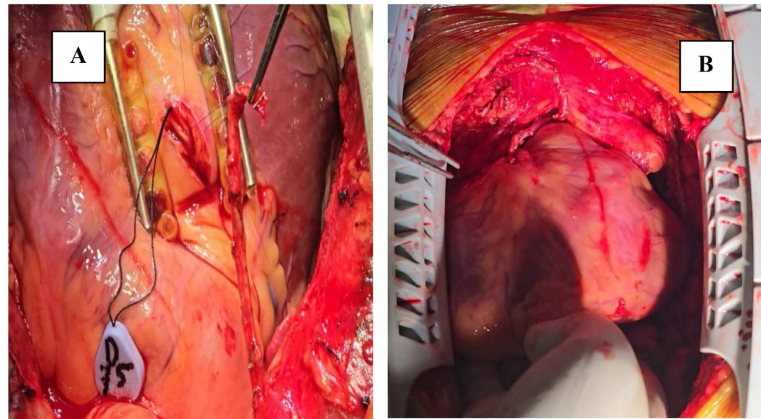


Figure 3. RIMA to LAD *in situ* grafting: (A) During grafting; (B) Upon completion of grafting.

After completing the distal anastomoses, careful assessment ensured optimal graft positioning and length. Following meticulous hemostasis, the chest was closed in layers, completing a technically challenging but successful procedure in this rare anatomical variant.

In **Figure 4**, the left internal mammary artery (LIMA) is grafted to the distal right coronary artery (RCA) *in situ*. Image (A) illustrates the graft placement during the procedure, and image (B) presents the final result post-anastomosis, confirming successful revascularization.

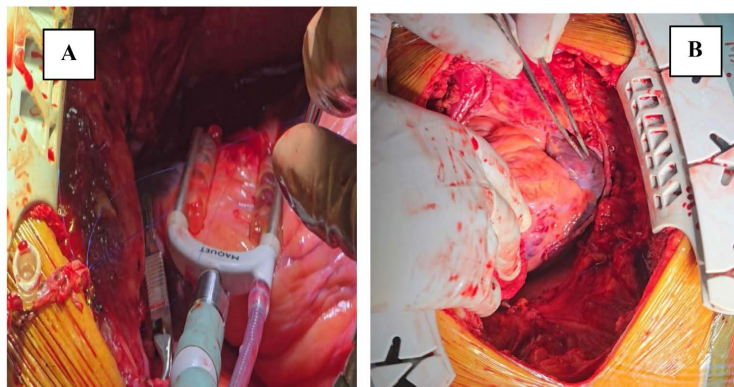


Figure 4. LIMA to distal RCA *in situ* grafting: (A) During grafting; (B) After completion.

The patient's postoperative recovery was smooth, with no complications. He was discharged home on the seventh postoperative day. At his six-week follow-up, he showed significant clinical improvement.

3. Discussion

Dextrocardia was first described by Hieronymus Fabricius in 1606, while situs inversus was later detailed by Marco Aurelio Severinus in 1643 [6]. In adults, dextrocardia is often associated with situs inversus totalis, where mirror-image symmetry involves not only the heart but also the bronchial branching pattern and abdominal viscera. This anatomical variation poses distinct challenges for coronary artery bypass surgery [7].

Preoperative evaluations in dextrocardia patients include clinical examination, ECG, echocardiography, and coronary angiography. ECG findings typically show inverted P waves in lead I with mirror-image dextrocardia, while echocardiography confirms atrial situs and cardiac function. Coronary angiography, with minor modifications, helps delineate coronary artery anatomy [3].

The choice of surgical position is a crucial factor in these cases. In most instances, including our presented case where the right internal mammary artery (RIMA) was grafted to the right coronary artery (RCA), surgeons prefer operating from the left side. This position offers better exposure to the coronary targets and allows for easier graft placement. This positioning is particularly advantageous for accessing the left-sided vessels such as the LAD and LCX. However, in some cases, right-side positioning may be required for specific anastomoses, necessitating additional technical adjustments [3] [8]. In the present case, after completing the LAD graft, the surgeon switched to the right side, where the left internal mammary artery (LIMA) was grafted to the right coronary artery (RCA) in situ. This approach effectively mirrored the standard LIMA-to-LAD configuration typically seen in patients with normal anatomy.

The use of BIMA provides significant long-term benefits in CABG patients [9]. The RIMA was selected for the LAD in our case due to its proximity and favorable anatomical orientation, while the LIMA was used for the RCA. Full skeletonization of the LIMA was necessary to achieve adequate length, a technique that is particularly beneficial in dextrocardia cases [3] [10].

Kanoksin S and colleagues reviewed 35 studies, identifying 41 dextrocardia patients who underwent CABG between 1981 and 2022. Most surgeons operated from the left side (19 cases), while fewer used the right (8 cases) or both (3 cases). Saphenous vein grafts were the most frequently used (33 cases), followed by RIMA (30 cases), LIMA (10 cases), radial artery (4 cases), and a single use of the gastroepiploic artery. Notably, only six cases reported the use of bilateral internal mammary artery (BIMA) grafts, highlighting its rarity in dextrocardia patients. Procedures ranged from single to five grafts, utilizing both on-pump and off-pump techniques. These findings emphasize the adaptability of CABG in managing the unique anatomical challenges of situs inversus [5].

In the present case, we utilized BIMA as *in situ* grafts, performed the procedure using the OPCAB technique, and adapted to the patient's unique anatomy by operating from both sides.

4. Recommendations

- **Preoperative Planning:** Detailed imaging, including echocardiography and coronary angiography, should be conducted to evaluate anatomical variations and guide surgical planning.
- **Surgeon's Position:** The left-side operating position is generally preferred for better visualization and easier access to coronary targets; however, adaptability is crucial, as certain anastomoses may require switching to the right side.
- **Conduit Selection:** Use of bilateral internal mammary arteries (BIMA) should be prioritized for superior long-term outcomes.
- **Graft Configuration:** Full skeletonization of the internal mammary arteries can provide additional length, aiding in the revascularization of distal coronary targets.
- **Postoperative Monitoring:** Careful hemodynamic monitoring and echocardiographic evaluation are essential to detect any graft-related complications early.

5. Conclusion

Dextrocardia is an exceedingly rare condition that necessitates specialized surgical adaptations. Total arterial revascularization using BIMA presents an additional challenge due to the altered anatomy. However, with careful planning and minor intraoperative modifications, excellent surgical outcomes can be achieved. This case demonstrates the feasibility and success of CABG using BIMA *in situ* in a patient with dextrocardia, highlighting the importance of tailored surgical strategies in complex congenital anomalies.

Ethics Statement

Written informed consent was obtained from the patient's parents for the publication of any images or data that could potentially reveal the patient's identity in this article.

Acknowledgements

The authors would like to express their sincere gratitude to the surgical and anesthetic teams at United Hospital Ltd, Gulshan 2, Dhaka, Bangladesh, for their invaluable support and expertise in managing this complex case. We also extend our appreciation to the nursing staff and technical personnel for their dedication and contributions to ensuring optimal patient care. Finally, we acknowledge the patient and their family for their trust and cooperation throughout the treatment process.

Conflicts of Interest

The authors declare no conflicts of interest regarding the publication of this paper.

References

- [1] Rosenberg, H.N. and Rosenberg, I.N. (1949) Simultaneous Association of Situs Inversus, Coronary Heart Disease and Hiatus Hernia: Report of a Case and Review of Literature. *Annals of Internal Medicine*, **30**, 851-859. <https://doi.org/10.7326/0003-4819-30-4-851>
- [2] Subash, S., Simha, P. and Manjunatha, N. (2017) Off-Pump Coronary Artery Bypass Surgery in a Patient with Dextrocardia and Situs Inversus: Anesthetic, Surgical Consideration and Role of Transesophageal Echocardiography. *Heart Views*, **18**, 100-103. https://doi.org/10.4103/heartviews.heartviews_5_17
- [3] Murtuza, B., Gupta, P., Goli, G. and Lall, K.S. (2010) Coronary Revascularization in Adults with Dextrocardia: Surgical Implications of the Anatomic Variants. *Texas Heart Institute Journal*, **37**, 633-640.
- [4] Chikwe, J., Lee, T., Itagaki, S., Adams, D.H. and Egorova, N.N. (2018) Long-term Outcomes after Off-Pump versus On-Pump Coronary Artery Bypass Grafting by Experienced Surgeons. *Journal of the American College of Cardiology*, **72**, 1478-1486. <https://doi.org/10.1016/j.jacc.2018.07.029>
- [5] Kanoksin, S., Napa-umporn, W. and Phanchaipetch, T. (2024) Two Case Reports of Coronary Artery Bypass Grafting in Adults with Dextrocardia with Situs Inversus. *The Journal of Chulabhorn Royal Academy*, **6**, 46-53.
- [6] Cleveland, M. (1926) Situs Inversus Viscerum: An Anatomic Study. *Archives of Surgery*, **13**, 343-368. <https://doi.org/10.1001/archsurg.1926.01130090042003>
- [7] Wilcox, B.R., Cook, A.C. and Anderson, R.H. (2005) *Surgical Anatomy of the Heart*. Cambridge University Press.
- [8] Yamashiro, S., Iha, K., Akasaki, M., Uezu, T., Ikemura, R. and Nishijima, I. (2009) Emergency Off-Pump Complete Arterial Revascularization in a Patient with Dextrocardia. *General Thoracic and Cardiovascular Surgery*, **57**, 625-628. <https://doi.org/10.1007/s11748-009-0446-9>
- [9] Urso, S., Sadaba, R., González Martín, J.M., Nogales, E., Tena, M.Á. and Portela, F. (2024) Bilateral Internal Thoracic Artery versus Single Internal Thoracic Artery plus Radial Artery: A Double Meta-Analytic Approach. *The Journal of Thoracic and Cardiovascular Surgery*, **167**, 183-195.E3. <https://doi.org/10.1016/j.jtcvs.2022.03.010>
- [10] Poncelet, A.J., Dion, R., Lengele, B. and Noirhomme, P. (2006) Complete Arterial Revascularization in Coronary Artery Bypass Grafting in a Patient with Solitus Inversus Totalis. *Journal of Cardiovascular Surgery*, **47**, 477-479.