

Is the Laparoscope Only Meant for the Abdomen?

—A Case Report Utilizing Laparoscopy to Evaluate a Thigh Abscess Cavity

Emily R. Kindall¹, Wade M. Wright², Peter P. Zajac³, Courtney M. Janowski⁴, David L. Young⁵, Luis G. Fernandez^{5,6,7,8,9,10,11}, Marc R. Matthews^{12*}

¹Department of Surgery, Doctors Hospital at Renaissance, Edinburg, TX, USA

²Department of Surgery, Abrazo Health Network General Surgery Residency, Glendale, AZ, USA

³Department of Surgery, Mountain Vista Medical Center, Mesa, AZ, USA

⁴Penn State Health Milton S. Hershey Medical Center, Hershey, PA, USA

⁵Department of Surgery, Division of Trauma Surgery/Surgical Critical Care, The University of Texas Health Science Center, Tyler, TX, USA

⁶School of Medicine, University of Texas at Tyler, Tyler, TX, USA

⁷Trauma Wound Care, UT Health East, Tyler, TX, USA

⁸Department of Surgery, University of Texas Medical Branch, Galveston, TX, USA

⁹Adjunct Clinical Professor of Medicine and Nursing, University of Texas, Arlington, TX, USA

¹⁰TXSG Medical Brigade, Austin, TX, USA

¹¹Assistant Clinical Professor of Surgery, University of Texas, Tyler, TX, USA

¹²Department of Surgery, Banner-University of Arizona/University Medical Center, Tucson, AZ, UAS

Email: *mrmathews1@arizona.edu

How to cite this paper: Kindall, E.R., Wright, W.M., Zajac, P.P., Janowski, C.M., Young, D.L., Fernandez, L.G. and Matthews, M.R. (2025) Is the Laparoscope Only Meant for the Abdomen? *Surgical Science*, **16**, 281-290. <https://doi.org/10.4236/ss.2025.165029>

Received: April 14, 2025

Accepted: May 25, 2025

Published: May 28, 2025

Copyright © 2025 by author(s) and Scientific Research Publishing Inc. This work is licensed under the Creative Commons Attribution International License (CC BY 4.0).

<http://creativecommons.org/licenses/by/4.0/>



Open Access

Abstract

Minimally invasive surgery and the use of endoscopy have been evolving for over 225 years. Traditionally used for general surgery procedures in the abdomen, the role of the laparoscope is now commonly used in not only the abdomen but also the retroperitoneum, chest, urinary tract, joints, pelvis, and even in the gravid uterus. It is the predominant route for surgical exploration and intervention, whether for malignant or benign diseases. As minimally invasive surgery continues to expand, novel uses of the laparoscope are devised, demonstrating that the laparoscope can be used anywhere in the body. Presented is a 42-year-old female with a large, soft-tissue thigh abscess, which, once drained, required the placement of a trocar and laparoscope to evaluate the remaining large cavity for possible retained necrosis or purulence. Simple visual inspection with retraction did not provide adequate visualization without requiring a large counter incision in a metabolically challenged patient. This case presen-

tation highlights the versatility of endoscopy and the laparoscope instrument.

Keywords

Laparoscope, Laparoscopy, Thigh, Abscess, Abscess Cavity, Negative Wound Therapy, Instillation Therapy, Hypochlorous Acid

1. Introduction

Minimally invasive surgery and the use of endoscopy were first developed with the cystoscope, allowing for the treatment of lower urinary tract pathology in 1803. [1] This then progressed to thoracoscopy and eventually laparoscopy in the late 1800s. [1] However, these 19th-century renditions of minimally invasive surgery were rudimentary and cumbersome to the patient as well as the examiner as they were performed under direct visualization with the use of candlelight. It was not until the 1980s that modern laparoscopic surgery, using a camera and an electric light source, was born. [2] Since this time, the landscape of minimally invasive surgery has only continued to evolve.

Traditionally used for general surgery procedures in the abdomen, the role of the laparoscope has expanded to become a cornerstone practice in several surgical subspecialties, including general surgery, colorectal surgery, thoracic surgery, orthopedic surgery, urology, and gynecology. [3] The laparoscope is now commonly used in not only the abdomen but also the retroperitoneum, the chest, the urinary tract, joints, and even the gravid uterus. It is the predominant route for surgical exploration and intervention, whether in malignant or benign cases. [2] The list of laparoscopic surgical procedures is endless (**Tables 1-3**). As minimally invasive surgery continues to expand, novel uses of the laparoscope are presented, demonstrating that the laparoscope can be used just about anywhere in the body.

Table 1. List of frequently performed abdominal/pelvic laparoscopic procedures.

Laparoscopic exploration/washout
Laparoscopic adhesiolysis
Laparoscopic drain placement
Laparoscopic appendectomy
Laparoscopic cholecystectomy with/without common bile duct exploration
Laparoscopic splenectomy
Laparoscopic trauma evaluation for penetrating injury into the peritoneum and running the bowel
Laparoscopic hernia repair with mesh or implant
Laparoscopic anterior wall reconstruction with mesh or implant
Laparoscopic liver resection
Laparoscopic small and large bowel resection (partial bowel or total colectomy)
Laparoscopic enterostomy/colostomy placement

Continued

Laparoscopic nephrectomy for removal or transplant
Laparoscopic diaphragmatic hernia/laceration repair with mesh or implant
Laparoscopic bypass surgery/sleeve resection (bariatric surgery)
Laparoscopic adrenalectomy
Laparoscopic pancreaticoduodenectomy with reconstruction
Laparoscopic retroperitoneal mass excision
Laparoscopic abscess debridement/removal
Laparoscopic diverticulitis washout
Laparoscopic neobladder creation
Laparoscopic bladder resection
Laparoscopic prostatectomy and pelvic node dissection
Laparoscopic fetal intervention in the gravid uterus
Laparoscopic hysterectomy with or without node dissection/oophorectomy/adeneotomy/ myomectomy/tubal ligation/ovarian cyst aspiration/ovarian resections
Laparoscopic transvaginal (culdoscopy)/transrectal/transgastric approaches
Natural Orifice Transluminal Endoscopic Surgery (NOTES)
Laparoscopic Shunt Revision

Table 2. List of frequently performed thoracoscopic procedures.

Video-assisted thoracoscopic surgery
Thoracoscopic lobectomy/wedge resection
Thoracoscopic spontaneous pneumothorax therapy

Table 3. List of prior vascular laparoscopic endeavors.

Laparoscopic Aortic Aneurysm Repair (historic and prior to endovascular surgery development)
Angioscopy
Subfascial endoscopic perforator vein ligation

2. Aim

In this case report, we describe the use of the laparoscope within a soft tissue cavity, further highlighting the breadth of endoscopy and the laparoscope instrument.

3. Case Report

A 42-year-old female with a past medical history of severe diabetes requiring insulin, lipomyelomeningocele resulting in bilateral lower extremity paralysis from infancy, peripheral artery disease resulting in a right below knee amputation (BKA), right femoral head resection due to osteonecrosis as well as a left hip disarticulation, bipolar and substance abuse disorders, end colostomy placement, and bilateral nephrostomy tubes secondary to recurrent and problematic drainage from

her suprapubic catheter, presented with a large right thigh abscess. Initial radiographic images revealed a previously resected right femoral head (**Figure 1**). Her initial basal metabolic rate was 36 (minus her two lower extremities and her HgbA1C was 11.5% (mmol/mol). A computerized axial tomography (CAT) scan revealed a large right thigh abscess surrounding the remaining right femur (**Figure 2, Figure 3**). The patient underwent initial drainage from a lateral incision (**Figure 4, Figure 5**) and wound packing hypochlorous acid solution-soaked gauze (Vashe Wound Solution, Urgo Medical North America, Ft. Worth, TX); however, subsequent inspection to assess whether the entire abscess cavity had been drained or if there was any remaining necrotic tissue to debride, proved difficult. The cavity was exceptionally large, approximately 20 × 10 cm (as measured by CAT scan), with the femur bone running through the center. Options to improve visualization, such as extending the lateral incision or creating a separate medial counter-incision, were discussed but were not favorable in this patient with multiple comorbidities and a proven predilection for infectious complications.

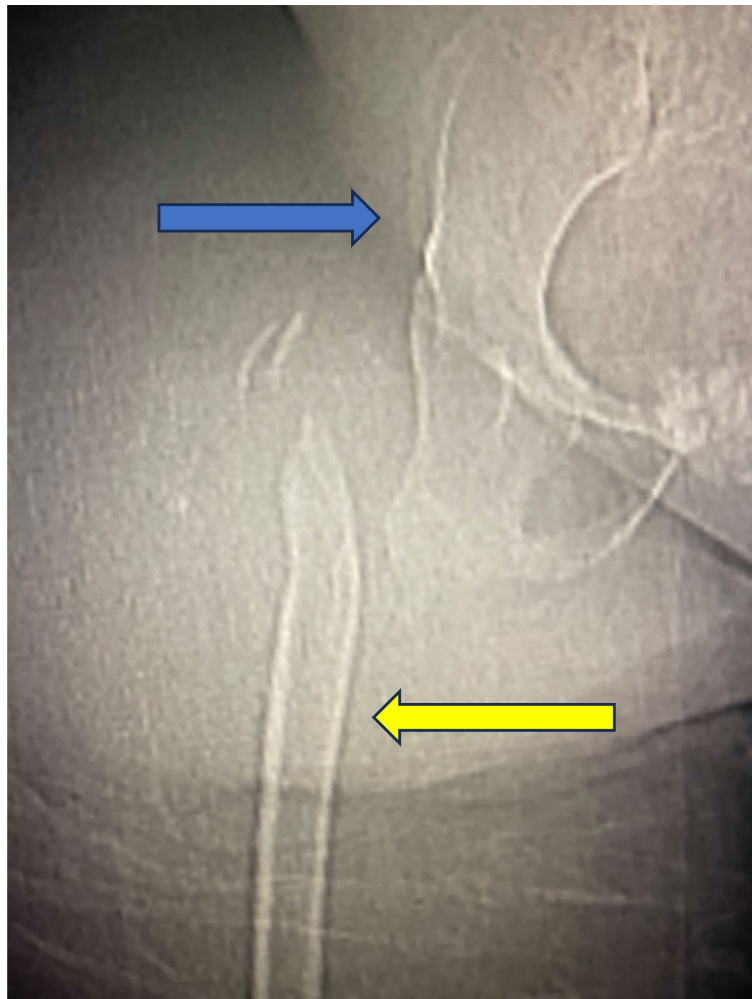


Figure 1. Radiograph of right hip joint including right pelvis (blue arrow) and femur (yellow arrow) revealing a previously resected right femoral head.

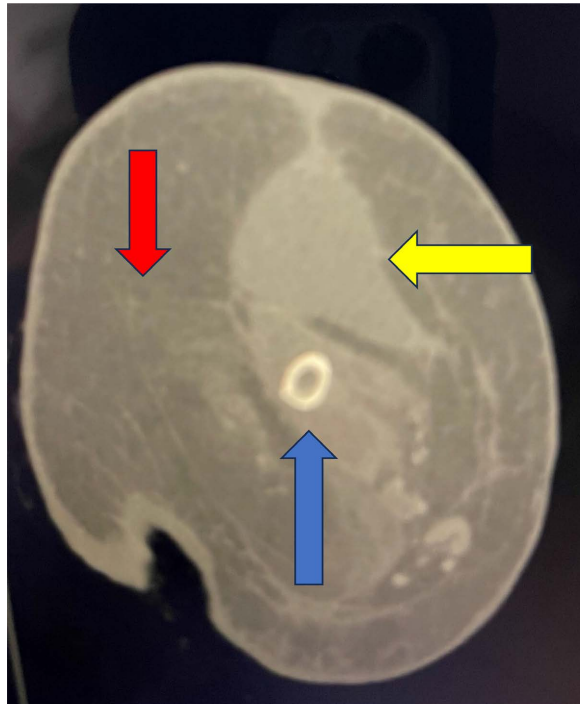


Figure 2. Computed tomography scan (axial view) of right thigh with femoral bone (blue arrow), large abscess (yellow arrow) surrounding the femoral bone, and muscle mass (red arrow).

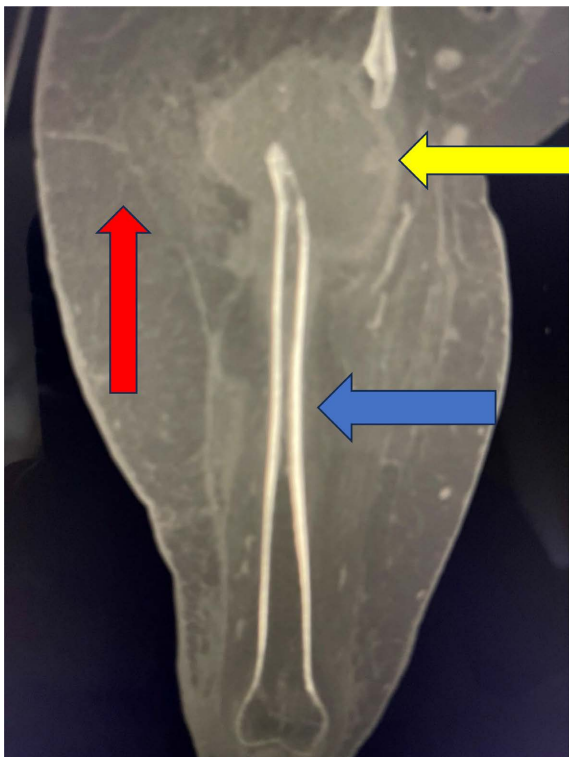


Figure 3. Computed tomography scan (coronal view) of the right thigh with femoral bone (blue arrow), large abscess (yellow arrow) surrounding the femoral bone, and muscle mass (red arrow).

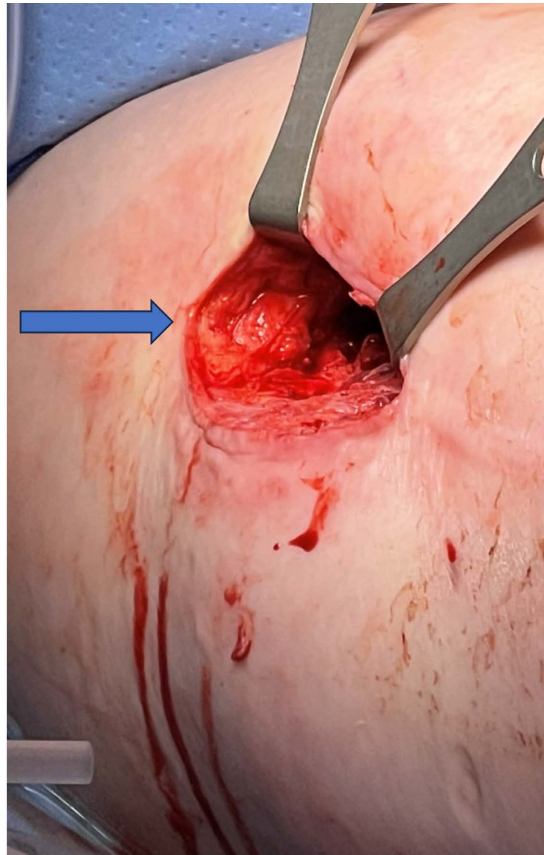


Figure 4. Photograph of the right lateral thigh lateral incision for abscess drainage. The blue arrow denotes where the No. 11-sized trocar and 30-degree laparoscope were inserted to inspect the large right thigh abscess cavity.

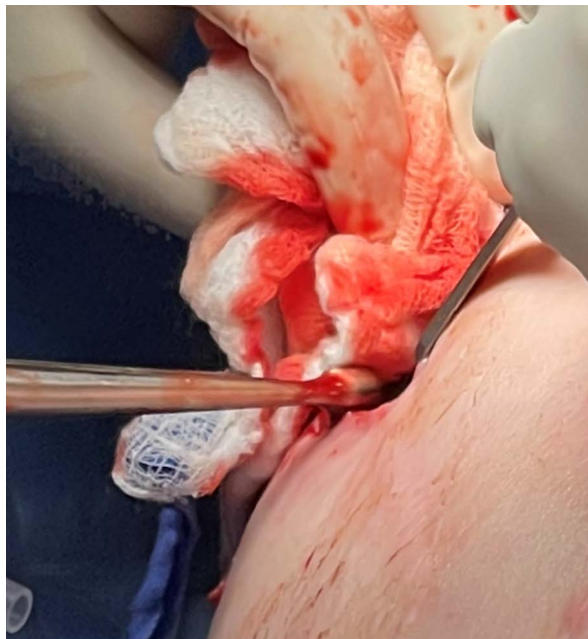

Figure 5. Photograph of currettes being inserted into a right thigh wound to debride the distended right thigh abscess cavity after inspection by the laparoscope.

Because the femur was visually obstructing the opposite side view of the wound, and despite maximal retraction, the proximal, medial, and superior aspects of the abscess cavity could not be inspected by direct visualization. The decision was then made to insert a #11 disposable trocar (Ethicon, Raritan, NJ) through the previously made drainage incision, and a #10 laparoscope (Karl Storz Endoskope, Tuttlingen, Germany) was then advanced to assess the large, evacuated abscess cavity. The 30-degree laparoscope was able to be manipulated past the femur, rotated circumferentially, and allowed for clear visualization/inspection of the entire internal thigh cavity. No remaining necrosis or purulence were appreciated, so the cavity was irrigated with one liter of hypochlorous solution through the laparoscope. Postoperatively, the blood sugars were kept between 140 and 200 mg/dL, and a nutrition consult was obtained to assist with a protein-sparing diet to further wound healing.

The patient then underwent negative pressure wound therapy with a spirally cut cover layer of the CLEANSE CHOICE™ foam (Solventum, San Antonio, TX) (Figures 6-8) with instillation of hypochlorous acid solution for cyclical washings, and no further surgical intervention was required. After several weeks of intravenous antibiotics, including piperacillin/tazobactam (Pfizer, New York City, NY) and tobramycin (Pfizer, New York City, NY), as well as negative pressure wound therapy and improved blood sugar control, the right thigh abscess cavity was obliterated, and the skin was closed by delayed primary closure after 10 days. The patient was discharged on hospital day 17 to a skilled nursing facility, and despite a clinic visit scheduled within one week of discharge, she was lost to follow-up.

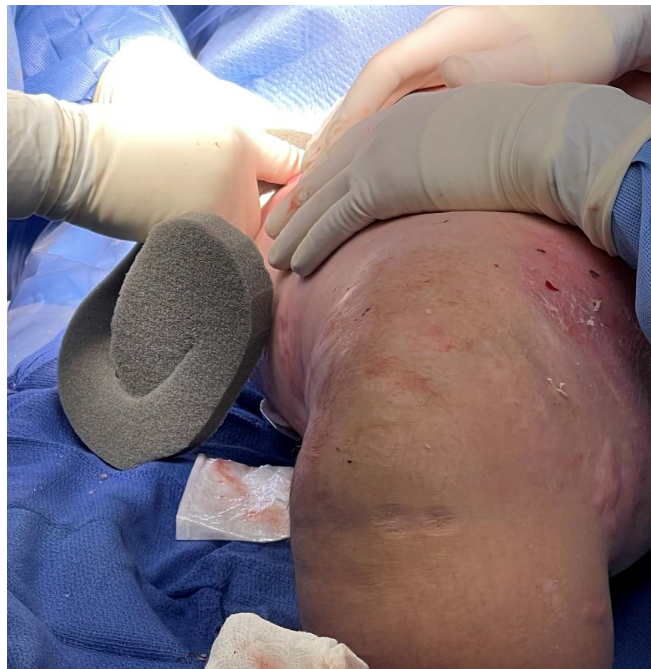

Figure 6. Packing right thigh cavity through lateral wound with spirally cut CLEANSE CHOICE™ foam.

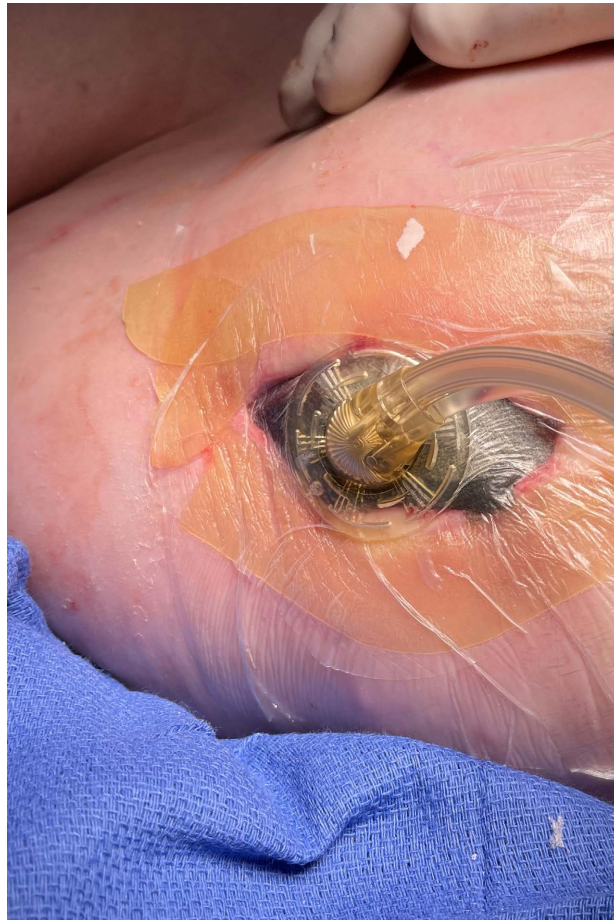

Figure 7. Packed right thigh cavity through lateral wound with spiral cut CLEANSE CHOICE™ foam with acrylic drape covering.



Figure 8. Freshly removed and spirally cut CLEANSE CHOICE™ foam to help remove inflammatory mediators and collapse the distended thigh cavity.

4. Discussion

This innovative use of the laparoscope demonstrates that the bounds of minimally invasive surgery have still not been reached to view all inner spaces of the human body [4].

It was Swedish surgeon Hans Christian Jacobaeus, who was initially credited with coining the term “laparoscopy” (“laparothorakoskopie”) [5], who reported about his clinical experience using the laparoscope with pneumoperitoneum in 17 subjects and two thorascopies [6]. Novel techniques continue to be presented annually in this field. One such example is the use of minimally invasive surgery in a patient to laparoscopically evacuate a tubercular abscess located in a presacral region to decrease the morbidity acquired by the patient [7]. Another case report described the extraperitoneal evacuation of a tubercular iliopsoas abscess with the use of a laparoscope. However, the authors recognized the lack of high-level research within the literature concerning the management and treatment options of such an abscess [8]. Nonetheless, not all laparoscope endeavors into human soft tissue cavities or tissue planes have been successful or may have been sidelined secondary to other technological advancements in surgery (Table 3).

In our case report, using a laparoscope through a trocar advanced into the thigh cavity allowed for clear visualization that no necrotic tissue, multiloculated abscess, or purulence remained, and thus, the diabetic patient with multiple comorbidities was able to avoid an extended incision or an additional counter-incision on the medial aspect of the abscess cavity. As with all minimally invasive surgical techniques, the use of the laparoscope in large soft tissue cavities may afford patients less pain, lower risk of infection, faster recovery, potentially shorter hospital stays, decreased wound burden, and overall reduced morbidity.

5. Limitations

This case report suffers from limitations, including the fact that it represents one single patient and may lack generalizable knowledge of other surgical patients. However, there are most likely other medical centers that have had similar issues with accessing patients’ difficult anatomy or other problems requiring the innovative use of the laparoscope. A multi-institutional study through laparoscopic organizations would be beneficial in gathering other similar or different case reports to collect additional cases illustrating such unique approaches in the care of medically complex and metabolically challenged patients. Other limitations include the patient being lost to follow-up and what additional operations may have been required at other medical centers in the continuum of this patient’s care [9].

6. Conclusion

We present this case to highlight the broad range of applications for minimally invasive surgery and demonstrate that the laparoscope is an invaluable tool that may still be used in a wide variety of surgical techniques.

Institutional Review Board

This case report, containing only de-identified data, does not produce generalizable knowledge, nor is it an investigation of an FDA-regulated product. A case report is an educational activity and exempt from IRB review based on the Code of Federal Regulations and the Common Rule [10]. An IRB was obtained through the Midwestern University institutional review board and cleared for publication. The human data presented is in accordance with the Declaration of Helsinki. No funding was provided or obtained for the writing and development of this scientific paper. The patient did consent to the release of medical educational material.

Conflicts of Interest

The authors declare no conflicts of interest regarding the publication of this paper.

References

- [1] Nakayama, D.K. (2017) The Minimally Invasive Operations that Transformed Surgery. *Journal of the American College of Surgeons*, **2**, 64-71
- [2] Alkatout, I., Mechler, U., Mettler, L., Pape, J., Maass, N., Biebl, M., *et al.* (2021) The Development of Laparoscopy—A Historical Overview. *Frontiers in Surgery*, **8**, Article 799442. <https://doi.org/10.3389/fsurg.2021.799442>
- [3] Kelley, W.E. (2008) The Evolution of Laparoscopy and the Revolution in Surgery in the Decade of the 1990s. *Journal of the Society of Laparoscopic and Robotic Surgeons*, **12**, 351-357.
- [4] Semm, K. (1976) *Pelviskopie und Hysteroskopie: Farbatlas und Lehrbuch*. Schattauer, 7-14.
- [5] Vecchio, R., Macfayden, B.V. and Palazzo, F. (2000) History of Laparoscopic Surgery. *Panminerva Medica*, **42**, 87-90.
- [6] Litynski, G.S. (1999) Endoscopic Surgery: The History, the Pioneers. *World Journal of Surgery*, **23**, 745-753. <https://doi.org/10.1007/s002689900576>
- [7] Tobing, S.D.A.L. and Kurniawan, D. (2020) Minimally Invasive Technique for the Abscess Drainage in Lumbosacral Tuberculosis Using Arthroscopy Sheath: A Case Report. *International Journal of Surgery Case Reports*, **72**, 271-276. <https://doi.org/10.1016/j.ijscr.2020.04.007>
- [8] Rizvi, S.A.A., McManus, J., Foo, G. and Lockie, P. (2015) Laparoscopic Drainage of Iliopsoas Abscess. *CRSLS: MIS Case Reports from SLS*, **19**, 1-4. <https://doi.org/10.4293/crsls.2015.00005>
- [9] Nissen, T. and Wynn, R. (2014) The Clinical Case Report: A Review of Its Merits and Limitations. *BMC Research Notes*, **7**, Article No. 264. <https://doi.org/10.1186/1756-0500-7-264>
- [10] Breault, J.L. (2006) Protecting Human Research Subjects: The Past Defines the Future. *Ochsner Journal*, **6**, 15-20.