

Consolidation of a Femoral Neck Fracture in Sickle Cell Disease Patient after Surgical Abstention: A Beneficial and Favorable Outcome

Marc Leroy Guifo¹, Albert Desiré Atangana Fouda¹, Faustin Atemkeng Tsatedem², Emini Ngono¹, Mengale Ntang¹, Ulrich Bisay Souhe³, Ginette Kalla¹

¹Faculty of Medicine and Biomedical Sciences, University of Yaoundé 1, Yaoundé, Cameroon

²Faculty of Medicine and Pharmaceutical Sciences, University of Dschang, Dschang, Cameroon

³Faculty of Medicine and Pharmaceutical Sciences, University of Ebolowa, Ebolowa, Cameroon

Email: mlguifo@yahoo.com

How to cite this paper: Guifo, M.L., Atangana Fouda, A.D., Atemkeng Tsatedem, F., Ngono, E., Ntang, M., Bisay Souhe, U. and Kalla, G. (2024) Consolidation of a Femoral Neck Fracture in Sickle Cell Disease Patient after Surgical Abstention: A Beneficial and Favorable Outcome. *Surgical Science*, 15, 438-443.

<https://doi.org/10.4236/ss.2024.157040>

Received: June 4, 2024

Accepted: July 15, 2024

Published: July 18, 2024

Copyright © 2024 by author(s) and Scientific Research Publishing Inc.

This work is licensed under the Creative Commons Attribution International License (CC BY 4.0).

<http://creativecommons.org/licenses/by/4.0/>



Open Access

Abstract

Femoral neck fracture is classically a traumatic pathology in the elderly but it can also occur in young people during a road traffic accident or occasionally when the femoral neck has been weakened by a pathological process. In sickle cell patients, the hip is often subjected to aseptic necrosis. The authors report the case of the child NL, aged 5 years and 4 months in whom a fracture of the femoral neck classified Delbet 3 was found as well as his sickle cell status discovered and in whom treatment by surgical abstention was carried out with a favorable evolution. This association of factors of the femoral head necrosis or nonunion is unusual and confirms the osteogenetic potential of a child. However, monitoring is necessary because other anomalies may reveal themselves.

Keywords

Sickle Cell Disease, Fracture, Femoral Neck, Osteomyelitis

1. Introduction

Fracture of the femoral neck is often a pathology of the elderly with an incidence of 110 per 100,000 inhabitants. [1]. It is less common in young working people and can occur during road accidents. Schrader Wade *et al.* in 2007 collected 20 cases over 30 years in a level 1 trauma center in Germany [2] [3]. It

can also be found on a femoral neck weakened by a pathological process such as a bone cyst in a child [3]. Many studies have reported high risk of unfavorable outcome with complications like avascular necrosis, coxa vara, and limb leg discrepancy [4]. Sickle cell is the most prevalent genetic disease in the world. It is characterised by the presence of abnormal hemoglobin in red cells that has the tendency to adopt a sickle shape in the presence of low oxygen tension. When deformed, these red blood cells occlude the microcirculation with subsequent consequences as ischemia and infarction. Tissue ischemia generally manifests as pain with variable localisation call “vaso-occlusive crisis” that can be persistent if the ischemia progress to necrosis [5]. Classically the sickler are known to be at risk of osteonecrosis of the femoral head. Association of femoral neck fracture, sickle cell osteomyelitis poses a double thread on the femoral head. We report a case occurring in a child treated non-operatively with a favourable and beneficial outcome.

2. Case Presentation

The child NNL, aged 5 years and 4 months, female, was brought to the Emergency Department for pain and loss of function. The onset dates back to 3 weeks previously and the child woke up reporting pain in her lower limb with lameness in the context of a fever of 38.5°C. The mother did massages and administered paracetamol with temporary relief of pain. There is an increase in pain which leads the child to a consultation after three weeks of self-medication at home. As past history, she was hospitalized a year ago for a lung infection, not up to date with her vaccinations. She has no known blood type, she has never been transfused. On examination, she complained of pain which she localized to the knee and the distal third of the right thigh. With a limited flexion and extension, there is no inequality in limb length or vicious attitude. The diagnosis of juvenile arthritis is made in paediatrics and biological and radiological work ups are requested including a CBC, a CRP, a knee x-ray and a chest x-ray. Biology revealed leukocytosis with 15,000 white blood cells, a CRP of 24, the initial x-ray of the knee was normal (Figure 1). It is completed by an x-ray of the hip which will show cervico-metaphyseal osteolysis and a feature corresponding to a type 3 femoral neck fracture of the Delbet classification [6]) (Figure 2). The treatment will consist of traction with a reserve of screw fixation if the progression of the infection permitted. Haemoglobin electrophoresis confirms sickle cell status. With antibiotic treatment based on cefuroxime, we will observe a drop in CRP to 6 after 4 weeks and leukocytosis to 11,500. We note indolence of the limb under this protocol with a child who is increasingly mobile on the traction bed. Since the family is limited and exhausted by the long 5-week stay, a long leg cast is placed to accompany the treatment and protect the femoral neck during this consolidation phase. The progress is satisfactory with resumption of walking after removal of the cast without inequality in length (Figure 3). Monitoring is ongoing with limitation of physical activities.

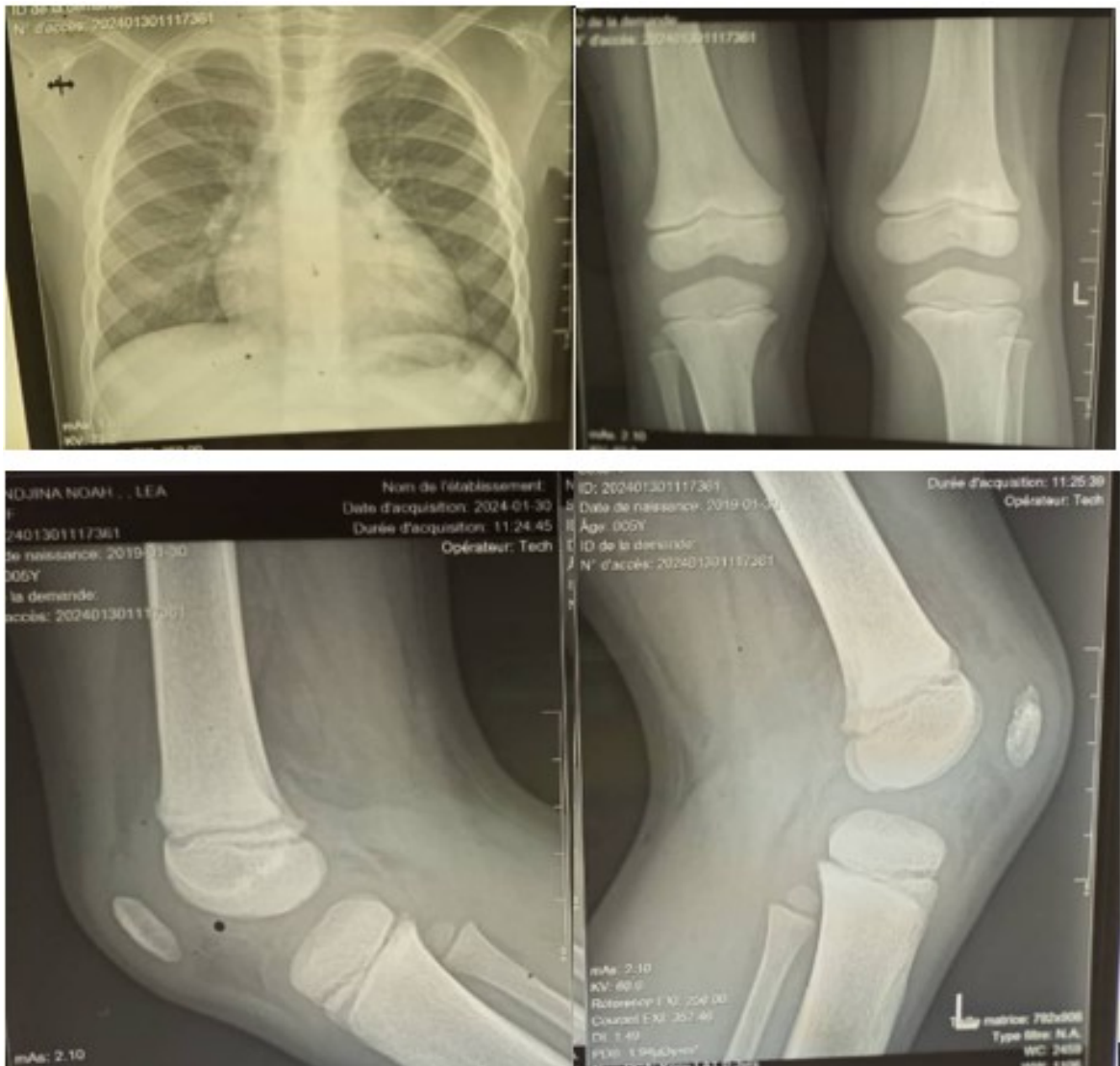


Figure 1. Initial radiological assessment.

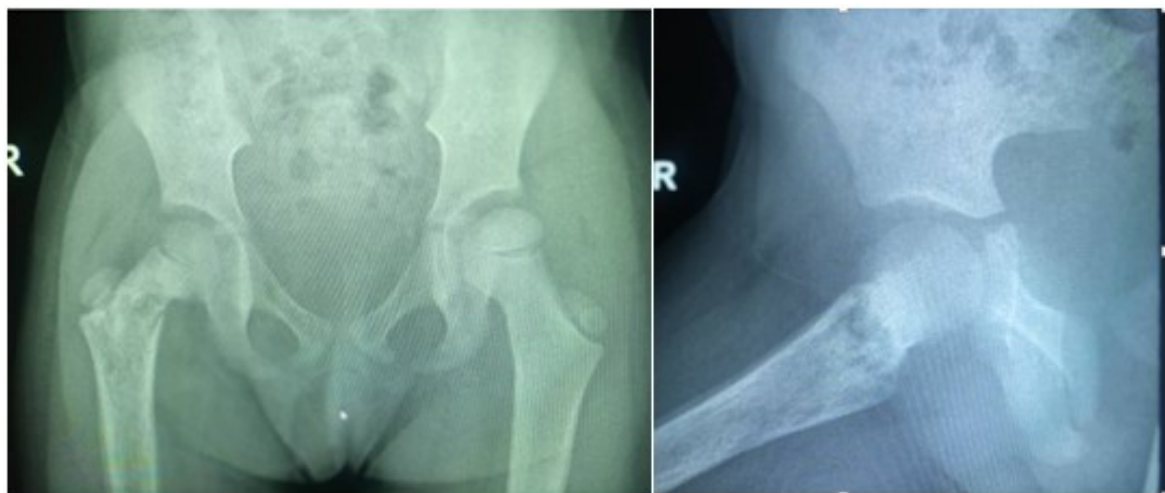

Figure 2. Additional radiological assessment.

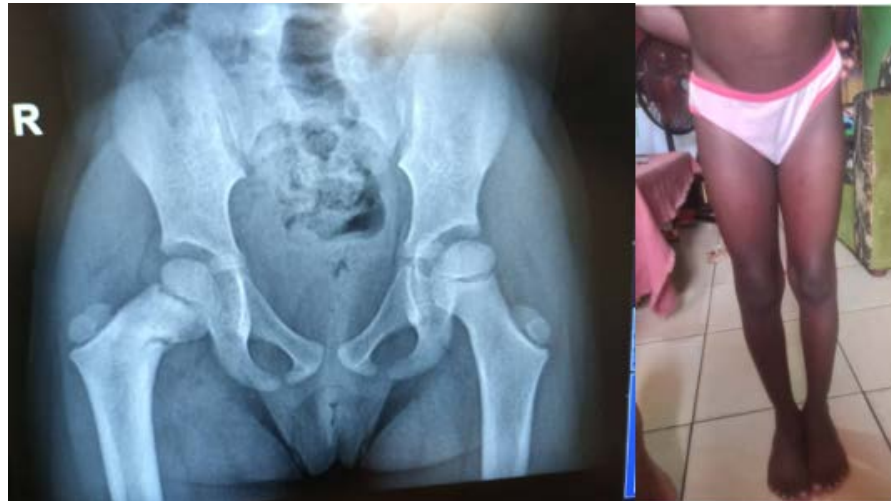

Figure 3. Radiological appearance and image of the patient in bipedal support after 10 weeks.

3. Discussion

Femoral neck fracture in children represents less than 1% of fractures [7]. This reflects a bone structure different from adults with a thick periosteum and higher bone density. These fractures can nevertheless occur in high-energy trauma or when the bone structure has been weakened. Sickle cell disease is a common pathology in black people and is one of the most widespread genetic diseases [8]. It is responsible for a known and often feared complication, avascular necrosis of the femoral head [8]-[10]. The combination of two factors of avascular necrosis of the femoral head (fracture and sickle cell disease) and the coexistence of an infection exacerbated the risk of this eventuality and made this clinical case unique. Femoral neck fractures in children are classified into 4 stages according to Delbet [6] [11].

In this patient, a knee lesion was initially suspected, which is a classic situation for hip pathologies which are often referred to the knee due to the innervation of the knee by a branch of the obturator nerve. This suspicion was quickly corrected.

A certain number of constraints are known for the management of femoral fractures in children of school age; the financial and social cost that this imposes on parents and families makes orthopaedic treatment unattractive [12]. In this patient we chose conservative treatment due to the risk of infection which did not allow for screw fixation. Besides the major risk represented by avascular necrosis, other anomalies may reveal themselves with progression: coxa vara, length inequality or recurrence of fracture. In a study studying the modifications that antergrade elastic nailing could induce on the development of the proximal end of the femur involving 27 fractures in 25 patients, TP Carey *et al.* [12] analyzed parameters such as: the distance from the top of the femur trochanter and joint space, the minimum diameter of the femoral neck, the cervico-femoral angle and the lengths of the limbs. The cervico-femoral angle was different in our

patient between the two sides.

At medium term, this patient presents clinically with signs of consolidation with painless walking and no apparent inequality. On the x-ray we observe the disappearance of the fracture line. This seemed beneficial and we recommend abstaining from physical exercise till complete remodelling of the bone which still seems to present a heterogeneous appearance on the 10-week x-ray.

In the absence of infection, another treatment could have consisted of simple screw fixation or screw fixation with a non-vascularized cortico-cancellous graft [13]. For the latter, it is a technically difficult procedure and requires experience, which is not consistent with the rarity of cases. As a last resort, a resection without interposition according to the principle of the Gilderstone procedure can allow indolence and a minimum of function for complicated cases of avascular necrosis while awaiting the possibility of total hip replacement in adulthood [14].

4. Conclusion

A non-displaced femoral neck fracture in children is accessible to simple orthopaedic management by traction followed by cast support. The existence of displacement makes the result of non-operative treatment uncertain. In the case of sickle cell disease, the risks of avascular necrosis are increased, however, the child is known for his capacity of osteogenesis which results in beneficial remodelling of fractures in the event of malunion. This osteogenesis is not lost in sickle cell patients and has probably, along with effective antibiotic therapy contributed to a favourable outcome of this treatment.

Conflicts of Interest

The authors declare no conflicts of interest regarding the publication of this paper.

References

- [1] Szymiski, D., Walter, N., Lang, S., Baertl, S., Weber, J., Alt, V., *et al.* (2022) Incidence and Treatment of Intracapsular Femoral Neck Fractures in Germany. *Archives of Orthopaedic and Trauma Surgery*, **143**, 2529-2537. <https://doi.org/10.1007/s00402-022-04504-3>
- [2] Shrader, M.W., Jacofsky, D.J., Stans, A.A., Shaughnessy, W.J. and Haidukewych, G.J. (2007) Femoral Neck Fractures in Pediatric Patients: 30 Years Experience at a Level 1 Trauma Center. *Clinical Orthopaedics and Related Research*, **454**, 169-173. <https://doi.org/10.1097/01.blo.0000238794.82466.3d>
- [3] Taneda, H. and Azuma, H. (1994) Avascular Necrosis of the Femoral Epiphysis Complicating a Minimally Displaced Fracture of Solitary Bone Cyst of the Neck of the Femur in a Child. *Clinical Orthopaedics and Related Research*, **304**, 172-175. <https://doi.org/10.1097/00003086-199407000-00026>
- [4] Azam, M., Iraqi, A., Sherwani, M., Abbas, M., Alam, A., Sabir, A., *et al.* (2009) Delayed Fixation of Displaced Type II and III Pediatric Femoral Neck Fractures. *Indian Journal of Orthopaedics*, **43**, 253. <https://doi.org/10.4103/0019-5413.53455>

- [5] Yolande, D.P.F., Tufong, K.A., Jules, T.M., Mayah, A.P., Charlotte, E.E., Njinkui, D.N., *et al.* (2021) Osteomyelitis in Children with Sickle Cell Disease: A Challenging Diagnosis: Case Report from Cameroon. *Open Journal of Pediatrics*, **11**, 208-214. <https://doi.org/10.4236/ojped.2021.112020>
- [6] Duffy, S., Gelfer, Y., Trompeter, A., Clarke, A. and Monsell, F. (2021) The Clinical Features, Management Options and Complications of Paediatric Femoral Fractures. *European Journal of Orthopaedic Surgery & Traumatology*, **31**, 883-892. <https://doi.org/10.1007/s00590-021-02933-1>
- [7] Panigrahi, R., Sahu, B., Mahapatra, A.K., Palo, N., Priyadarshi, A. and Biswal, M.R. (2015) Treatment Analysis of Paediatric Femoral Neck Fractures: A Prospective Multicenter Therapeutic Study in Indian Scenario. *International Orthopaedics*, **39**, 1121-1127. <https://doi.org/10.1007/s00264-015-2677-y>
- [8] Ouederni, M., Rouag, H., Ben Fraj, I., Rekaya, S., Kouki, R., Lamouchi, T., *et al.* (2023) Incidence and Risk Factors for Osteonecrosis of the Femoral Head in Five Hundred and Ten Sickle Cell Disease Paediatric Patients. *International Orthopaedics*, **47**, 2941-2952. <https://doi.org/10.1007/s00264-023-05886-8>
- [9] Sadat-Ali, M. (1993) Avascular Necrosis of the Femoral Head in Sickle Cell Disease. *Clinical Orthopaedics and Related Research*, **290**, 200-205. <https://doi.org/10.1097/00003086-199305000-00026>
- [10] Li, Z.Q., Zhuang, Z.K., Hong, Z.N., Chen, L.L., He, W. and Wei, Q.S. (2021) Avascular Necrosis after Femoral Neck Fracture in Children and Adolescents: Poor Prognosis and Risk Factors. *International Orthopaedics*, **45**, 2899-2907. <https://doi.org/10.1007/s00264-021-05210-2>
- [11] Wang, W.T., Huang, D.H., Xiong, Z., Guo, Y.M., Liu, P.R., Li, M., *et al.* (2023) Is There an Alternative to the Delbet-Colonna Classification? Introduction and Reliability Assessment of a New Classification System for Paediatric Femoral Neck Fractures: Preliminary Results. *International Orthopaedics*, **48**, 1507-1516. <https://doi.org/10.1007/s00264-023-06051-x>
- [12] Carey, T.P. and Galpin, R.D. (1996) Flexible Intramedullary Nail Fixation of Pediatric Femoral Fractures. *Clinical Orthopaedics and Related Research*, **332**, 110-118. <https://doi.org/10.1097/00003086-199611000-00015>
- [13] Roshan, A. and Ram, S. (2006) Early Return to Function in Young Adults with Neglected Femoral Neck Fractures. *Clinical Orthopaedics & Related Research*, **447**, 152-157. <https://doi.org/10.1097/01.blo.0000203483.13583.c8>
- [14] Fischer, H., Maleitzke, T., Eder, C., Ahmad, S., Stöckle, U. and Braun, K.F. (2021) Management of Proximal Femur Fractures in the Elderly: Current Concepts and Treatment Options. *European Journal of Medical Research*, **26**, Article No. 86. <https://doi.org/10.1186/s40001-021-00556-0>