

Hydrodissection of Greater Occipital Nerve for Migraine Treatment: A Case Report

Elizabeth Wong, Dominic C. Harmon*

School of Medicine, University of Limerick, Limerick, Ireland

Email: *harmondominic@gmail

How to cite this paper: Wong, E. and Harmon, D.C. (2025) Hydrodissection of Greater Occipital Nerve for Migraine Treatment: A Case Report. *Pain Studies and Treatment*, 13, 37-42.

<https://doi.org/10.4236/pst.2025.132005>

Received: March 10, 2025

Accepted: March 28, 2025

Published: March 31, 2025

Copyright © 2025 by author(s) and Scientific Research Publishing Inc.

This work is licensed under the Creative Commons Attribution International License (CC BY 4.0).

<http://creativecommons.org/licenses/by/4.0/>



Open Access

Abstract

Peripheral nerve hydrodissection is a novel technique that can be applied in the treatment of neuropathic pain and musculoskeletal medicine. However, hydrodissection for migraine treatment has not been previously reported. We present the case of an 85-year-old female with recurrent migraine. Despite extensive conservative therapies she continued to experience recurrent migraine. The patient underwent ultrasound-guided bilateral greater occipital nerve hydrodissection as a targeted approach to address perineural inflammation or nerve entrapment of the Greater Occipital Nerve. Hydrodissection with 10 mL of 5% dextrose solution of the greater occipital nerve was performed at the level of C2 vertebrae in a theatre setting. Following the procedure, the patient experienced improvement in migraine, with sustained improvement over three months, at follow-up. Functional outcomes, including daily activities, improved substantially. No complications were reported. This is the first case to support the potential role of dextrose hydrodissection as a safe, minimally invasive treatment option for recurrent migraine. These results warrant further investigation of this technique in the management of recurrent migraine.

Keywords

Greater Occipital Nerve, Hydrodissection, Migraine, Technique, Ultrasound

1. Introduction

Migraines are a common and disabling type of headache characterized by unilateral, throbbing and severe pain [1]. The most common associated symptoms are neck pain followed by vomiting, photophobia and phonophobia [1]. The pathophysiology of migraine is complex and not fully understood. Migraines are theorized to originate from the activation of trigeminal afferent fibers which could be triggered by upstream neural events, dilation of blood vessels, or myofascial input

[2] [3]. The trigeminocervical complex theory postulates that sensory input from upper cervical nerves, including the greater occipital nerve (GON), connect to the trigeminal afferent nerves by converging onto the trigeminal nucleus caudalis neurons in the brainstem [1]. This theory provides the rationale for the application of a nerve block of the GON in the treatment of migraine. In a GON block, local anesthetic inhibits afferent stimuli that comes from regions innervated by the GON and thus decreases the input into the trigeminal nucleus caudalis [4]. However, the duration of analgesia from a nerve block is limited as there has been reports of recurrence of pain upon fading of the local anesthetic effect [5]. To our knowledge, this is the first case of successful treatment of migraine using ultrasound-guided hydrodissection of the GON.

The GON is composed of sensory nerves that originate in the dorsal root ganglion of C2 and C3 [6]. Its sensory distribution includes the posterior aspect of the head until the vertex where it meets areas supplied by the ophthalmic division of the trigeminal nerve [6]. The tortuous path of the GON involves emerging between the atlas and axis, followed by traversing in between the inferior obliquus capitis muscle and semispinalis capitis muscle, piercing the semispinalis capitis muscle and finally perforating the aponeurotic fibers of the trapezius muscle to reach the scalp [7]. At each of these points noted the GON is vulnerable to nerve entrapment, irritation or muscular compression which can cause altered nerve transmission resulting in the clinical presentation of pain and paraesthesia [7] [8].

Ultrasound guided hydrodissection of peripheral nerves is an emerging technique that involves injecting solution into fascia to release entrapped nerves or separate nerves from their surrounding structures [8]. Hydrodissection of the GON has been implicated in treatment of neuropathic pain with myofascial origins such as occipital neuralgia and cervicogenic headache [5] [7]. Therefore, hydrodissection of the GON has the potential to address similar nerve irritation in the treatment of migraines.

2. Case Report

An 85-year-old patient presented to Pain Management Center at Croom Orthopaedic Hospital with recurrent migraine. The patient reported suffering from migraine since the age of 11 years of age. The migraine is associated with an aura that causes a unilateral complete loss of visual field. Prior to age 70, the patient recalls suffering from a migraine once a week with a severity that could reach up to 10 out of 10 on a pain scale. In a severe attack, the pain could last over 24 hours and would be incapacitating in nature leading to bed rest as relief. After age 70, the frequency of migraines reduced to about once every two months with a severity of 8 out of 10 on the pain scale. The patient was unable to determine the cause for the decrease in frequency at age 70. With respect to past treatment, the patient tried prophylactic treatment with 10 mg amitriptyline, however, this was discontinued due to failure to resolve the migraines and the side effect profile adequately. In 2020, the patient received treatment with botulinum toxin at the Pain Management

Center and reported a good response. The patient had no other medical history.

The patient was informed about the procedure of ultrasound guided GON hydrodissection and informed consent was obtained. The patient was positioned in a prone position and was encouraged to breathe normally. An ultrasound machine (Sonosite Micromaxx) with 4 - 5 MHz frequency was used with a linear transducer. The procedure was performed in a theatre setting under aseptic conditions. The ultrasound probe was placed in the suboccipital area in the transverse orientation at the level of C2 - C3 vertebrae. Using the C2 transverse process as a landmark, the probe was moved laterally to identify the obliquus capitis inferior muscle (OCIM), semispinalis capitis muscle and splenius capitis muscle (**Figure 1**). The target point was determined when the GON was found to be superficial to the OCIM. A 22-gauge spinal needle was inserted “in plane” beneath the transducer (**Figure 1**). The needle advanced from medial to lateral until the needle tip was positioned at the target point. Hydrodissection of the GON was performed bilaterally by slowly injecting 10 ml of low concentration (5%) dextrose solution (**Figure 1**).

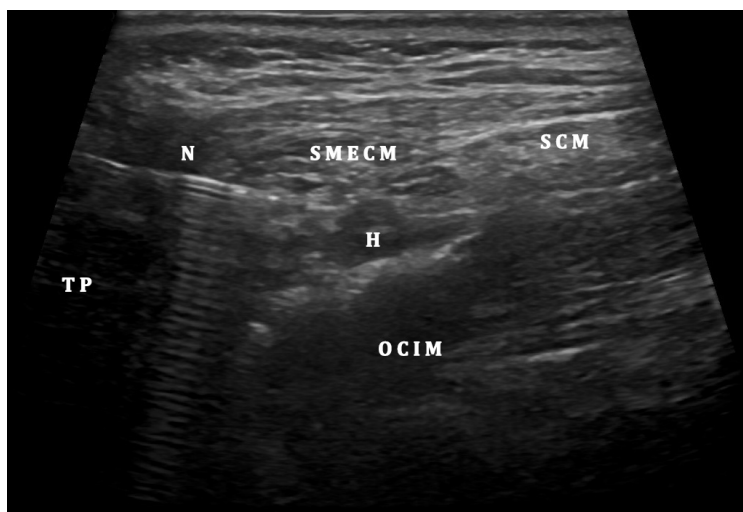


Figure 1. Labelled ultrasound image of the greater occipital hydrodissection. Hydrodissection of the GON at the C2 level under ultrasound guidance. Abbreviations: **N**: needle, **H**: Hydrodissection, **TP**: Transverse process, **OCIM**: Obliquus capitis inferior muscle, **SMECM**: semispinalis capitis muscle, **SCM**: splenius capitis muscle.

There were no complications after the procedure was complete. Following the hydrodissection procedure, the patient experienced improvement in migraine, with sustained improvement over two months, at follow-up. She reported that she had not experienced a migraine since the procedure at three months follow up. She described functional outcomes, including daily activities, had improved substantially.

3. Discussion

This case supports the potential role of hydrodissection of the GON as a safe and minimally invasive treatment option for recurrent migraine. Pharmacological

therapy of migraines includes treatment with antidepressants, antiepileptics, calcium channel blockers, beta-blockers, and monoclonal antibodies against calcitonin gene related peptide (CGRP) [2]. However, up to 40% of patients with chronic migraine either become refractory or do not respond to pharmacological therapy highlighting the complex pathophysiology and need for more non-pharmacological treatment options [3] [9]. Hydrodissection is a minimally invasive technique that offers an alternative to more invasive interventions.

Peripheral nerve hydrodissection is a novel technique that can be applied in the treatment of neuropathic pain and musculoskeletal medicine [10]. Pain due to peripheral nerve compression or entrapment are common but underrecognized [9]. Nerve entrapment is defined as altered transmission due to mechanical irritation from an anatomical neighbour and can clinically manifest as numbness, paralysis or neuropathic pain [9]. Furthermore, compressed nerves can release inflammatory mediators which can exacerbate the pain [9]. Interestingly, hydrodissection with 5% dextrose was proposed to reduce neuropathic pain by inhibiting the release of CGRP, an inflammatory mediator also implicated in the pathogenesis of migraines [9]. The inhibition of CGRP is currently used in the treatment of migraine with monoclonal antibodies and botulinum toxin [3]. This proposition strengthens the rationale behind the treatment of migraine with GON hydrodissection emphasizing its validity and importance.

Hydrodissection is a technique that requires advanced skills in ultrasound guided needling techniques. It involves injection of fluid around the target nerve to release it from surrounding soft tissue [10]. The potential complications include infection or nerve injury by hitting the nerve with a needle or compressing the nerve with excess volume. These complications can be limited by using an aseptic protocol and performed by a skilled specialist. By using 5% dextrose, there is a decreased risk of adverse reactions to the medications lending towards the safety of the procedure.

The GON is well suited for the technique due to its superficial nature and clear visualization of surrounding soft tissue. Hydrodissection of the GON for migraine treatment could potentially be indicated in patients that are non-responders to pharmacological therapy. The results of this case report warrant further investigation in the management of recurrent migraine with hydrodissection of the GON.

4. Conclusion

This is the first case to support the potential role of dextrose hydrodissection as a safe, minimally invasive treatment option for recurrent migraine. These results warrant further investigation of this technique in the management of recurrent migraine.

Acknowledgements

We would like to extend our gratitude to the patient for her consent to publish this report.

Statements and Declarations

Conflicts of Interest

There were no other competing interests involved in this research. There was no support from any organisation for the submitted work and no other relationships or activities that could appear to have influenced the submitted work.

Availability of Data and Material/Data Transparency

This case report is an honest, accurate, and transparent account of the case being reported. No important aspects of the report have been omitted. Any queries should be directed to the corresponding author via email. Requests for reprints should also be addressed to the corresponding author.

Ethics Approval

This study is fully compliant with the ethical guidelines of the Research Ethics and Clinical Trials Committee of the University of Limerick Hospitals Group.

Consent to Participate

The patient described consented to participation and publication of the report as described.

Consent for Publication

The corresponding author has the right to grant on behalf of all authors and does grant on behalf of all authors, an exclusive licence to PAIN Practice to permit this case report (if accepted) to be published in PAIN Practice editions.

References

- [1] Karaođlan, M. and İnan, L.E. (2022) A Comparison of the Clinical Efficacy of GON Block at the C2 Level and GON Block at the Classical Distal Occipital Level in the Treatment of Migraine. *Clinical Neurology and Neurosurgery*, **215**, Article 107190. <https://doi.org/10.1016/j.clineuro.2022.107190>
- [2] Malekian, N., Bastani, P.B., Oveisgharan, S., Nabaei, G. and Abdi, S. (2021) Preventive Effect of Greater Occipital Nerve Block on Patients with Episodic Migraine: A Randomized Double-Blind Placebo-Controlled Clinical Trial. *Cephalalgia*, **42**, 481-489. <https://doi.org/10.1177/03331024211058182>
- [3] Sangalli, L., Eli, B., Mehrotra, S., Sabagh, S. and Fricton, J. (2023) Calcitonin Gene-Related Peptide-Mediated Trigeminal Ganglionitis: The Biomolecular Link between Temporomandibular Disorders and Chronic Headaches. *International Journal of Molecular Sciences*, **24**, Article 12200. <https://doi.org/10.3390/ijms241512200>
- [4] Velásquez-Rimachi, V., Chachaima-Mar, J., Cárdenas-Baltazar, E.C., Loayza-Vidalon, A., Morán-Mariños, C., Pacheco-Barrios, K., *et al.* (2022) Greater Occipital Nerve Block for Chronic Migraine Patients: A Meta-analysis. *Acta Neurologica Scandinavica*, **146**, 101-114. <https://doi.org/10.1111/ane.13634>
- [5] Kaga, M. (2022) First Case of Occipital Neuralgia Treated by Fascial Hydrodissection. *American Journal of Case Reports*, **23**, e936475. <https://doi.org/10.12659/ajcr.936475>

- [6] Ashkenazi, A. and Levin, M. (2007) Greater Occipital Nerve Block for Migraine and Other Headaches: Is It Useful? *Current Pain and Headache Reports*, **11**, 231-235. <https://doi.org/10.1007/s11916-007-0195-3>
- [7] Ryan, P.J. and Harmon, D.C. (2023) Ultrasound-guided Greater Occipital Nerve Hydrodissection for Treatment of Cervicogenic Headache: A Case Report. *Pain Studies and Treatment*, **11**, 1-8. <https://doi.org/10.4236/pst.2023.111001>
- [8] Trescot, A. and Brown, M. (2015) Peripheral Nerve Entrapment, Hydrodissection, and Neural Regenerative Strategies. *Techniques in Regional Anesthesia and Pain Management*, **19**, 85-93. <https://doi.org/10.1053/j.trap.2016.09.015>
- [9] Tang, Y., Kang, J., Zhang, Y. and Zhang, X. (2017) Influence of Greater Occipital Nerve Block on Pain Severity in Migraine Patients: A Systematic Review and Meta-analysis. *The American Journal of Emergency Medicine*, **35**, 1750-1754. <https://doi.org/10.1016/j.ajem.2017.08.027>
- [10] Lam, K.H.S., Hung, C., Chiang, Y., Onishi, K., Su, D.C.J., Clark, T.B., *et al.* (2020) Ultrasound-Guided Nerve Hydrodissection for Pain Management: Rationale, Methods, Current Literature, and Theoretical Mechanisms. *Journal of Pain Research*, **13**, 1957-1968. <https://doi.org/10.2147/jpr.s247208>