

Splenic Torsion in a Domestic Short Hair Cat: Diagnostic Imaging and Surgical Management

Boris Masnov*^{}, Eleonora D’Incecco^{}, Anna-Maria Adrian^{}

Frontier Kleintierspezialisten, Hergolding, Germany

Email: *b.masnov@frontier.vet

How to cite this paper: Masnov, B., D’Incecco, E. and Adrian, A.-M. (2026) Splenic Torsion in a Domestic Short Hair Cat: Diagnostic Imaging and Surgical Management. *Open Journal of Veterinary Medicine*, 16, 17-25.
<https://doi.org/10.4236/ojvm.2026.162002>

Received: December 30, 2025

Accepted: February 25, 2026

Published: February 28, 2026

Copyright © 2026 by author(s) and Scientific Research Publishing Inc. This work is licensed under the Creative Commons Attribution International License (CC BY 4.0).
<http://creativecommons.org/licenses/by/4.0/>



Open Access

Abstract

An 11-year-old spayed domestic shorthair cat was presented for evaluation of significant weight loss with a palpable abdominal mass. Ultrasonography revealed a severely enlarged spleen with findings suggestive of splenic torsion, including folding and vascular abnormalities. Colour Doppler flow was still present. Exploratory laparotomy confirmed complete splenic torsion with capsular rupture and hemoperitoneum. Splenectomy was performed. Histopathology confirmed torsion with congestion and hemorrhage. The patient initially responded well postoperatively but was euthanised two weeks later due to suspected intra-abdominal abscess formation. Relevance and novel information: This report adds to the limited literature on feline splenic torsion. The detection of Doppler flow in a torsed spleen challenges previously established ultrasound criteria, suggesting species-specific variations or transient perfusion. Given the rarity of this condition in cats, it should be considered a differential in cases of acute abdominal signs and splenomegaly, even when Doppler flow is present.

Keywords

Splenic Torsion, Hemoabdomen, Ultrasound, Laparotomy

1. Introduction

Splenic torsion, though extremely rare in cats, is a condition that requires immediate medical attention due to the potential for severe complications such as splenic infarction, rupture, and haemorrhage. To the authors’ knowledge, there is only one case report describing a cat with splenic torsion with concurrent splenitis and chronic anaemia [1]. This case report details the ultrasonographic findings of splenic torsion in a cat, with one key distinction from previously published cases: in our case, a color Doppler signal was detected in the splenic vasculature. In dogs,

splenic torsion commonly appears secondary to gastric dilatation and volvulus [2]. Primary splenic torsion, an isolated rotation of the spleen around the gastro-splenic and phrenicosplenic ligaments, is also well-described in canines [3]. Primary splenic torsion is most common in large and giant deep-chested breeds for example German shepherd and Great Danes [3], although it is also described in smaller dog breeds [4]. Splenic torsion can be partial or complete, and in canine patients, this condition is readily diagnosed using B-mode ultrasound [5]. The ultrasonographic findings of splenic torsion include splenomegaly, a diffuse, mottled, or lacy pattern of the spleen, hypoechoic parenchyma, and absence or reduction of the colour Doppler signal in the splenic vein [5] [6]. Furthermore, the surrounding fat tissue may become hyperechoic, and a hyperechoic, triangular perihilar finding may be supportive of the diagnosis of acute splenic torsion in dogs [5] [7].

2. Case Description

2.1. History and Clinical Examination

A 11-year-old female, outdoor domestic shorthair cat was referred to our institution for evaluation and work-up of weight loss and possible abdominal mass. The owner reported weight loss of over 1 kg in the last 2 weeks and history of chronic pancreatitis, which was diagnosed two years ago. Six months prior to presentation to our clinic, the cat was treated for rhinitis, and mild splenomegaly was already suspected by the referring veterinarian. At time of presentation, the cat was eating well, and no lethargy was reported by the owner. On clinical examination the cat was alert, slightly pale mucous membranes were noted, capillary refill time was less than 2 seconds, body temperature was 37.9°C, heart rate was 186 bpm, respiratory rate was 30/min, a strong pulse was palpable and on palpation a tense, distended abdomen was noted. All of the peripheral lymph nodes were unremarkable.

2.2. Diagnostic Imaging and Findings

An abdominal ultrasound was performed using LOGIQ E10 (GE Healthcare Medical Systems, Chicago) with both microconvex 3 - 10 MHz (C3-10) and linear transducers 4 - 15 MHz (ML6-15) and revealed a severely enlarged and rounded spleen. The spleen appeared folded and rotated. Multiple peripheral, well-defined hypoechoic changes were visible in the parenchyma. These appeared partly rounded, partly linear, with a partly hyperechoic rim. It seemed that the number of these lesions increased during the examination (**Figure 1**). The largest lesion appeared to have broken through the splenic capsule. A colour Doppler signal was present in the intrasplenic vasculature. A moderate amount of anechoic free fluid with hyperechoic particles was present. The gallbladder wall was subjectively hyperechoic, smooth, mildly thickened, measuring 2.6 mm. Intraluminally, a well-defined hyperechogenic structure without acoustic shadowing was observed. No dilatation of the ductus cysticus or common bile duct was identified. The remainder of the abdominal organs were ultrasonographically unremarkable. In conclusion, partial or complete splenic torsion with secondary splenic capsule

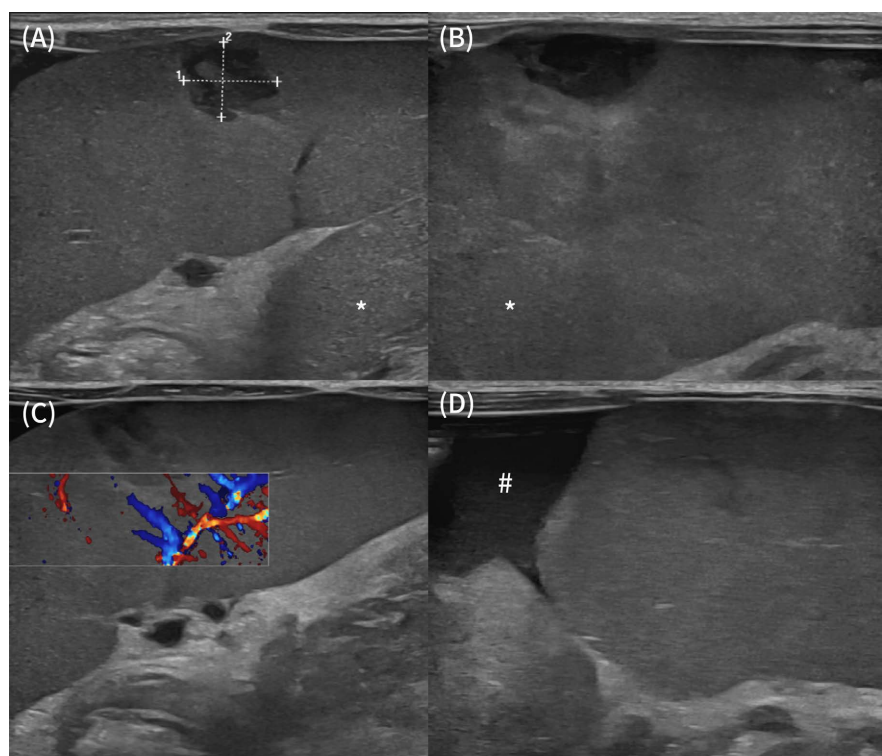


Figure 1. Note the severe splenomegaly and folding of the splenic parenchyma - white asterisks (A). There are multiple peripheral, well-defined hypoechoic and heterogenous changes visible in the parenchyma (A)-(C). A clear colour Doppler signal is visible in the intrasplenic vasculature (C). Note a small amount of anechoic peritoneal effusion surrounding the spleen (white hashtag in (D)).

and parenchymal rupture was highly suspected, causing a secondary hemoabdomen. Findings in the gallbladder could have been consistent with possible cholangiohepatitis, cholangitis, secondary to previously reported mild chronic pancreatitis, or might have been considered physiological.

2.3. Laboratory Findings

On the day of presentation, only hematology was performed. A moderate to severe normochromic and normocytic, non-regenerative anemia with mild to moderate thrombocytopenia was present. The non-regenerative anemia is considered most consistent with acute intra-abdominal blood loss, representing a pre-regenerative phase before an appropriate erythropoietic response could occur. No blood smear was performed to confirm the thrombocytopenia, given that sequestration of thrombocytes was highly likely.

2.4. Surgery

The patient was premedicated with methadone. Anesthesia was induced with propofol and midazolam intravenously to effect, and maintained with inhalation anesthesia using isoflurane in a mixture of oxygen and air. The patient's vital parameters were continuously monitored during anesthesia.

A median celiotomy was performed and a hemoperitoneum was present. The spleen was ruptured, and identified as the source of bleeding. The whole spleen was completely rotated around the pedicle, with a mass at the cranial pole. The splenic vessels were individually ligated with sutures near the pancreas and then transected, followed by removal of the spleen. A biopsy sample was sent from the removed spleen. Additionally, the gallbladder was severely thickened. A duodenotomy was performed, and the bile duct was catheterized. The patency of the common bile duct and cystic duct was proven and the aforementioned ducts were flushed with saline solution. Thorough abdominal lavage was performed with saline solution. Wound closure was performed in three layers: abdominal cavity closure with continuous sutures using PDS, subcutaneous sutures with continuous sutures, and skin closure with continuous sutures using Monocryl.

2.5. Histopathology

Histological examination of the spleen revealed results that were consistent with passive congestion caused by a torsion (**Figure 2**).

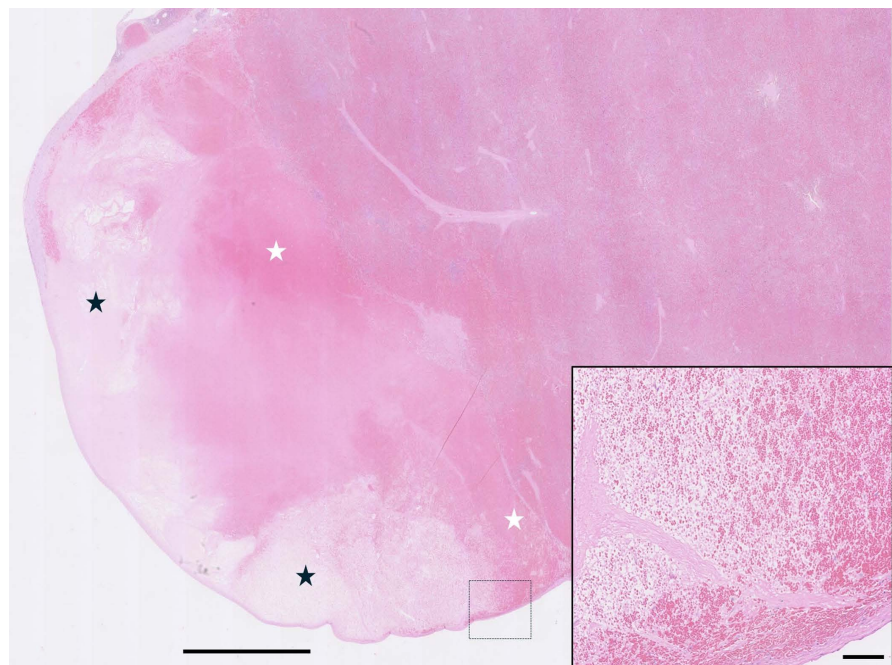


Figure 2. An area of the spleen exhibiting marked congestion with haemorrhage (white stars) and necrosis (black stars). Haematoxylin and eosin. Magnification $\times 7.5$, scale bar = 2.5 mm. Inset: Magnification $\times 200$, scale bar = 100 μm .

2.6. Postoperative Management and Outcome

Postoperatively, the patient remained stationary in our facility's intensive care unit for 4 days. Perioperatively, methadone was given according to Glasgow's pain score for pain management and Cephalexin for the suspected possibility of infection development. Daily monitoring of the complete blood count and the first-day post surgically biochemistry profile was done. Blood examination revealed nor-

malisation of thrombocyte numbers, regenerative anaemia with a marked increase in reticulocyte numbers, and marked leukocytosis. On complete biochemistry and electrolyte profile, a mild hypoalbuminemia of 20 g/l was noted, which was suspected to be due to blood loss and splenectomy. An ultrasound re-examination was performed one day post surgically, and a paralytic ileus was diagnosed, hence a constant rate infusion of metoclopramide was initiated alongside with intravenous administration of maropitant 1 mg/kg SID and pantoprazole 1 mg/kg SID. The patient was released after 5 days of intensive treatment with moderate anaemia, moderate leukocytosis, predominantly lymphocytosis, normal thrombocyte numbers, and in good clinical condition with a normal appetite. After initial great improvement in condition, the patient was re-admitted to our facility two weeks after clinical discharge because of an acute onset of lethargy and anorexia. On clinical examination normal body temperature of 38.7, pink to pale mucosal membranes, CRT less than 2 seconds and borderline bradycardia of 160 bpm and strong pulse were noted. On abdominal palpation, an intra-abdominal mass was suspected. An ultrasound was performed and a high level of suspicion for an intra-abdominal abscess possibly originating from the omentum or pancreas was made (**Figure 3**). No cytological or histopathological confirmation was obtained, as further diagnostic procedures were declined by the owner. The owner decided not to continue with further therapy and the patient was euthanised.

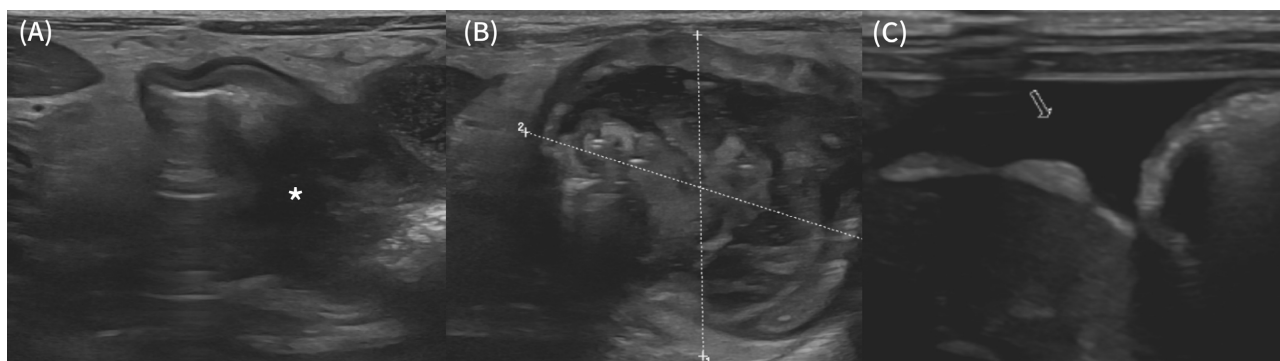


Figure 3. A hyperechoic intra-abdominal fat is visible caudal to the liver and between the small intestinal loops (A). In the close proximity with the small intestine loop, there is a heterogenous, well defined mass and possible adhesion with the intestine (white asterisk) is suspected (B). A heterogenous well defined, rounded, approximately 4 cm in diameter and possibly encapsulated mass is visible in the mid ventral abdomen (B). Note the mild to moderate amount of anechoic peritoneal effusion (white arrow) and hyperechoic intra-abdominal fat (C).

3. Discussion

Splenic torsion is an extremely rare condition in cats, with previously only one other documented case [1]. The clinical presentation and ultrasonographic findings in this case were consistent with those reported in splenic torsion cases in other species, such as dogs, where the condition is more commonly recognized. This report adds valuable information to the scant literature on feline splenic torsion, particularly in terms of ultrasonographic characteristics and postoperative outcomes.

Ultrasound is a key diagnostic tool in the identification of splenic torsion. In dogs, splenomegaly with a diffuse, mottled, or lacy splenic pattern, hypoechoic parenchyma, and an absence or reduction of the color Doppler signal are typical findings [5] [6]. Splenomegaly is a relatively rare finding in cats and most of the time is secondary to neoplastic transformation of the splenic tissue such as lymphoma or mast cell tumor [8] [9]. Splenomegaly is often reported secondary due to anaesthesia and sedation in dogs but given the difference in sinusoid splenic tissue in cats, there is only a small significant response of the splenic parenchyma to general anaesthesia [8] [10]. Fine needle aspiration (FNA) is commonly used to determine the underlying cause of the splenomegaly, and it is considered a safe procedure [5]. In our case, authors decided against the FNA of the enlarged spleen because the suspicion of a possible splenic torsion was made and explorative laparotomy was planned. A regional lymphadenomegaly was reported in a previous case of splenic torsion and splenitis might be a possible cause of that. It is unclear why regional lymphadenomegaly was visible in our case, given that no histopathological changes were reported. However, our case demonstrated a marked difference compared to previously reported splenic torsion in a cat. Despite the complete torsion of the splenic pedicle, a clear color Doppler signal was observed throughout the splenic tissue. This finding is unexpected and contrasts with the usual presentation of splenic torsion in dogs, where Doppler flow is typically absent due to compromised blood supply. One potential explanation for the presence of Doppler flow could be a partial torsion at the time of the ultrasound examination, which later progressed to complete torsion. However, this is considered unlikely given the short amount of time between the ultrasound examination and surgery. Another hypothesis is that arterial flow was retained despite venous occlusion, a phenomenon not commonly described but theoretically possible. The degree of pedicle rotation may have contributed to the observed Doppler signal, as extensive torsion can disproportionately compromise venous drainage while permitting low-grade arterial inflow, due to the higher intraluminal pressure of arteries. This imbalance could result in splenic congestion and splenomegaly while still allowing detectable intraparenchymal blood motion on colour Doppler examination. Importantly, colour Doppler ultrasound detects blood motion rather than effective tissue perfusion, therefore, persistent arterial inflow or congested intravascular flow within the spleen may generate a Doppler signal despite functionally compromised venous drainage. Further investigation into the vascular dynamics of splenic torsion in cats could provide insight into this anomaly.

Splenic torsion can be classified as either acute or chronic, depending on the location of vascular compromise. In chronic splenic torsion, the spleen rotates distal to the splenic hilus. If collateral veins, such as the splenogonadal or left gastroepiploic vein remain uninvolved, alternative venous pathways may develop, facilitating drainage from the spleen into the systemic circulation [11]. This adaptation can reduce venous congestion, resulting in more subtle clinical signs. In contrast, acute splenic torsion typically occurs near the splenic hilus, without the

possibility of collateral compensation. This leads to rapid-onset, severe splenic venous congestion, marked splenomegaly, and potential capsular distension or rupture. In our case, the combination of acute clinical deterioration, severe splenomegaly, absence of identifiable collateral circulation, and evidence of splenic rupture is consistent with an acute splenic torsion.

The findings in this case are in some ways similar to those reported in the previous case of feline splenic torsion, particularly the presence of splenomegaly, haemoperitoneum, and regional lymphadenopathy. However, the previous case did not report the unusual Doppler findings seen here, suggesting variability in the ultrasonographic appearance of this condition. The presence of haemoperitoneum in both cases suggests that haemorrhage may be a common complication of splenic torsion in cats, possibly more so than in dogs, where the incidence of haemoperitoneum is also noted but may be less frequent. Further studies and case reports are necessary to draw this conclusion.

The underlying cause of splenic torsion in our patient remains unclear. In dogs, the condition is often secondary to gastric dilatation-volvulus [2], which is extremely rare in felines. One of the reasons for this might be the barrel shaped chest anatomy in felines, compared with over presented deep chested canines. The absence of neoplastic or significant inflammatory changes in the spleen suggests that primary splenic torsion, where the spleen rotates independently of other structures, might have occurred. However, the anatomical and physiological factors that predispose cats to this rare condition are not well understood. The role of immune response, splenic sinusoid architecture, and vascular differences in felines might be considered in future studies. A potential contributing factor to splenic torsion in this case is the patient's history of chronic pancreatitis. In cats, the left pancreatic lobe lies in close proximity to the splenic hilus and is most commonly affected in inflammatory pancreatic disease. Chronic pancreatitis could theoretically lead to local inflammation, fibrosis, or adhesions involving adjacent structures, potentially altering splenic mobility and predisposing to torsion. However, this association is considered unlikely in the present case. Chronic inflammatory changes would be expected to result in a more gradual or chronic alteration of splenic position, potentially allowing the development of collateral circulation. In contrast, the absence of collateral vessels and the presence of an acute haemoperitoneum support an acute torsion event, making a direct causal relationship with chronic pancreatitis less probable, although it cannot be completely excluded.

The prognosis following splenectomy for splenic torsion in dogs is generally good [11], and this seems to be true for cats as well, based on the limited data available. Despite the eventual euthanasia in this case, the initial perioperative recovery was successful. This suggests that, when diagnosed early and treated appropriately, splenic torsion in cats can be managed effectively with surgical intervention. Possible complications as postoperative infections, vascular damage to left pancreatic lobe and gastric fundus which could lead to abscess formations or

gossypiboma are possible and described in literature [12] [13] and underscore the importance of careful postoperative monitoring. The presence of a short-term mild neutropenia perioperatively may have contributed to the suspected postoperative abscess formation in this case.

4. Conclusion

This case report contributes to the understanding of splenic torsion in cats, particularly in terms of its ultrasonographic appearance. While the condition remains rare, it should be considered for the differential list in cats presented with acute abdominal pain, splenomegaly, or hemoperitoneum. The findings in this case also suggest that splenic torsion in cats may have a different pathophysiology compared to other species, warranting further investigation. Despite the unfavorable outcome in this instance, the good perioperative response indicates that splenectomy should be strongly considered as a treatment option in similar cases.

Funding

The authors received no financial support for the research, authorship, and/or publication of this article.

Data Availability Statement

The data supporting the findings of this study are available from the corresponding author upon reasonable request.

Ethical Approval

The work described in this manuscript involved the use of non-experimental (owned or unowned) animals. Established internationally recognised high standards (“best practice”) of veterinary clinical care for the individual patient were always followed and/or this work involved the use of cadavers. Ethical approval from a committee was therefore not specifically required for publication in JFMS Open Reports. Although not required, where ethical approval was still obtained it is stated in the manuscript.

Informed Consent

Informed consent (verbal or written) was obtained from the owner of the animal described in this work. No animals or people are identifiable within this publication, and therefore additional informed consent for publication was not required.

No animals or people are identifiable within this publication, and therefore additional informed consent for publication was not required.

Conflicts of Interest

The authors declare no conflicts of interest regarding the publication of this paper.

References

- [1] Bucknoff, M.C. and Rolph, K.E. (2024) Splenic Torsion in a Cat with Chronic Anemia. *Journal of Feline Medicine and Surgery Open Reports*, **10**, No. 1. <https://doi.org/10.1177/20551169231216405>
- [2] Brockman, D.J., Washabau, R.J. and Drobatz, K.J. (1995) Canine Gastric Dilatation/Volvulus Syndrome in a Veterinary Critical Care Unit: 295 Cases (1986-1992). *Journal of the American Veterinary Medical Association*, **207**, 460-464. <https://doi.org/10.2460/javma.1995.207.04.0460>
- [3] DeGroot, W., Giuffrida, M.A., Rubin, J., Runge, J.J., Zide, A., Mayhew, P.D., et al. (2016) Primary Splenic Torsion in Dogs: 102 Cases (1992-2014). *Journal of the American Veterinary Medical Association*, **248**, 661-668. <https://doi.org/10.2460/javma.248.6.661>
- [4] Ohta, H., Takagi, S., Murakami, M., Sasaki, N., Yoshikawa, M., Nakamura, K., et al. (2009) Primary Splenic Torsion in a Boston Terrier. *Journal of Veterinary Medical Science*, **71**, 1533-1535. <https://doi.org/10.1292/jvms.001533>
- [5] Penninck, D. and d'Anjou, M.A. (2015) Atlas of Small Animal Ultrasonography. 2nd Edition, Wiley-Blackwell, 239-258.
- [6] Saunders, H.M., Neath, P.J. and Brockman, D.J. (1998) B-Mode and Doppler Ultrasound Imaging of the Spleen with Canine Splenic Torsion: A Retrospective Evaluation. *Veterinary Radiology & Ultrasound*, **39**, 349-353. <https://doi.org/10.1111/j.1740-8261.1998.tb01619.x>
- [7] Mai, W. (2006) The Hilar Perivenous Hyperechoic Triangle as a Sign of Acute Splenic Torsion in Dogs. *Veterinary Radiology & Ultrasound*, **47**, 487-491. <https://doi.org/10.1111/j.1740-8261.2006.00169.x>
- [8] Hudson, J. (2020) Hemolymphatic System. In: Holland, M. and Hudson, J., Eds., *Feline Diagnostic Imaging*, Wiley, 513-515.
- [9] Hanson, J.A., Papageorges, M., Girard, E., Menard, M. and Hebert, P. (2001) Ultrasonographic Appearance of Splenic Disease in 101 Cats. *Veterinary Radiology & Ultrasound*, **42**, 441-445. <https://doi.org/10.1111/j.1740-8261.2001.tb00967.x>
- [10] Reese, S.L., Zekas, L.J., Iazbik, M.C., Lehman, A. and Couto, C.G. (2012) Effect of Sevoflurane Anesthesia and Blood Donation on the Sonographic Appearance of the Spleen in 60 Healthy Cats. *Veterinary Radiology & Ultrasound*, **54**, 168-175. <https://doi.org/10.1111/j.1740-8261.2012.01990.x>
- [11] Specchi, S. and Bertolini, G. (2020) CT Angiography Identifies Collaterals in Dogs with Splenic Vein Obstruction and Presumed Regional Splenic Vein Hypertension. *Veterinary Radiology & Ultrasound*, **61**, 636-640. <https://doi.org/10.1111/vru.12914>
- [12] Fossum, T.W. (2007) Splenic Torsion. In: *Small Animal Surgery*, 3rd Edition, Mosby Elsevier, 629-631.
- [13] Langley-Hobbs, S.J., Demetriou, J.L. and Ladlow, J.F. (2014) Feline Soft Tissue and General Surgery. Elsevier, 391.