

Penile and Scrotal Complications of Male Circumcision: A Narrative Review with Insights from Three Salvaged Complications from Traditional Circumcisions in Our Setting

Frank Obeng^{1,2*}, Aishah Fadila Adamu², Karen Michelle Anyebanying Whittal²,
Ali Mamudu Ayamba^{1,2}

¹School of Medicine, Faculty of Surgery, University of Health and Allied Sciences, Ho, Ghana

²Department of Surgery, Ho Teaching Hospital, Ho, Ghana

Email: *fobeng@uhas.edu.gh, 2017adamu@uhas.edu.gh, anyebanyingwhittal@gmail.com, aayamba@uhas.edu.gh

How to cite this paper: Obeng, F., Adamu, A.F., Whittal, K.M.A. and Ayamba, A.M. (2026) Penile and Scrotal Complications of Male Circumcision: A Narrative Review with Insights from Three Salvaged Complications from Traditional Circumcisions in Our Setting. *Open Journal of Pediatrics*, 16, 1-14.

<https://doi.org/10.4236/ojped.2026.161001>

Received: September 25, 2025

Accepted: December 28, 2025

Published: December 31, 2025

Copyright © 2026 by author(s) and Scientific Research Publishing Inc.

This work is licensed under the Creative Commons Attribution International License (CC BY 4.0).

<http://creativecommons.org/licenses/by/4.0/>



Open Access

Abstract

Background: Circumcision is one of the most common surgical procedures globally, yet complications remain prevalent in traditional practice where untrained practitioners often operate under unsafe conditions. This remains a preventable cause of penile-scrotal morbidity in children. This review uses three index cases to illustrate the wound-healing and scarring consequences of traditional circumcision in Ghana, while contextualizing them within the broader literature. **Methods:** Three pediatric cases from South-Eastern Ghana were reviewed: a 4-month-old male with penoscrotal denudation, and two boys aged two and four years with post-circumcision phimosis, meatal stenosis, and buried penis. A narrative review of 120 screened records with 24 included relevant articles was conducted (PubMed, Scopus, Cochrane, Google Scholar) to synthesize evidence on circumcision complications, reconstructive strategies, and scar-related outcomes. We then illustrated key injury patterns with the three paediatric cases managed in the study area. **Results:** Case 1 (penoscrotal denudation) was reconstructed with dartos-fasciocutaneous flaps; complete epithelial coverage by postoperative day 7. Case 2 (post-circumcision phimosis + meatal stenosis, buried penis) underwent release + meatotomy/meatoplasty; meatal calibre improved from 2 French to 8 French at 2 weeks. Case 3 (phimosis + meatal stenosis) had release + meatotomy/meatoplasty; peak urinary stream increased from “pin-hole” to a continuous stream with post-void residual 0 mL at 2 weeks. Across the literature, common complications included infection, haemorrhage, penile skin loss, urethral fistula, phimosis, and meatal stenosis; timely salvage using local flaps and meatotomy/meatoplasty yielded

favourable outcomes. **Conclusions:** Training and oversight for traditional circumcisers, aseptic technique, and early referral reduce morbidity. Reconstruction using dartos-fasciocutaneous flaps and meatotomy/meatoplasty are effective salvage options in resource-limited settings.

Keywords

Circumcision, Traditional Circumcision, Penile Complications, Scrotal Injuries, Scar Outcomes, Pediatric Urology, Reconstructive Surgery

1. Introduction

Circumcision is a widespread surgical procedure performed for cultural, religious, and medical reasons, with an estimated one-third of males globally undergoing circumcision [1] [2]. While medical circumcision is generally safe, complications arise when performed by untrained traditional circumcisers who often lack the necessary anatomical knowledge, sterilization practices, and access to proper medical facilities [1] [2].

In sub-Saharan Africa, traditional circumcision remains prevalent due to deep-rooted cultural and religious practices. However, this approach is associated with significant risks, including infections, hemorrhage, urethral fistulae, penile and scrotal tissue loss, and even mortality. Studies in Nigeria and Kenya by Magoha (1999) and Peltzer & Kanta (2009) have documented higher rates of complications in traditional circumcision compared to those conducted in formal medical settings [1] [2].

This narrative review examines penile and scrotal complications related to circumcision. Drawing insights from three cases: (an index case of penoscrotal denudation [3] and two other cases of post-circumcision phimosis and buried penile shaft) and existing literature, it underscores the critical need for bridging the gap between traditional and medical practices to improve patient outcomes.

The index cases that provide the context for this narrative review illustrate the devastating consequences of such practices. A 4-month-old male presented with extensive penile and scrotal tissue loss following circumcision by a traditional herbalist [3]. The two other cases had post-circumcision phimosis and buried penile shaft. This narrative review builds on the experience of the index cases to explore the broader implications of traditional circumcision practices, their associated risks, and effective management strategies.

The gap between traditional and medical practices highlights the need for regulated training and supervision to reduce complications. Additionally, while medical circumcision techniques such as the dorsal slit and sleeve resection have proven effective in minimizing adverse outcomes [4]-[6], the lack of accessible medical facilities in rural and resource-constrained settings continues to push communities toward traditional methods.

2. Methods

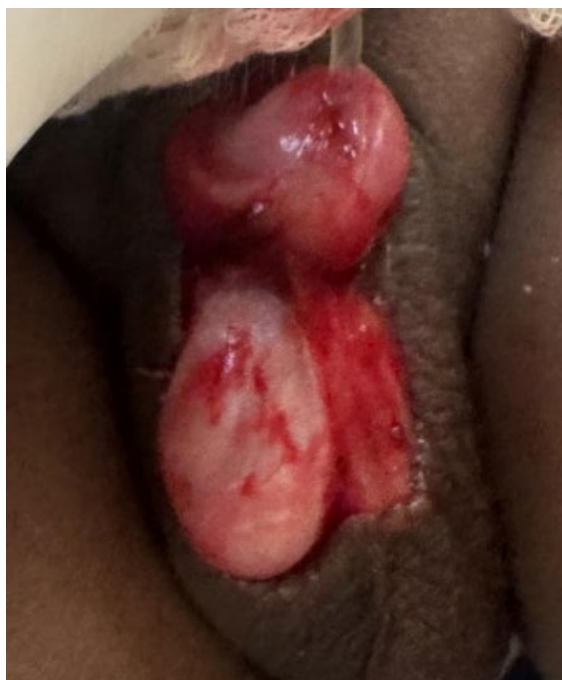A search in peer reviewed databases (Google Scholar, PubMed, Cochrane Library and Scopus) was done using the keywords, Traditional Circumcision, Penile and Scrotal Injuries, Trapped Penis, Meatotomy-meatoplasty, Dartos Flaps, Circumcision Complications, Herbal Circumcisers. Pertinent literature on the subject matter was reviewed within the delimited context of Penile and Scrotal Complications of Male Circumcision, and the index cases in this narrative review.

Ethics and consent: This work conformed to the Declaration of Helsinki and local policy. The submission reports anonymized case descriptions and non-identifiable images. Written parental/guardian consent for publication—including clinical photographs—was prospectively obtained for all three children, with consent forms on file. No patient received experimental therapy; management followed standard of care.

3. Case Context and Literature Review

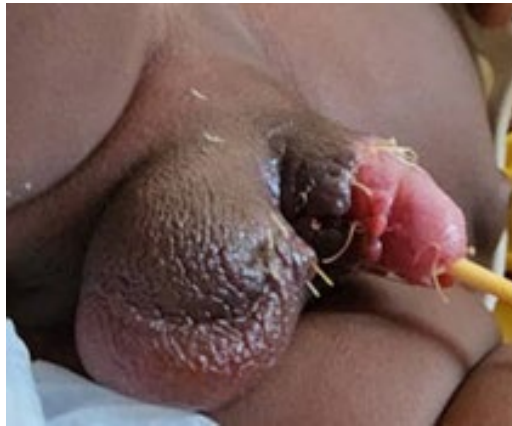3.1. Case Reports

Case 1 (4-month-old, penoscrotal denudation): Traumatic skin loss after traditional circumcision [3]. Emergency wound toileting/debridement and dartos-fasciocutaneous flap coverage achieved complete epithelialisation by post-op day 7; normal voiding and penile tumescence at 6-week review (**Figure 1** shows pre-operative appearance and **Figure 2** shows post-operative outcome).



Source: Image taken personally by authors in Theatre in June 2024.

Figure 1. This pictograph shows a deep scrotal laceration involving both hemi-scrota with both testicles and coverings exposed (Penoscrotal denudation).

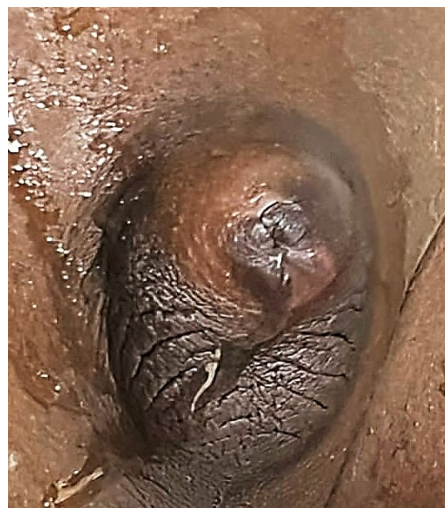


Source: Image taken personally by authors in Theatre in June 2024.

Figure 2. Preliminary results; 5 days after the primary closure in theatre, epithelialization was excellent at this time, and was optimal by 7 days post-operative.

3.2. Case 2 and Case 3

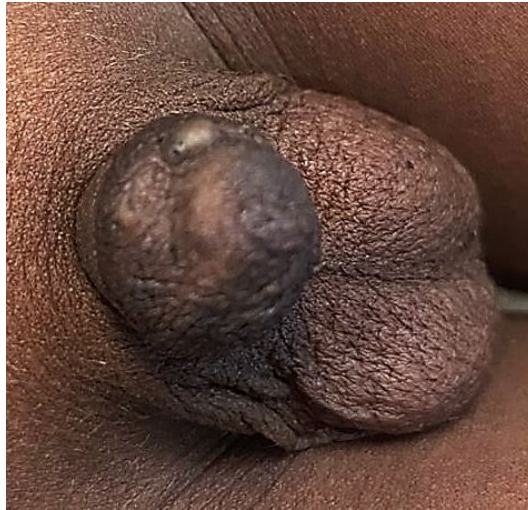Case 2 (2-year-old circumcised by a traditional circumciser at a home setting without anesthesia or aseptic technique): Patient presented with post-circumcision phimosis, meatal stenosis, buried/inconspicuous penis; ultrasound showed no hydronephrosis. Surgical release, plus meatotomy/meatoplasty restored voiding; meatal calibre improving from 2 to 8 French at 2 weeks. Parents reported normal nocturnal penile tumescence by six weeks post-operative period. (**Figure 3**: pre-operative appearance; **Figure 4**: post-operative result).



Source: Image taken personally by authors in september 2024.

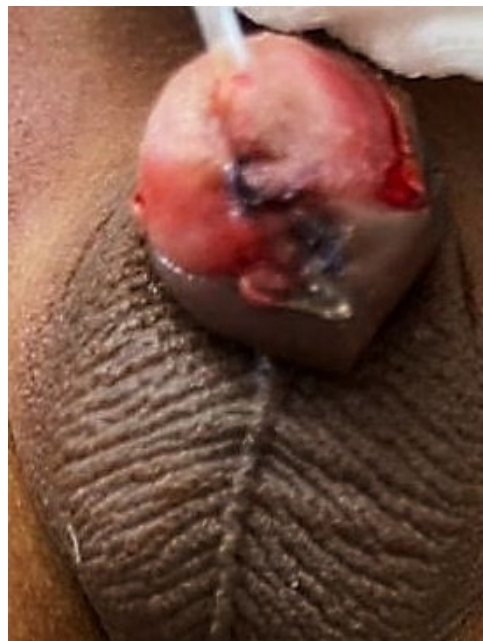
Figure 3. Post circumcision phimosis and meatal stenosis with a buried penis/penile entrapment in a two-year-old Boy after circumcision by a traditional circumciser. Some wetness from a urine spurt can be observed over the skin of the perineum on the patient's right side. This came from a forced urine jet that spurted as the patient strained to urinate (through the pin-hole meatus) during gentle physical examination. The bladder was not distended on physical examination. There was no bladder distention or hydronephrosis on ultrasound.

Case 3 (4-year-old, also circumcised by a traditional circumciser at a home setting without anesthesia or aseptic technique): He had post-circumcision phimosis with meatal stenosis also managed by surgical release, plus meatotomy/meatoplasty. The initial pin hole meatus with pencil shaped urine spurts on straining (at presentation) improved to a continuous urinary stream and a post-void residual urine of zero mL at 2 weeks post-operatively (**Figure 5**).



Source: Image taken personally by authors in September 2024.

Figure 4. Post circumcision phimosis and meatal stenosis in a four-year old boy after circumcision by a traditional circumciser.



Source: Image taken personally by authors in September 2024.

Figure 5. Post-operative appearance for both cases after salvage surgeries involving a release of phimosis and buried penis, followed by meatotomy and meatoplasty.

4. Literature Review, Circumcision Practices

4.1. Traditional Circumcision Practices

Traditional circumcision is deeply rooted in cultural and religious practices but is often conducted without medical supervision. Studies by Magoha (1999) and Peltzer and Kanta (2009) demonstrated higher complication rates in traditional settings due to the absence of sterilized tools, insufficient anatomical knowledge, and limited capacity to manage emergencies [1] [2].

4.2. Medical Circumcision Techniques

Table 1. Literature review [1] [2] [4]-[10].

Subtitle, study and year	Main findings
Traditional circumcision Magoha <i>et al.</i> (1999) Peltzer <i>et al.</i> (2009)	- Traditional circumcisers (wanzams) often perform circumcision without proper training or sterilization, leading to increased risks of infections, haemorrhage, and injury. - Cultural rituals sometimes conflict with medical standards.
Medical methods of circumcision vakalopoulos <i>et al.</i> (2015)	- Medical techniques are more controlled and reduce the risk of complications. - Techniques include dorsal slit, sleeve resection, and device-assisted methods, each with specific benefits and complications based on patient factors.
Dorsal slit technique Barone <i>et al.</i> (2012)	- Dorsal slit is effective for older children and adults. - Provides better visibility and control during the procedure but requires careful haemostasis to avoid complications.
Sleeve resection technique Barone <i>et al.</i> (2012)	- Common in paediatric circumcision. - Produces a neat cosmetic result, though care is needed to ensure correct sizing and avoid complications.
Guillotine technique Barone <i>et al.</i> (2012)	- Often used in neonatal circumcision. - Carries a higher risk of complications like glanular injury if not performed correctly.
Gomco clamp sorokan <i>et al.</i> (2015)	- Effective at minimizing bleeding and widely used. - Requires expertise to avoid complications like glanular injury or improper fit.
Plastibell device sorokan <i>et al.</i> (2015)	- Common for neonatal circumcisions due to simplicity and lower complication rates. - The ring naturally falls off after 5 to 7 days.
Mogen clamp bailey <i>et al.</i> (2007)	- A quick and bloodless method of circumcision. - Requires precision to avoid injury to the glans.
Shang ring kraft <i>et al.</i> (2016);	- Low complication rates in adult and adolescent circumcisions. - Preferred in some regions due to ease of use and effectiveness.
PrePex device WHO (2009)	- Non-surgical, using elastic bands to induce ischemic necrosis. - Primarily used in adult males for human immune-deficiency virus (HIV) prevention programs with minimal complications.
Complications in non-medical circumcision Tirana <i>et al.</i> (2022)	- Complications include infections, haemorrhage, penile injuries, and urethral fistulae. - Traditional circumcisers lack the necessary aseptic techniques and skills to manage emergencies. - Cases illustrate complications from untrained circumcisers.
Index cases	- Scrotum adaptability in local flap usage helped salvage the procedure despite complications. Meatotomy and meatoplasty was adequate salvage for post-circumcision phimoses with meatal stenoses.

Medical circumcision techniques have been shown to significantly reduce com-

plications. Vakalopoulos *et al.* (2015) highlighted, that techniques such as the dorsal slit and sleeve resection allow for better control, visibility, and reduced risk of tissue damage [4]. Barone *et al.* (2012) further emphasized that device-assisted methods, such as the Gomco clamp and Plastibell device, provide consistent outcomes with minimal complications when used appropriately [5].

As summarized in **Table 1**, Medical methods of circumcision include a dorsal slit, sleeve resection, guillotine, Gomco clamp, Plastibell, Mogen clamp, Shang Ring, and PrePex device, each with specific benefits and risks [1] [2] [4] [7]-[10].

5. Discussion

5.1. Overview of Complications

Circumcision, while considered a simple and routine procedure, is not without risks, especially when performed by untrained traditional practitioners. Complications associated with male circumcision are diverse and range from minor issues, such as mild bleeding and infections, to severe outcomes, including penile and scrotal tissue loss, urethral fistulae, and glans amputations, post circumcision phimosis, buried penis, meatal stenosis [1] [2]. The severity of these complications is often amplified in non-medical settings due to inadequate sterilization techniques, lack of anatomical knowledge, and absence of emergency preparedness [1] [2].

Table 2. Overview of complications of circumcision [1] [2] [4] [6].

Complication	Incidence (%)	Common causes
Infections	2 - 10	Poor aseptic techniques
Hemorrhage	0.8 - 3	Lack of or failure of hemostasis. Hemophilia and other bleeding diathesis.
Urethral fistula	0.1 - 0.5	Improper handling of instruments, wrong suture size during frenula artery hemostasis.
Glans amputation	<0.1	Inappropriate use of clamps or tools
Skin bridges	Variable	Inadequate postoperative care; poor technique

Table 3. Scrotal skin complications [5] [7]-[10].

Study	Author (s)	Year	Main findings	Management	Outcomes
Scrotal injuries during neonatal circumcision	Bar-Yosef, Y. <i>et al.</i>	2019	12 out of 489 circumcision-related injuries involved the scrotum (2.5%) during neonatal circumcisions. Superficial injuries.	Suture closure in emergency department or operating room exploration with general anesthesia.	No long-term damage expected; rare injuries; half required anesthesia.
Repair of total penile skin loss using scrotal flap	Sultan Qaid <i>et al.</i>	2022	A 45-day-old infant sustained total penile skin loss due to ritual circumcision by an untrained practitioner.	The small remnant Penile skin was released, and the defect repaired with a single-step scrotal flap advancement.	Functionally and cosmetically satisfying outcome at 6-month follow-up.

Table 4. Penile skin complications [11]-[21].

Study	Author (s)	Year	Main findings	Management	Study scope and outcomes
Extensive penile skin defects	Gao, Q. <i>et al.</i>	2019	31-year-old male suffered extensive penile skin defects due to circumcision complications.	Surgical exploration to repair the defect with skin grafts.	Full recovery expected.
Penile injury due to prolonged Plastibell retention	Bode, M. <i>et al.</i>	2009	23 cases of penile injuries caused by prolonged Plastibell ring retention, leading to skin defects and necrosis.	Surgical intervention, including wound debridement and skin grafting.	Resolution of the injury, but long-term consequences possible.
Total penile skin loss due to circumcision	Qaid, S. <i>et al.</i>	2022	A 45-day-old male infant suffered total penile skin loss during ritual circumcision.	Scrotal flap advancement for penile skin repair.	Successful repair and satisfactory functional outcome.
Glanular ischaemic necrosis post-circumcision	Aminsharifi, S. <i>et al.</i>	2012	2 cases of severe glanular ischemic necrosis following circumcision.	Surgical debridement and possible grafting of affected tissue.	Outcomes variable; potential need for further surgical intervention.
Circumcision mishaps retrospective analysis	Osifo and Oriafio	2009	6 days to 12 years-olds: Penile skin defects, infection, partial penile amputation, urethrocutaneous fistula, skin bridges.	Surgical repair and management of complications.	Improved outcomes with timely intervention.
Dorsal penile nerve block circumcision complication	Migliorini, M.	2016	Ischaemia (leading to necrosis), Pain in 24-year-old following circumcision.	Immediate surgical intervention to restore blood flow and preserve the tissue.	Risk of necrosis minimized with timely intervention.
Circumcisions in paediatric clinics	Tuncer <i>et al.</i>	2017	2062 participants studied: Scrotal injuries, infection, haemorrhage, trapped/buried/inconspicuous penis.	Surgical repair for complications, management of infections.	2 infections, 11 haemorrhages, 1 scrotal injury, 6 trapped penis incidents observed.
Herpes simplex virus infection post-circumcision	Leas, <i>et al.</i>	2013	Penile herpes simplex virus infection after Jewish oral-suction ritual circumcision in a 2.5-year-old.	Antiviral treatment, management of infection.	Successful resolution with antiviral therapy.

Table 5. Dual complications of scrotal and penile skin.

Study	Author (s)	Year	Main findings	Management	Outcomes
Circumcision mishaps with skin defects, infections, and haemorrhage	Osifo, O. <i>et al.</i>	2009	Reported complications from circumcisions include partial penile amputations, scrotal and penile skin defects, infections, haemorrhage and haemorrhage.	Surgical correction for skin defects, infections treated with antibiotics, haemorrhage controlled surgically.	Mixed outcomes depending on severity; most managed successfully with surgery.
Index case 1 (2024)	Index	2024	A 4-month-old male child suffered extensive scrotal tissue loss and near-total penile skin loss at circumcision	Immediate surgical intervention involving scrotal flap for reconstruction and closure of both penile and scrotal defects.	Rare and unique combination of both extensive scrotal tissue loss and near-total penile skin loss due to circumcision. Good functional and cosmetic results with full recovery after salvage surgery.

5.2. Penile Injuries

Penile injuries are among the most severe complications of circumcision [1]-[21].

These injuries include skin degloving, glans necrosis, and urethral damage [13]. According to Gao *et al.* (2019), penile resurfacing using flaps pedicled on the scrotal artery has been shown to be an effective reconstructive approach for managing severe skin loss [14]. Additionally, Qaid *et al.* (2022) reported successful outcomes with scrotal flap advancements for repairing extensive penile skin defects caused by ritual circumcision [13]. These techniques underscore the critical role of surgical innovation in managing post-circumcision penile injuries (Tables 2-5).

5.3. Scrotal Injuries

Scrotal injuries during circumcision, though less common, can lead to significant functional and cosmetic challenges. Bar-Yosef *et al.* (2019) highlighted the rarity of scrotal injuries during neonatal circumcision, reporting that most cases were superficial and could be managed with suture closure [12]. However, complex injuries involving multiple layers, as seen in the index case 1, require more advanced reconstructive techniques (Tables 3-5).

5.4. Index Case 1: Dual Complications

The first index case involved a 4-month-old male who presented with extensive penile skin degloving and scrotal lacerations. The complications, including the exposure of the tunica vaginalis and loss of multiple tissue layers, underscore the risks associated with untrained practitioners performing circumcisions. Immediate surgical intervention using dartos and scrotal flaps restored functionality and aesthetics, aligning with findings from Qaid *et al.* (2022), who reported similar success in reconstructive surgery for penile defects [13].

The combination of penile and scrotal injuries, as observed in this index case, represents a rare and challenging scenario. This dual presentation complicates management, as both anatomical and functional considerations must be addressed simultaneously. Surgical reconstruction using local tissue flaps, such as dartos and scrotal flaps, has proven effective in restoring form and function. This approach aligns with findings by Ignjatović *et al.* (2010), who reported successful outcomes using full-thickness skin grafts for extensive penile and scrotal defects [15].

5.5. Index Cases 2 and 3

These two other cases exemplify delayed but salvageable complications from traditional circumcision practices commonly performed without anesthesia or sterile technique in sub-Saharan Africa [1]-[3]. The presentation of post-circumcision phimosis, meatal stenosis, and buried/trapped penis—absent systemic infection or renal compromise—underscores the anatomical but non-systemic nature of such injuries [11] [20]. Surgical management with phimosis release, meatotomy, and meatoplasty yielded good outcomes, aligning with pediatric urologic reconstruction standards [6] [8] [13]. These cases reiterate the documented burden of complications linked to unskilled circumcision and support calls for policy reforms and community education to integrate safety and standardization into cul-

tural practices [2] [3] [21] [22].

5.6. Management of Penile and Scrotal Injuries

Scrotal flaps and full-thickness skin grafts are among the most effective techniques for managing extensive genital injuries. Gao *et al.* (2019) demonstrated the efficacy of scrotal artery pedicled-flaps in resurfacing penile defects, achieving favorable cosmetic and functional outcomes [14]. Bar-Yosef *et al.* (2019) also highlighted the adaptability of scrotal tissue in neonatal circumcision-related injuries, noting successful outcomes with tissue flaps and suture closures [12]. See **Tables 2-5**.

5.7. Factors Contributing to Complications

Several factors contribute to the high complication rates observed in traditional circumcision settings.

Lack of Training: Traditional practitioners often lack formal medical training, leading to improper surgical techniques and increased risk of complications [2] [5].

Inadequate Sterilization: The absence of sterilized instruments in traditional settings significantly increases the risk of infections [1].

Delayed Presentation: In many cases, patients seek medical attention only after complications have become severe, further complicating management [8]. This situation was observed in the index cases 2 and 3.

5.8. Surgical Innovations and Advances

Advancements in surgical techniques have improved outcomes for circumcision-related injuries. Scrotal flaps, as highlighted by Gao *et al.* (2019), provide a reliable and versatile option for reconstructing penile and scrotal defects [14]. Similarly, Ignjatović *et al.* (2010) demonstrated the efficacy of full-thickness skin grafts for complex cases involving extensive tissue loss [15]. These innovations emphasize the importance of skilled surgical intervention in mitigating complications.

5.9. Need for Regulatory Oversight

The World Health Organization (WHO) and other health bodies advocate for increased regulation of traditional circumcision practices. A WHO-affiliated systematic review of surgical voluntary medical male circumcision (VMMC) safety (40 studies) estimated moderate/severe adverse events at ~0.30 per 100 clients, with higher infection-related adverse events in boys aged 10 - 14 years. Rare but serious events (e.g., tetanus, glans injury) were also reported; the authors call for robust safety surveillance as programs mature [23]. In 2023, WHO issued a landscape report on sustaining safe VMMC services, re-affirming VMMC's role in combination HIV prevention while emphasizing quality, age-appropriate services, and prevention of urethrocutaneous fistulae through surgical best-practice and supervision [24]. These updates support our conclusion that training, oversight

and early referral are central to harm-reduction in settings where traditional circumcision persists.

5.10. Regulatory and Educational Interventions

The World Health Organization (WHO) advocates formal training programs for traditional practitioners to enhance their understanding of aseptic techniques and anatomy [9]. Collaborative efforts between traditional and medical practitioners can help bridge the gap in knowledge and improve outcomes [3]. Public awareness campaigns are also essential to educate communities about the risks of unregulated circumcision and encourage safer practices [1] [15]-[19].

6. Limitations

This is a narrative review anchored by a small, single-centre case series, which limits generalizability and precludes incidence estimates. Selection and publication bias are likely (severe or unusual cases are more often reported). The literature base varies in quality, with heterogeneous definitions of complications and follow-up intervals. Finally, timelines and outcomes in our three cases reflect specialist availability in a referral setting and may not be reproducible in all resource-limited contexts.

7. Conclusions

This narrative review highlights the significant risks associated with traditional circumcision practices and the effective management of penile and scrotal complications through principled salvage-surgical techniques. Recommendations targeted at the national health authorities are suggested here. The lessons and experience from the index cases, underscore the need for urgent corrective measures.

Key recommendations to the national healthcare authorities, include Providing formal training in aseptic techniques and anatomical knowledge [9]. Establishing collaborative frameworks between traditional and medical practitioners to bridge gaps in practice [3]. Conducting community awareness campaigns to educate the public about the risks associated with unregulated circumcision [1]. Through these measures, complications arising from circumcision can be minimized, ensuring better outcomes for patients.

Funding

This research received no external funding. It was entirely self-funded by the authors with in-kind institutional support from the University of Health and Allied Sciences, Ho, Ghana.

Ethics Statement

This work conformed to the Declaration of Helsinki and local policy. The submission reports anonymized case descriptions and non-identifiable images. Written parental/guardian consent for publication—including clinical photographs—

was prospectively obtained for all three children, with consent forms on file. No patient received experimental therapy; management followed standard of care.

Author Contributions

Frank Obeng (FO): Conceptualization, observation, field intervention, literature review, manuscript drafting, supervision, and final approval.

Mahamadu Ayamba Ali (MAA), Aishah Fadila Adamu (AFA), Karen Michelle Anyebanying Whittal (KMAW): Literature search, digital illustration and reconstruction, data synthesis, manuscript drafting, supervision and critical revisions.

Both authors meet the ICMJE authorship criteria, take full responsibility for the integrity of the work, and have approved the final version of the manuscript.

Conflicts of Interest

The authors declare that they have no competing interests.

References

- [1] Magoha, G.A. (1999) Circumcision in Various Nigerian and Kenyan Ethnic Groups. *Central African Journal of Medicine*, **45**, 258-262.
- [2] Peltzer, K. and Kanta, X. (2009) Medical Circumcision and Manhood Initiation Rituals in the Eastern Cape, South Africa: A Post Intervention Evaluation. *Culture, Health & Sexuality*, **11**, 83-97. <https://doi.org/10.1080/13691050802389777>
- [3] Obeng, F., Adamu, A.F., Ayamba, A.M., Whittal, K.M. and Gavor, S.E. (2024) A Near-Miss Orchidectomy Involving a Local Herbal-Circumcisionist in South-Eastern Ghana: A Case Report on a Circumcision Disaster. https://www.researchgate.net/publication/382561732_A_Near-Miss_Orchidectomy_Involving_a_Local_Herbal-Circumcisionist_in_South-Eastern_Ghana_A_Case_Report_on_a_Circumcision_Disaster
- [4] Abdulwahab-Ahmed, A. and Mungadi, I. (2013) Techniques of male circumcision. *Journal of Surgical Technique and Case Report*, **5**, 1-7. <https://doi.org/10.4103/2006-8808.118588>
- [5] Barone, M., Li, P., Lee, R., Ouma, D., Oundo, M., Barasa, M., *et al.* (2019) Simplifying the Shangring Technique for Circumcision in Boys and Men: Use of the No-Flip Technique with Randomization to Removal at 7 Days versus Spontaneous Detachment. *Asian Journal of Andrology*, **21**, 324-331. https://doi.org/10.4103/aja.aja_91_18
- [6] Sorokan, S.T., Finlay, J.C. and Jefferies, A.L. (2015) Newborn Male Circumcision. *Paediatrics & Child Health*, **20**, 311-315. <https://doi.org/10.1093/pch/20.6.311>
- [7] Bailey, R. (2008) Male Circumcision for HIV Prevention: A Prospective Study of Complications in Clinical and Traditional Settings in Bungoma, Kenya. *Bulletin of the World Health Organization*, **86**, 669-677. <https://doi.org/10.2471/blt.08.051482>
- [8] Kraft, K.H., Shukla, A.R. and Canning, D.A. (2016) Advances in Penile Trauma Reconstruction. *Journal of Indian Association of Pediatric Surgeons*, **21**, 19-23.
- [9] WHO (2009) Male Circumcision: Global Trends and Safety.
- [10] Kim, H.H., Li, P.S. and Goldstein, M. (2010) Male Circumcision: Africa and Beyond? *Current Opinion in Urology*, **20**, 515-519.

- <https://doi.org/10.1097/mou.0b013e32833f1b21>
- [11] Suwarno, B., Gumilar, O.B., Rozidi, A.R.S. and Zharfan, R.S. (2022) Urethral Injury as a Rare Complication of Circumcision: A Case Report and Literature Review. *Indonesian Journal of Urology*, **29**, 151-157. <https://doi.org/10.32421/juri.v29i2.764>
- [12] Bar-Yosef, Y., Dekalo, S., Bar-Yaakov, N., Binyamini, J., Sofer, M. and Ben-Chaim, J. (2019) Scrotal injuries during neonatal circumcision. *Journal of Pediatric Urology*, **15**, 69.e1-69.e3. <https://doi.org/10.1016/j.jpuro.2018.10.009>
- [13] Qaid, S., Ahmed, F., Al-shami, E., Alyhari, Q., Ghabisha, S., Askarpour, M.R., et al. (2022) Repair of Total Penile Skin Loss after Ritual Circumcision Using a Scrotal Flap: A Case Report. *Pan African Medical Journal*, **42**, Article 152. <https://doi.org/10.11604/pamj.2022.42.152.35813>
- [14] Gao, Q. and Qu, W. (2019) Penile Resurfacing Using a Reverse Bilateral Anterior Scrotal Artery Flap: A Case Report of Penile Skin Defects Following Circumcision. *Medicine*, **98**, e18106. <https://doi.org/10.1097/md.00000000000018106>
- [15] Ignjatovic, I., Kovacevic, P., Medojevic, N., Potic, M. and Milic, V. (2010) Reconstruction of the Penile Skin Loss Due to 'Radical' Circumcision with a Full Thickness Skin Graft. *Vojnosanitetski pregled*, **67**, 593-595. <https://doi.org/10.2298/vsp1007593i>
- [16] Rosellen, J., Pflüger, M., Bach, A., Steffens, J. and Kranz, J. (2020) Penile Paraffinome—Therapeutische Strategien. *Der Urologe*, **59**, 1371-1376. <https://doi.org/10.1007/s00120-020-01322-6>
- [17] Ben Chaim, J., Livne, P.M., Binyamini, J., Hardak, B., Ben-Meir, D. and Mor, Y. (2005) Complications of Circumcision in Israel: A One-Year Multicenter Survey. *The Israel Medical Association Journal*, **7**, 368-370. <https://pubmed.ncbi.nlm.nih.gov/15984378/>
- [18] Bickell, M., Beilan, J., Wallen, J., Wiegand, L. and Carrion, R. (2016) Advances in Surgical Reconstructive Techniques in the Management of Penile, Urethral, and Scrotal Cancer. *Urologic Clinics of North America*, **43**, 545-559. <https://doi.org/10.1016/j.ucl.2016.06.015>
- [19] Leas, B.F. and Umscheid, C.A. (2014) Neonatal Herpes Simplex Virus Type 1 Infection and Jewish Ritual Circumcision with Oral Suction: A Systematic Review. *Journal of the Pediatric Infectious Diseases Society*, **4**, 126-131. <https://doi.org/10.1093/jpids/piu075>
- [20] Iacob, S.I., Feinn, R.S. and Sardi, L. (2021) Systematic Review of Complications Arising from Male Circumcision. *BJUI Compass*, **3**, 99-123. <https://doi.org/10.1002/bco2.123>
- [21] Osifo, O. and Oriaifo, I. (2009) Circumcision Mishaps in Nigerian Children. *Annals of African Medicine*, **8**, 266-270. <https://doi.org/10.4103/1596-3519.59583>
- [22] Zhehau, Q. and Zichire, D. (2024) A Near-Miss Unintended Orchidectomy Involving a Local Herbal Circumcisionist in South Eastern Ghana: A Case Report on a Circumcision Disaster. *Archives of Clinical and Experimental Surgery*, **13**, 1-4.
- [23] Jindai, K., Farley, T., Awori, Q., Temu, A., Ndenzako, F. and Samuelson, J. (2023) Systematic Review: Safety of Surgical Male Circumcision in Context of HIV Prevention Public Health Programmes. *Gates Open Research*, **6**, Article 164. <https://doi.org/10.12688/gatesopenres.13730.2>
- [24] World Health Organization (2023) Assessing and Enhancing Sustainable Voluntary Medical Male Circumcision Services for HIV Prevention in East and Southern Africa: A Land-Scape Report of Voluntary Medical Male Circumcision Priority Countries.

WHO.

<https://www.who.int/teams/global-hiv-hepatitis-and-stis-programmes/hiv/prevention/voluntary-medical-male-circumcision>