

# Management of Acute Intestinal Intussusception in Infants and Children at the Nianankoro Fomba Hospital in Segou

Oumar Sountie Coulibaly<sup>1</sup>, Moussa Dembélé<sup>1\*</sup>, Aminata Fofana<sup>2</sup>, Bagouma Traoré<sup>3</sup>, Abdoulaye Traoré<sup>3</sup>, Yacaria Coulibaly<sup>4</sup>

<sup>1</sup>Pediatric Surgery Department, Nianankoro Fomba Hospital, Ségou, Mali

<sup>2</sup>Otorhinolaryngology Department, Bamako District Hospital, Bamako, Mali

<sup>3</sup>Intensive Care Anesthesia Department, Nianankoro Fomba Hospital, Ségou, Mali

<sup>4</sup>Pediatric Surgery Department, Gabriel Touré University Hospital, Bamako, Mali

Email: \*dmbmoussa@gmail.com

**How to cite this paper:** Coulibaly, O.S., Dembélé, M., Fofana, A., Traoré, B., Traoré, A., Coulibaly, Y. (2025) Management of Acute Intestinal Intussusception in Infants and Children at the Nianankoro Fomba Hospital in Segou. *Open Journal of Pediatrics*, 15, 338-347.

<https://doi.org/10.4236/ojped.2025.153032>

**Received:** April 25, 2025

**Accepted:** May 18, 2025

**Published:** May 21, 2025

Copyright © 2025 by author(s) and Scientific Research Publishing Inc. This work is licensed under the Creative Commons Attribution International License (CC BY 4.0).

<http://creativecommons.org/licenses/by/4.0/>



Open Access

## Abstract

**Introduction:** Acute intestinal intussusception is a medical-surgical emergency. It is the main etiology of intestinal obstructions in infants. Its diagnosis is essentially clinical in its typical form with ultrasound confirmation. Care still remains problematic in developing countries where delay in care impacts morbidity and mortality. Our work aims to evaluate the epidemiological, clinical, diagnostic and therapeutic aspects of acute intestinal intussusception. **Materials and Method:** It was a 3-year retrospective and descriptive study from January 1, 2022 to December 31, 2024, including patients aged 0 to 15 years operated on for acute intestinal intussusception in the pediatric surgery department at Nianankoro Fomba Hospital in Segou. **Results:** We recorded 40 cases, representing an annual frequency of 13.3 cases. The average age was 2 years 5 months. There was a male predominance (24 cases). The sex ratio was 1.5. The average consultation time was 3.2 days. Thirty percent (30%) of patients had an altered general condition. The functional signs were dominated by vomiting (87%), paroxysmal cries (62.5%), and rectal bleeding (52.5%). The classic triad was present in 40% of cases. The intussusception sausage was palpable at 57.5% and prolapsed through the anus at 7.5%. Abdominal ultrasound was performed in 72.5% of cases. The treatment was surgical for all patients. The ileo-colic form (ileo-caeco-colic and transvalvular ileo-colic) represented 75% of cases. Manual desinvagination was performed in 65%, and resection-anastomosis in 35%. Postoperative complications were the abscess of the surgical site in 3 cases, including a case of recurrence of intussusception on day 6, then an eventration at 1 month. The average length of hospitalization was 6.6 days. **Conclusion:**

The management of acute intestinal intussusception remains a challenge in our context. Improving your prognosis requires early diagnosis and treatment.

## Keywords

Acute Intestinal Intussusception, Infant and Child, Medical-Surgical Emergency, Diagnosis, Treatment

---

## 1. Introduction

Acute intestinal intussusception is the penetration of one intestinal segment into the adjacent segment. It is a medical-surgical emergency, and the most common cause of intestinal obstruction in infants and children under 2 years of age [1]. All age groups can be affected [2]. The incidence is estimated to be between 20 and 100 cases per 100,000 births [3] [4]. The clinical diagnosis is considered in front of the classic triad (abdominal pain or paroxysmal cries, vomiting and rectal bleeding), but these symptoms are often inconstant with a misleading clinical picture in some cases [5] [6]. Abdominal ultrasound confirms the diagnosis by showing the intussusception tube [7]-[10]. The prognosis depends on the early diagnosis and treatment. Pneumatic or enema reduction is indicated as the first intention in the absence of contraindication and gives good results [6] [11] [12]. Surgical treatment remains relevant in countries with limited resources, where the technical capacity is insufficient, and where patients are faced with late diagnosis [13]. In the absence of a specific study on the subject in our locality, we set ourselves the objective: to evaluate the epidemiological aspects, the clinical and evolutionary profile of acute intestinal intussusceptions managed in the pediatric surgery department at the Nianankoro Fomba hospital in Segou.

## 2. Materials and Method

It was a retrospective and descriptive study over 3 years from January 1, 2022 to December 31, 2024 performed in the pediatric surgery department at Nianankoro Fomba Hospital in Ségou. We included all patients aged 0 to 15 years operated exclusively for acute intestinal intussusception. Patients operated on in another structure were not included in our study. Data was collected from medical records, consultations and operative registers. The variables studied were sociodemographic parameters (age, sex, residence, notion of referral/evacuation), clinical characteristics (general condition, vomiting, abdominal pain, rectal bleeding, paroxysmal cries, palpation of the sausage, prolapse of the sausage), the type of intussusception, the therapeutic aspects (the approach, the surgical procedure, the associated procedures) and the outcome. Data entry and analysis were done with IBM SPSS version 26.

## 3. Results

The annual frequency of intussusception was 13.33 cases. The average age was 2

years 5 months with extremes of 2 months and 15 years. The median age was 11 months (**Table 1**).

**Table 1.** Distribution of patients according to demographic data.

Demographic data	Percentage	
	Number of cases	
Age group		
1 month - 2 years	30	75%
>2 years	10	25%
Sex		
Male	24	60%
Female	16	40%
Residence		
City of Segou	28	70%
Other cities	12	30%

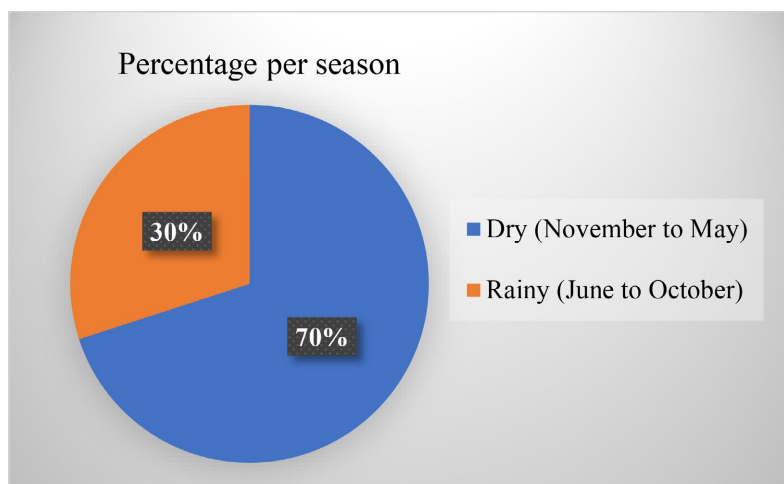
The age group of 1 month to 2 years was represented in 75% of cases (30 cases).

The male gender was predominant (24 cases) with a sex ratio of 1.5.

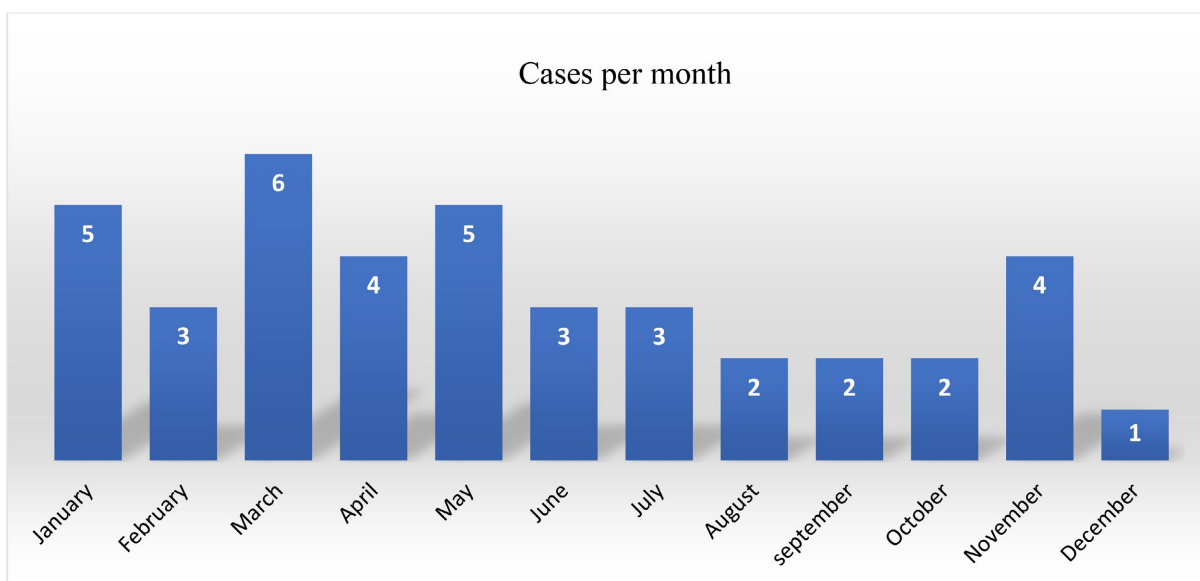
The majority of patients were from the city of Segou via the emergency room, representing 70% of cases. Referrals/evacuations involved 12 patients, representing 30% of cases (**Figure 1**).

Twenty-eight (28) patients, 70% of cases, consulted during the dry season (**Figure 1**).

We recorded the highest number in March (6 cases) followed by January (5 cases) and May (5 cases). The majority of patients were admitted via the emergency room, 70% of cases. The referrals/evacuations concerned 12 patients or 30% of cases (**Table 2**).



**Figure 1.** Distribution of patients according to the season of the year.



**Figure 2.** Distribution of patients according to the number of cases per month.

**Table 2.** Distribution of patients according to the medical consultation deadline.

Consultation deadline	Number of cases	Percentage
<24 hours	2	5%
24 - 48 hours	16	40%
>48 hours	22	55%
Total	40	100%

Thirty-eight (38) patients consulted more than 24 hours after the symptoms, representing 95% of cases. The average time between the symptoms and the consultation was 3.2 days with extremes of 1 and 6 days (**Table 3**).

**Table 3.** Distribution of patients according to clinical signs.

	Clinical signs	
	Number of cases	Percentage
General condition		
Fair	28	70%
Altered	12	30%
Functional signs		
Classic triad	16	40%
Paroxysmal cries	25	62.5%
Addominal pain	10	25%
Vomiting	35	87.5%
Rectal bleeding	21	52.5%

**Continued**

Physical signs		
Palpable sausage	23	57.5%
Abdominal distension	6	15%
Abdominal defense	6	15%
Rectal prolapse	3	7.5%
Non-specific	2	5%

Twenty-eight (28) patients, in 70% of cases, had a preserved general condition. Classic Ombredane triad (paroxysmal cries + vomiting + rectal bleeding) was present in 16 patients, in 40% of cases. Vomiting was the most frequent functional sign, in 87.5% of cases. The intussusception sausage was palpable in 23 patients, 57.5% of cases. The intussusception sausage was prolapsed in 3 patients, in 7.5% of cases.

Radiological examinations were requested in 34 patients, in 85% of cases. Abdominal ultrasound showed intussusception in 100% of cases, in the 29 patients (72.5%) who performed this examination.

All our patients were treated surgically. The approaches used were the supra-umbilical transverse in 38 cases (95%) and the median in 2 cases (5%) (**Table 4**).

**Table 4.** Distribution of patients according to surgical procedure and type of intussusception.

Type \ Procedure	Manual desinvagination	Manual desinvagination + Principle appendicectomy	Resection-anastomosis	Total
Ileo-ileal	3	0	3	6
Ileo-colic	0	19	11	30
Colo-colic	3	0	0	3
Double(ileo-ileo-colic)	0	1	0	1
Total	6	20	14	40

The intussusception was ileocolic in 75% of cases. A double intussusception (ileo-ileocolic) was noted in one patient. The procedures performed were manual desinvagination in 26 cases (65%), and resection-anastomosis in 14 cases (35%). The procedure associated with desinvagination was appendectomy in 20 cases (**Table 5**).

**Table 5.** Distribution of patients according to type of intussusception and age group.

Age group \ Type	Ileo-ileal	Ileo-colic	Colo-colic	Double (ileo-ileo-colic)	Total (n = 40)
Infant (1 mois - 2 ans)	3	26	0	1	30
Children (>2 ans)	3	4	3	0	10
Total (n = 40)	6	30	3	1	40

$\text{Khi}^2 = 13.5, p = 0.004.$

Ileocolic intussusception was represented in 30 cases, 75%. The ileocolic type affected infants in 26 cases and children in 4 cases. This rate corresponds to 86.6% in infants. There is a statistically significant association between age group and type of intussusception.

The procedure associated with manual desinvagination was the appendectomy in 20 cases.

The postoperative course was simple in 37 cases (92.5%). Postoperative complications affected 3 patients (7.5%). It was a surgical site infection. Among these 3 patients, one patient had a recurrence (ileo-ileal intussusception) on postoperative day 6, then an abdominal eventration at 1 month. The average length of hospitalization was 6.6 days with extremes of 4 and 15 days.

#### 4. Discussion

The annual frequency of acute intestinal intussusception varies according to geographic regions. Our frequency of 13.3 cases/year is similar to the sub-Saharan series [14] [15], but higher compared to the North African series [16]. Acute intestinal intussusception occurs before the age of 1 year in more than 60% of cases, with a high rate between 3 months and 8 months [17]. The median age is around 9 to 10 months [3]. The median age in our study was 11 months. The peak zone is between 3 months and 2 years [18]. Our age group of 1 month to 2 years represented 75% of cases. Male gender is generally associated with the occurrence of acute intestinal intussusception [4] [17] [19]. We made the same observation; the sex ratio was 1.5 in our study. The occurrence of acute intestinal intussusception following viral infections is reported in the literature [1] [18] [20]. Its seasonal nature is disputed [21] [22], however, a viral origin is correlated with its occurrence [18] [20]. In our study, we observed a peak in frequency during the dry season (November to May). This could be explained by the relatively long duration of the dry season (7 months) and especially the increase in viral infections during this period in a tropical environment. Delays in consultation still remain a challenge in African countries, with an average diagnosis time greater than 48 hours [13] [14] [23]. Our average consultation time was 3.2 days, of which 95% of patients consulted after 24 hours of progress. This delay could be explained by the use of traditional treatment and the distance from health structures. The symptoms of acute intestinal intussusception are diverse and varied; there are atypical presentations where the abdominal symptoms are secondary and the diagnosis is sometimes more difficult and delayed [24]. The classic Ombredane triad of abdominal pain or paroxysmal cries, vomiting and rectal bleeding has a positive predictive value of 93% [5], but it only concerns 7.5% to 40% of patients [6] [25]. This classic triad is often the prerogative of acute intestinal intussusceptions in infants. In our study, it was present in 40% of cases and it only concerned infants. The intussusception tube is most often palpated in the right hypochondrium or in the epigastric region; it is found in 70% of cases of ileocecal intussusception [26]. The sausage was palpated in 57.5% of cases in our study. Acute intestinal intussusception

prolapsed through the anus due to anatomical factors, notably a lack of adjoining of the colon and a long mesentery [27] [28]. These anatomical factors are correlated with a diagnostic delay in African and Indian series where the prevalence varies from 5% to 40% depending on the study [29]-[31]. The sausage was prolapsed in 3 patients (7.5%) in our series. This rate could be explained by a delay in consultation of at least 72 hours in the 3 patients. Plain abdominal radiography (ASP) is no longer recommended for the diagnosis of acute intussusception [32]. It is mainly used to look for signs of complications, in particular pneumoperitoneum and hydro-aerial levels, which are respectively in favor of digestive perforation and intestinal obstruction. We performed radiography on 5 patients (12.5%) who presented with abdominal distension. He objectified hydro-aerial levels, in favor of intestinal obstruction. Radiological diagnosis is essentially based on abdominal ultrasound which has a sensitivity of around 100% and a specificity of 88 to 100% [5] [8]-[10]. High-frequency ultrasound is absolutely diagnostically reliable. The characteristic appearance of intussusception is visible in cross-section and longitudinal section [7] [33]. Abdominal ultrasound was requested in 72.5% of cases in our study. She objectified the image as a cockade and a sandwich in all cases. Non-surgical treatment (pneumatic or enema reduction) has shown its effectiveness in the management of acute ileocolic intussusceptions with a success rate of around 89% for pneumatic reduction and 72% for enema reduction [6] [11] [12]. Non-surgical treatment is carried out as first intention in the absence of contraindication [34], putting surgical treatment in the background. Surgical treatment is indicated in case of failure or contraindication of the enema [34]. However, surgical treatment remains the only alternative in our context where the technical platform is insufficient (little infrastructure and personnel), the teams are not trained in non-surgical reduction and there are delays in consultations [13]-[15]. All our patients were treated surgically. We performed a transverse approach above the umbilical in 95% of cases and a median in 5% of cases. This could be explained by our preference for the transverse approach which causes fewer complications (scary, post-operative pain) in infants and small children. The anatomical ileo-colic form of acute intestinal intussusception accounts for 80 to 90%, the ileo-ileal from 5% to 8%, the colocolic form 2% and the ileo-ileocolic form 10% [35] [36]. In our study, the ileocolic form represented 75% of all cases and 87% of intussusceptions in infants. In our study, the ileocolic form represented 75% of all cases and 87% of intussusceptions in infants. The ileo-ileal form was represented in 15% of cases, the colocolic form in 7.5% and the ileo-ileo-colic form in 2.5%. Our results are similar to the literature data with regard to the ileocecal form but different in the other forms. This could be explained by the small sample size and the high number of older children in our study. Delay in diagnosis and treatment causes a high rate of morbidity and mortality in poor countries [13] [22] [36]. We performed manual desinvagination in 26 cases (65%) and intestinal resection, followed by end-to-end anastomosis in 14 cases (35%). This high rate of intestinal resection could be explained by the overall delay in treatment. The complications

inherent to open surgery constitute a morbidity independent of the diagnosis of intussusception. These complications are of the order of 1%, including complications of anesthesia, wall abscesses, and flange occlusion [37]. In our study, we recorded 3 cases of wall abscess, including in one case a recurrence of postoperative intestinal intussusception and an abdominal eventration. The duration of hospitalization varies depending on the nature of the treatment (surgical or not). Acute intestinal intussusceptions reduced non-surgically require an average of 2 days of hospitalization, with surgical reductions being up to 10 days of hospitalization in some studies [17] [23]. Our average length of hospitalization of 6.6 days could be explained by the fact that all our patients were treated surgically.

## 5. Conclusion

The management of acute intestinal intussusception still remains a challenge in African countries. The low socio-economic level, the lack of knowledge of the disease and the use of traditional treatment are the main causes of the delay in diagnosis and management of acute intestinal intussusception. Improving the prognosis of acute intestinal intussusception in our context will involve raising awareness among the population, training medical personnel, and improving the technical platform in our health structures.

## Conflicts of Interest

The authors declare no conflicts of interest regarding the publication of this paper.

## References

- [1] Bines, J.E., Ivanoff, B., Justice, F. and Mulholland, K. (2004) Clinical Case Definition for the Diagnosis of Acute Intussusception. *Journal of Pediatric Gastroenterology and Nutrition*, **39**, 511-518. <https://doi.org/10.1002/j.1536-4801.2004.tb00900.x>
- [2] Ondhia, M.N., Al-Mutawa, Y., Harave, S. and Losty, P.D. (2020) Intussusception: A 14-Year Experience at a UK Tertiary Referral Centre. *Journal of Pediatric Surgery*, **55**, 1570-1573. <https://doi.org/10.1016/j.jpedsurg.2019.07.022>
- [3] Stringer, M.D., Pablot, S.M. and Brereton, R.J. (1992) Paediatric Intussusception. *Journal of British Surgery*, **79**, 867-876. <https://doi.org/10.1002/bjs.1800790906>
- [4] Buettcher, M., Baer, G., Bonhoeffer, J., Schaad, U.B. and Heininger, U. (2007) Three-year Surveillance of Intussusception in Children in Switzerland. *Pediatrics*, **120**, 473-480. <https://doi.org/10.1542/peds.2007-0035>
- [5] Harrington, L., Connolly, B., Hu, X., Wesson, D.E., Babyn, P. and Schuh, S. (1998) Ultrasonographic and Clinical Predictors of Intussusception. *The Journal of Pediatrics*, **132**, 836-839. [https://doi.org/10.1016/s0022-3476\(98\)70314-2](https://doi.org/10.1016/s0022-3476(98)70314-2)
- [6] Jenke, A.C., Klaafßen-Mielke, R., Zilbauer, M., Heininger, U., Trampisch, H. and Wirth, S. (2011) Intussusception: Incidence and Treatment—Insights from the Nationwide German Surveillance. *Journal of Pediatric Gastroenterology and Nutrition*, **52**, 446-451. <https://doi.org/10.1097/mpg.0b013e31820e1bec>
- [7] Pracros, J.P., Louis, D., Tran-Minh, V.A., *et al.* (1989) *Invagination Intestinale aigüe du nourrisson et de l'enfant*. Elsevier.
- [8] Daneman, A. and Navarro, O. (2003) Intussusception: Part 1: A Review of Diagnostic

- Approaches. *Pediatric Radiology*, **33**, 79-85.  
<https://doi.org/10.1007/s00247-002-0832-2>
- [9] Hryhorczuk, A.L. and Strouse, P.J. (2009) Validation of US as a First-Line Diagnostic Test for Assessment of Pediatric Ileocolic Intussusception. *Pediatric Radiology*, **39**, 1075-1079. <https://doi.org/10.1007/s00247-009-1353-z>
- [10] Bucher, B.T., Hall, B.L., Warner, B.W. and Keller, M.S. (2011) Intussusception in Children: Cost-Effectiveness of Ultrasound vs Diagnostic Contrast Enema. *Journal of Pediatric Surgery*, **46**, 1099-1105. <https://doi.org/10.1016/j.jpedsurg.2011.03.034>
- [11] Sargent, M.A., Babyn, P. and Alton, D.J. (1994) Plain Abdominal Radiography in Suspected Intussusception: A Reassessment. *Pediatric Radiology*, **24**, 17-20. <https://doi.org/10.1007/bf02017652>
- [12] Kaiser, A.D., Applegate, K.E. and Ladd, A.P. (2007) Current Success in the Treatment of Intussusception in Children. *Surgery*, **142**, 469-477. <https://doi.org/10.1016/j.surg.2007.07.015>
- [13] Mouafo Tambo, F.F. and Andze, O.G. (2009) Les invaginations intestinales aiguës du nourrisson et de l'enfant en milieu africain: Intérêt d'un diagnostic précoce. *Mali Medical*, **24**, 46-49.
- [14] Rakotoarisoa, B., Rabarijaona, M. and Zafit, A. (2001) Invagination intestinale aiguë du nourrisson à propos de 22 cas traités chirurgicalement dans le service de chirurgie pédiatrique au CHU d'Antananarivo. *Médecine d'Afrique Noire*, **48**, 358-362.
- [15] Amadou, I. (2003) Invagination intestinale aiguë de l'enfant à propos de 65 cas traités chirurgicalement dans les services de chirurgie générale et pédiatrique du CHU Gabriel Toure. Université des Sciences, des Techniques et des Technologies de Bamako.
- [16] Benmansour, O. (2009) Invagination intestinale aiguë chez l'enfant et le nourrisson à l'hôpital provincial de Tanger. Thèse de Médecine, Université Mohammed 5 de Rabat.
- [17] de Lamber, G., Guérin, F., Franchi-Abella, S., Boubnova, J. and Martelli, H. (2015) Invagination intestinale aiguë du nourrisson et de l'enfant. *Journal de Pédiatrie et de Puériculture*, **28**, 118-130. <https://doi.org/10.1016/j.jpp.2015.04.001>
- [18] Khen-Dunlop, N. (2020) L'invagination intestinale aiguë. *Journal de Pédiatrie et de Puériculture*, **33**, 221-227. <https://doi.org/10.1016/j.jpp.2020.06.006>
- [19] Weihmiller, S.N., Monuteaux, M.C. and Bachur, R.G. (2012) Ability of Pediatric Physicians to Judge the Likelihood of Intussusception. *Pediatric Emergency Care*, **28**, 136-140. <https://doi.org/10.1097/pec.0b013e3182442db1>
- [20] Porter, H.J., Padfield, C.J., Peres, L.C., Hirschowitz, L. and Berry, P.J. (1993) Adenovirus and Intranuclear Inclusions in Appendices in Intussusception. *Journal of Clinical Pathology*, **46**, 154-158. <https://doi.org/10.1136/jcp.46.2.154>
- [21] Serayssol, C., Abbo, O., Mouttalib, S., Claudet, I., Labarre, D., Galinier, P., et al. (2014) Invagination intestinale aiguë du nourrisson et de l'enfant: Peut-on encore parler de prédominance automno-hivernale? Étude épidémiologique sur 10 ans. *Archives de Pédiatrie*, **21**, 476-482. <https://doi.org/10.1016/j.arcped.2014.02.016>
- [22] Bines, J.E., Liem, N.T., Justice, F.A., Son, T.N., Kirkwood, C.D., de Campo, M., et al. (2006) Risk Factors for Intussusception in Infants in Vietnam and Australia: Adenovirus Implicated, but Not Rotavirus. *The Journal of Pediatrics*, **149**, 452-460.E1. <https://doi.org/10.1016/j.jpeds.2006.04.010>
- [23] Saida, M. (2011) Invagination intestinale du nourrisson et de l'enfant au service des urgences chirurgicales pédiatriques Hôpital d'enfants-Rabat (A propos de 40 cas). Thèse Médecine, Universitaire Hassan II.

- [24] Saleem, M.M., Al-Momani, H. and Abu Khalaf, M. (2008) Intussusception: Jordan University Hospital Experience. *Hepatogastroenterology*, **55**, 1356-1359.
- [25] Klein, E.J., Kapoor, D. and Shugerman, R.P. (2004) The Diagnosis of Intussusception. *Clinical Pediatrics*, **43**, 343-347. <https://doi.org/10.1177/000992280404300405>
- [26] Simanovsky, N., Hiller, N., Koplewitz, B.Z., Eliahou, R. and Udassin, R. (2006) Is Non-Operative Intussusception Reduction Effective in Older Children? Ten-Year Experience in a University Affiliated Medical Center. *Pediatric Surgery International*, **23**, 261-264. <https://doi.org/10.1007/s00383-006-1838-x>
- [27] Justice, F.A., Auldist, A.W. and Bines, J.E. (2006) Intussusception: Trends in Clinical Presentation and Management. *Journal of Gastroenterology and Hepatology*, **21**, 842-846. <https://doi.org/10.1111/j.1440-1746.2005.04031.x>
- [28] Grapin C. (2004) Invagination intestinale aiguë: Décoder les formes trompeuses. *La Revue du Praticien*, **18**, 285-288.
- [29] Ugwu, B.T., Legbo, J.N., Dakum, N.K., Yiltok, S.J., Mbah, N. and Uba, F.A. (2000) Childhood Intussusception: A 9-Year Review. *Annals of Tropical Paediatrics*, **20**, 131-135. <https://doi.org/10.1080/02724936.2000.11748122>
- [30] Yadav, K., Patel, R.V., Mitra, S.K., et al. (1986) Intussusception in Infancy and Childhood. *Indian Journal of Pediatrics*, **23**, 113-120.
- [31] Ramachandran, P., Vincent, P., Prabhu, S. and Sridharan, S. (2006) Rectal Prolapse of Intussusception—A Single Institution's Experience. *European Journal of Pediatric Surgery*, **16**, 420-422. <https://doi.org/10.1055/s-2006-924732>
- [32] Carbonneil, C. (2009) Principales indications et «non-indications» de la radiographie de l'abdomen sans préparation. HAS. <https://www.has-sante.fr/>
- [33] del-Pozo, G., Albillos, J.C. and Tejedor, D. (1996) Intussusception: US Findings with Pathologic Correlation—The Crescent-in-Doughnut Sign. *Radiology*, **199**, 688-692. <https://doi.org/10.1148/radiology.199.3.8637988>
- [34] Khorana, J., Singhavejsakul, J., Ukarapol, N., Laohapensang, M., Siritwongmongkol, J. and Patumanond, J. (2016) Prognostic Indicators for Failed Nonsurgical Reduction of Intussusception. *Therapeutics and Clinical Risk Management*, **12**, 1231-1237. <https://doi.org/10.2147/tcrm.s109785>
- [35] Strouse, P.J., DiPietro, M.A. and Saez, F. (2003) Transient Small-Bowel Intussusception in Children on CT. *Pediatric Radiology*, **33**, 316-320. <https://doi.org/10.1007/s00247-003-0870-4>
- [36] Stringer, M.D., Pledger, G. and Drake, D.P. (1992) Childhood Deaths from Intussusception in England and Wales, 1984-9. *BMJ*, **304**, 737-739. <https://doi.org/10.1136/bmj.304.6829.737>
- [37] de Lamber, G., Guérin, F., Franchi-Abella, S., Boubnova, J. and Martelli, H. (2015) Invagination intestinale aiguë du nourrisson et de l'enfant. *Journal de Pédiatrie et de Puériculture*, **28**, 118-130. <https://doi.org/10.1016/j.jpp.2015.04.001>