

The Incidence of Endophthalmitis Cases in an Island Nation

Isaac Bertuello, Sarah Refalo-Azzopardi, Anastasia Ghio

Ophthalmology Department, Mater Dei Hospital, Msida, Malta

Email: isaac.bertuello@gov.mt, sarah-maria.azzopardi@gov.mt

How to cite this paper: Bertuello, I., Refalo-Azzopardi, S. and Ghio, A. (2024) The Incidence of Endophthalmitis Cases in an Island Nation. *Open Journal of Ophthalmology*, 14, 236-249. <https://doi.org/10.4236/ojoph.2024.143024>

Received: March 18, 2024

Accepted: August 10, 2024

Published: August 13, 2024

Copyright © 2024 by author(s) and Scientific Research Publishing Inc. This work is licensed under the Creative Commons Attribution International License (CC BY 4.0).

<http://creativecommons.org/licenses/by/4.0/>



Open Access

Abstract

Endophthalmitis is a severe ocular infection which can have sight threatening complications and should be treated urgently. Malta is an archipelago in the middle of the Mediterranean sea, with one main hospital (Mater Dei Hospital), where all emergency ophthalmic cases are referred during the years audited. This allowed the authors to review all the cases of endophthalmitis which presented to Mater Dei Hospital from 2009 to 2020 and to be able to reliably compare incidence of local endophthalmitis cases with worldwide quoted incidence rates. All theatre logbooks documenting procedures locally from 2009 to 2020 were reviewed and patients undergoing intravitreal tap and antibiotics injections were included in this audit. This was based on the assumption that all endophthalmitis cases which presented underwent these procedures. Data was analyzed and the average incidence of endophthalmitis cases noted and compared with international numbers. The local numbers are higher than the accepted average, taking into consideration sources of error during data collection for this audit. The authors suggest that a local standard operating procedure in terms of response of suspected endophthalmitis is needed as well as a register for local endophthalmitis cases.

Keywords

Endophthalmitis, Malta, Ophthalmic Surgery Complications, Cataract, Intravitreal Injections

1. Introduction

Endophthalmitis is a severe intraocular infection, resulting from intraocular colonisation of infectious agents, and may be exogenous or endogenous. In this audit, exogenous endophthalmitis was considered, namely caused by external events such as surgery. Unless treated promptly, endophthalmitis can lead to se-

vere vision loss; it is one of the most serious ophthalmic emergencies which require urgent medical attention and treatment to salvage vision and the integrity of the eye.

The Maltese islands have a unique advantage as it is a small island with short distances and thus easily accessible care. Ophthalmic emergency care is available 24 hours, seven days a week, with an on-site ophthalmologist or trainee available to assess cases within a short timeframe of arrival. Intravitreal injections take place in a clean room in a primary health care setting, in the private sector and the government hospital (Mater Dei Hospital). Vitrectomies and cataract surgeries only take place in one hospital in the private sector and in the main government hospital (MDH). The purpose of this audit is to assess whether these advantages are being reflected in the current care being offered to patients who have unfortunately been diagnosed with endophthalmitis.

Please state whether the human material or human data were performed in accordance with the Declaration of Helsinki. Please provide the ethical approval (including the name of the ethics committee and the reference number).

2. Method

The primary aim of the audit was to identify the number of cases of endophthalmitis in Malta and Gozo which presented from 2009 to 2020. As Mater Dei Hospital is Malta's primary hospital and equipped emergency ophthalmic center, it can be reasonably assumed that all endophthalmitis cases would present or be referred here. As no official register for endophthalmitis cases exists, as standard primary treatment mandates an intravitreal tap and antibiotics, the authors collected the data of patients registered for this procedure from the hospital theatre logbooks.

For the reason above, after permission from the hospital CEO, Ophthalmology chairman and Data protection officer all the cases of intravitreal taps were recovered from the theatre logbooks of 2009 to 2020. The files of these patients were obtained from the medical records section and relevant data extracted. These included: demographics (age, sex, location and co-morbidities), presentation date, presenting and final VA, treatment offered, cultures taken, and time of delay from presentation to intravitreal tapping as well as the possible primary source of the infection.

The total number of ophthalmic surgical cases as well as the subtype of surgery done per year, was obtained from theater records in order to work out the incidence of endophthalmitis post procedure.

3. Results

A total of 81 endophthalmitis cases were reported over the span of twelve years, the majority documented as resulting post-procedure, with eight due to endogenous causes and six being post-traumatic (**Figure 1**). The post-procedure endophthalmitis cases were further subdivided depending on the procedure done:

post-vitrectomy (0.269%) (Figure 2), post-cataract (0.178%) (Figure 3), post-intravitreal injections (0.086%) (Figure 4) with a variation depending on location in the latter (0.027% Mosta health centre, 0.1% Mater Dei Hospital.) (Figure 5) (Table 1 and Table 2)

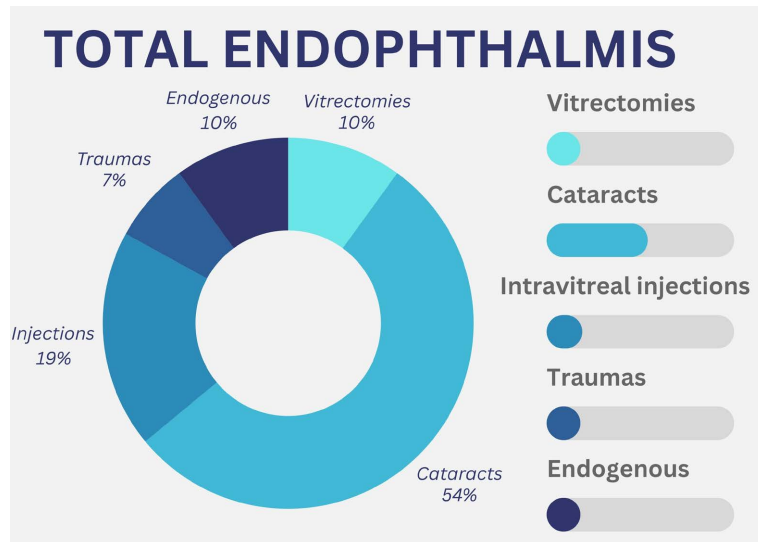


Figure 1. A total of 81 endophthalmitis cases were reported over the span of twelve years, the majority documented as resulting post-procedure, with eight due to endogenous causes and six being post-traumatic.

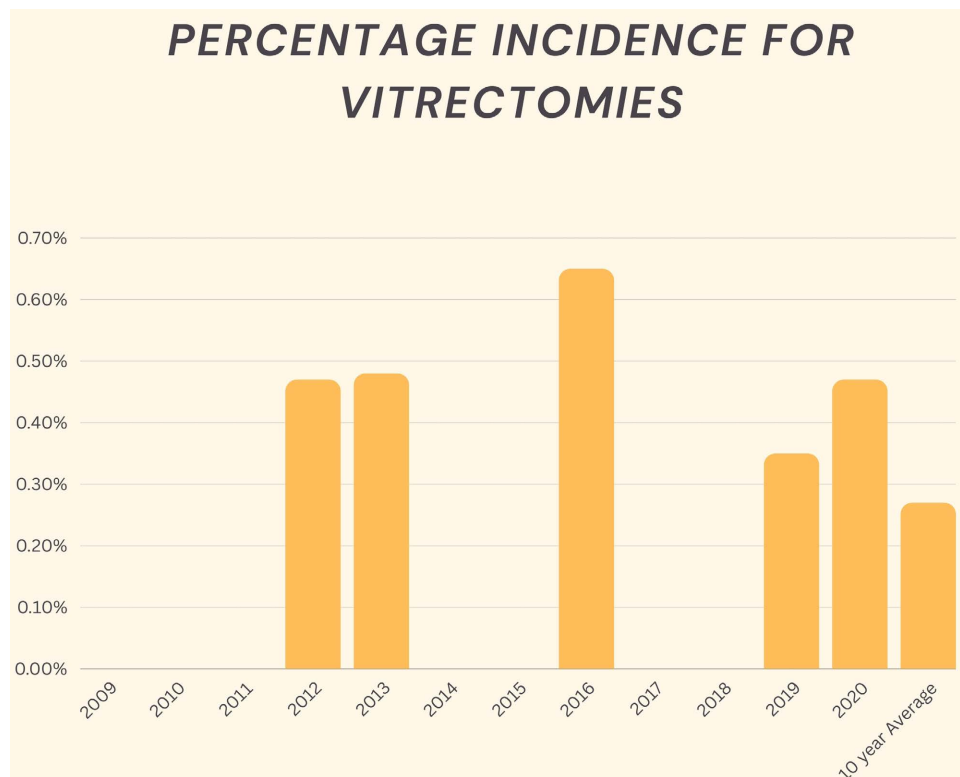


Figure 2. Figure showing the calculated incidence of endophthalmitis for Vitrectomies done between 2009 and 2020 as well as the calculated 10-year average of 0.269%.

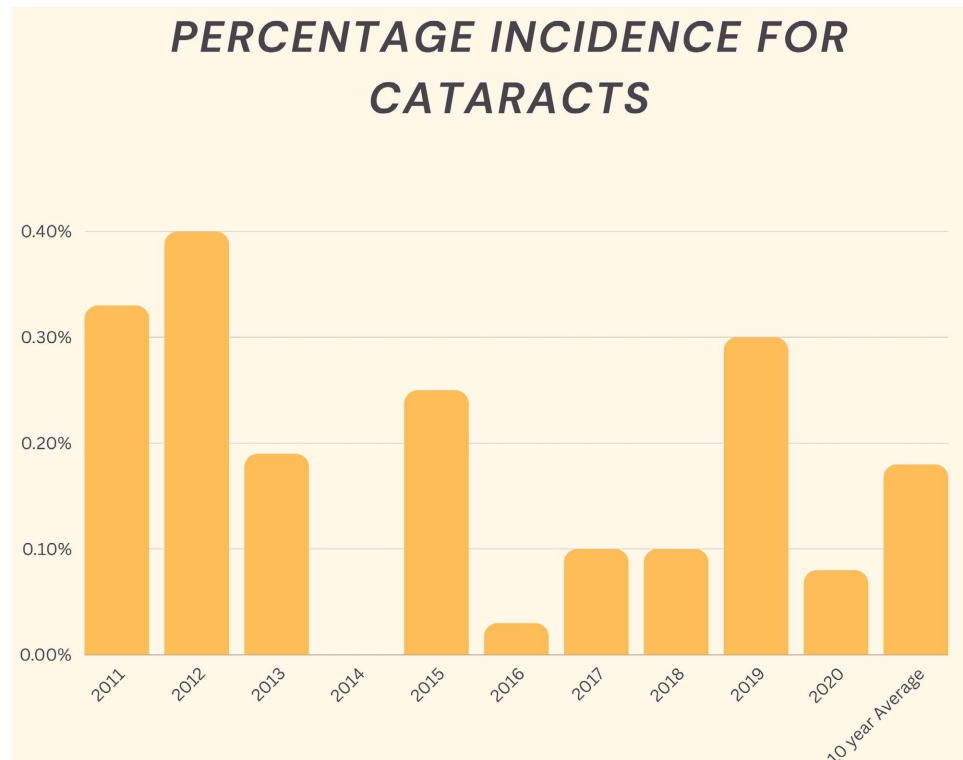


Figure 3. Figure showing the calculated incidence of endophthalmitis for Cataracts done between 2009 and 2020 as well as the calculated 10-year average of 0.178%.

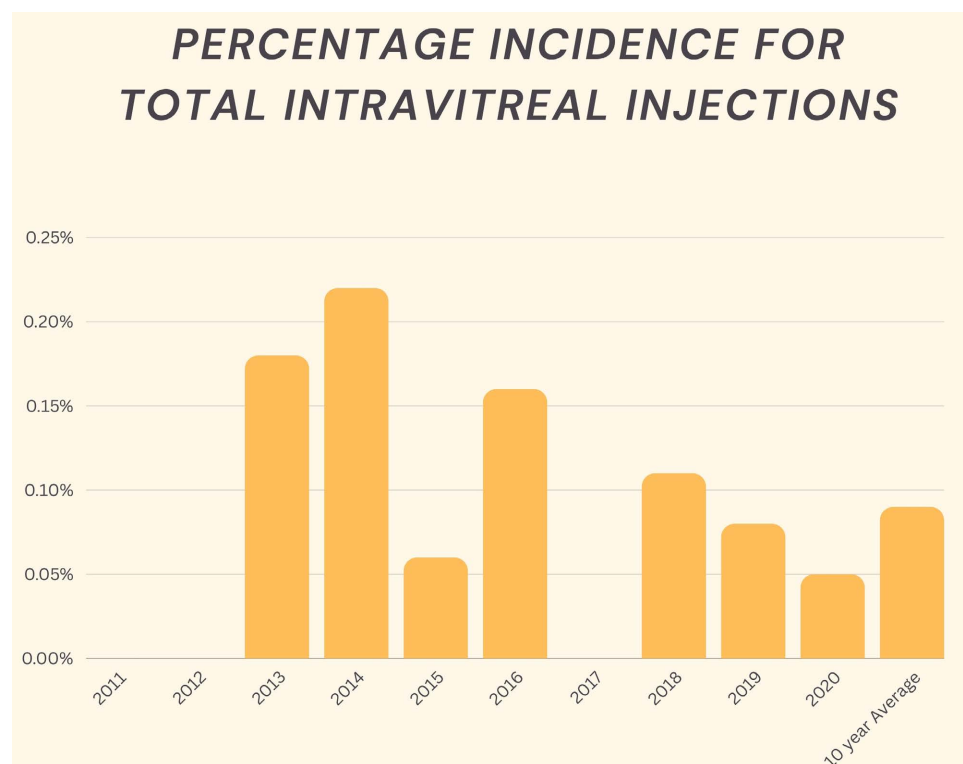


Figure 4. Figure showing the calculated incidence of endophthalmitis for Total Intravitreal Injection done between 2009 and 2020 as well as the calculated 10-year average of 0.086%. These included those performed in the Mater Dei Hospital as well as Mosta Health Centre.

Percentage incidence for intravitreal injections MOSTA HC VS MATER DEI HOSPITAL

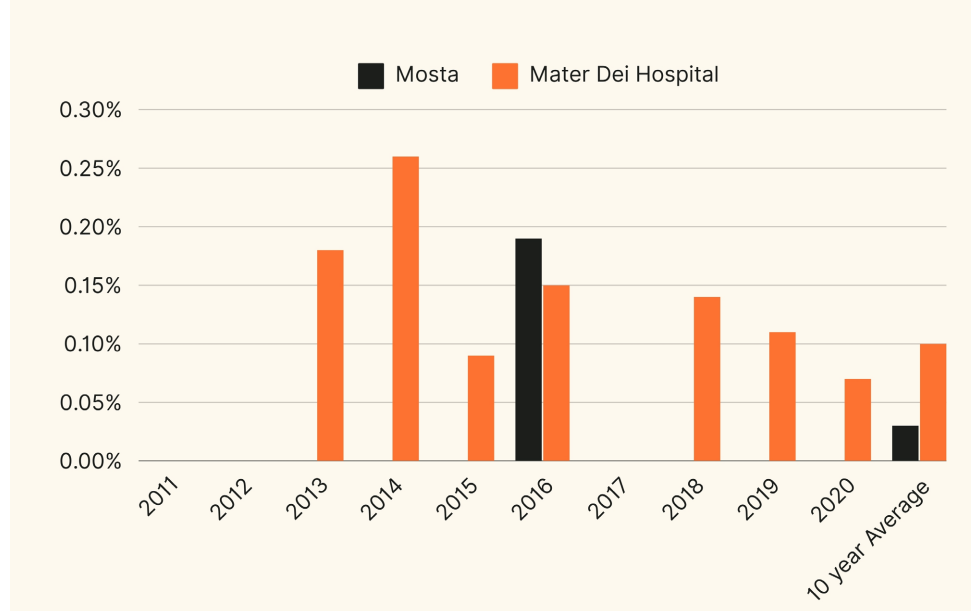


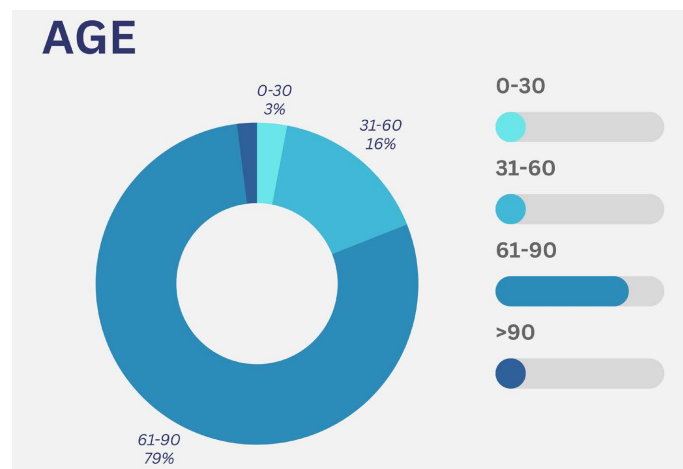
Figure 5. Figure comparing the calculated incidence of endophthalmitis for Intravitreal Injection done in Mater Dei Hospital vs those done at Mosta Health Centre between 2009 and 2020 as well as the calculated 10-year average. Showing that there was a threefold higher incidence of endophthalmitis cases post intravitreal injection in Mater Dei Hospital compared to Mosta Health Centre.

Table 1. Table showing the total number of endophthalmitis cases in Malta over 12 years (2009-2020). Data was obtained from the theatre logbooks by looking at all the cases of intravitreal taps and intravitreal antibiotics since no register for endophthalmitis cases exists.

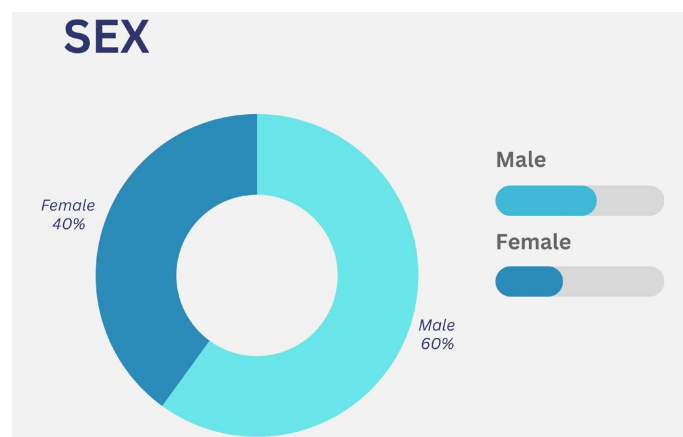
Year	No of Vitrectomies	No of cataracts	No of intravitreal injection Mosta	No of intravitreal injection MDH	Total Intra Vit	Traumas	Endogenous	Total
2009	1	2					1	4
2010	1	3				1		5
2011		8						8
2012	1	10					1	12
2013	1	4		2	2	1		8
2014				3	3		2	5
2015		7		1	1	2		10
2016	2	1	1	2	3		2	8
2017		3				1		4
2018		3		3	3			6
2019	1	1		2	2	1		5
2020	1	2		1	1		2	6
Total	8	44	1	14	15	6	8	81

Table 2. Table showing the total number of procedures done in Malta over 12 years (2009-2020) as well as the subtype of surgery done per year, was obtained from theater records in order to work out the incidence of endophthalmitis post procedure.

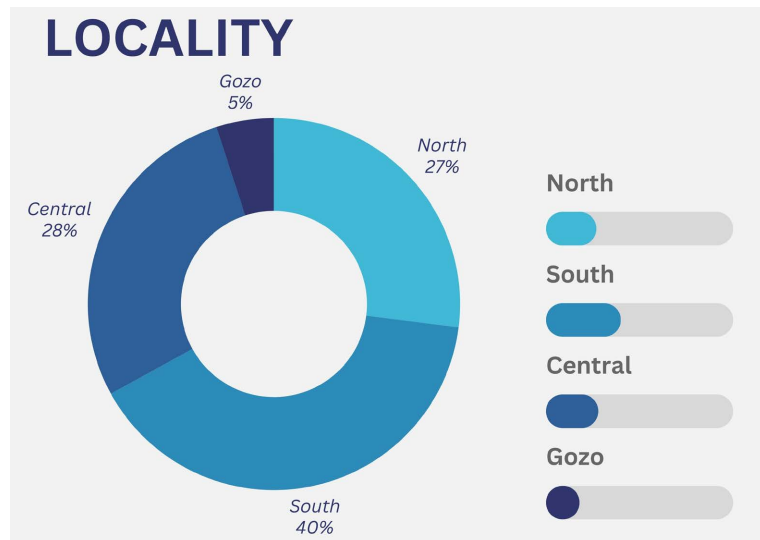
Year	No of Vitrectomies	No of cataracts	No of intravitreal injection Mosta	No of intravitreal injection MDH	Total Intra Vit
2011	195	2418	None	556	556
2012	214	2530	None	833	833
2013	210	2085	None	1132	1132
2014	233	3629	213	1144	1357
2015	264	2783	409	1135	1544
2016	310	3192	519	1367	1886
2017	302	2898	514	1561	2075
2018	296	2920	505	2110	2615
2019	288	3357	783	1845	2628
2020	212	2369	602	1370	1972
Total	2524	28181	3545	13053	16598



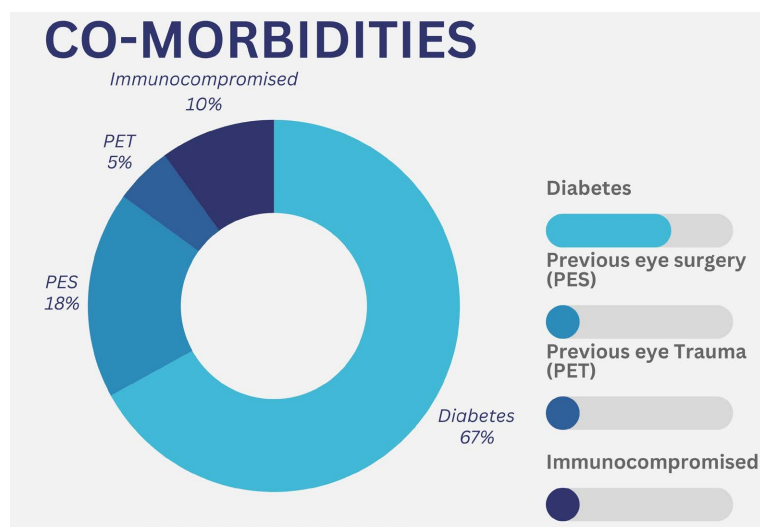
(a)



(b)



(c)



(d)

Figure 6. (a) Figure stratifying the total cases of endophthalmitis in different age categories. 0 - 30 3%, 31 - 60 16%, 61 - 90 79% and >90 2%; (b) Figure stratifying of the total cases of endophthalmitis for Sex. 40% of the patients were female while 60% were male; (c) Figure stratifying the total cases of endophthalmitis according to locality where the patient lived. It shows that 40% of the patients resided in the south of Malta, followed by 28% and 27% who resided in the central and northern parts of Malta respectively, while 5% lived in the sister island of Malta, Gozo; (d) Figure illustrating that the commonest co-morbidity documented in the patients with endophthalmitis was diabetes (67%), followed by having had previous eye surgery (PES) (18%), followed by being immunocompromised (10%) and finally by having had previous eye trauma (10%).

There was a higher incidence of endophthalmitis in the age group of 61 - 90 (**Figure 6(a)**). The number of cases in the male population was higher (**Figure 6(b)**), and the majority of patients were from the southern region of the island (**Figure 6(c)**). Diabetics were also noted to have a higher incidence of endophthalmitis (**Figure 6(d)**).

90% of patients presented with visual acuity (VA) of 6/60 or less, with only 5% having VA of 6/6 - 6/12 and 5% having VA of 6/18 - 6/36. This was in direct contrast with the final visual acuity, with the majority of patients (61%) having VA of 6/18 - 6/36, while 9% had VA of 6/6 - 6/12 and 30% had a VA of 6/60 or worse (Figure 7(a)). On further analysis it was noted that 80 percent of patients had a better final VA, while 11% had the same VA and only 9% of patients had a worse final VA (Figure 7(b)).

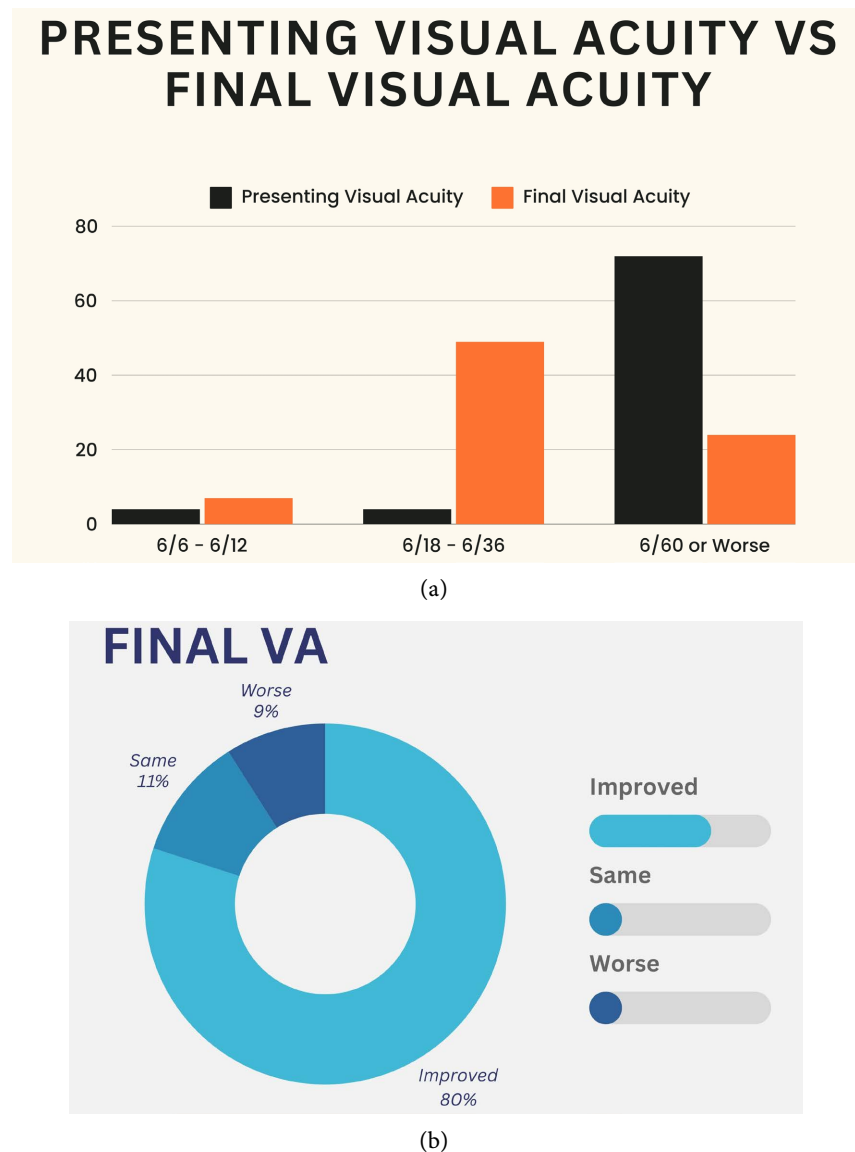


Figure 7. (a) Figure comparing the presenting visual acuity of patients who presented with endophthalmitis compared to the final visual acuity of these patients post treatment. 90% of patients presented with visual acuity (VA) of 6/60 or less, with only 5% having VA of 6/6 - 6/12 and 5% having VA of 6/18 - 6/36. This was in direct contrast with the final visual acuity, with the majority of patients (61%) having VA of 6/18 - 6/36, while 9% had VA of 6/6 - 6/12 and 30% had a VA of 6/60 or worse. (b) Figure illustrating that the majority patients had an improved visual acuity post treatment of endophthalmitis (80%), while 11% retained the same visual acuity and 9% ended up with a worse visual acuity.

Data analysis of management timeline showed that there was variance in the time of tapping and intravitreal antibiotic administration – in 64% of patients, initial tapping and antibiotic injection occurred within 24 hours after presentation, in 16% this occurred between 24 - 48 hours post presentation and in 20% it occurred more than 48 hours post-presentation (**Figure 8**).

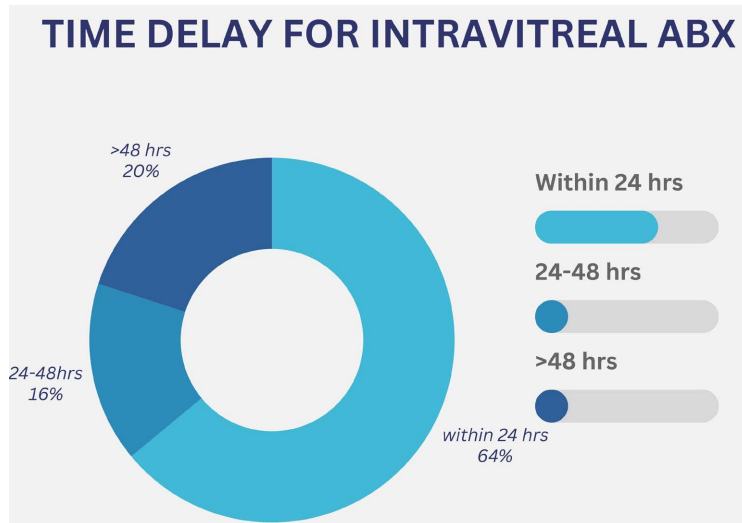


Figure 8. Figure illustrating that the majority of patients received intravitreal antibiotic treatment with 24 hours (64%) while 16% received the treatment between 24 and 48 hours and 20% received their treatment later than 48 hours after presentation and diagnosis.

Most patients were offered intravitreal tap and antibiotics (77%) while 12% were offered just intravitreal antibiotics without a tap and only 11% were offered an additional vitrectomy to intravitreal tap and antibiotics (**Figure 9**).

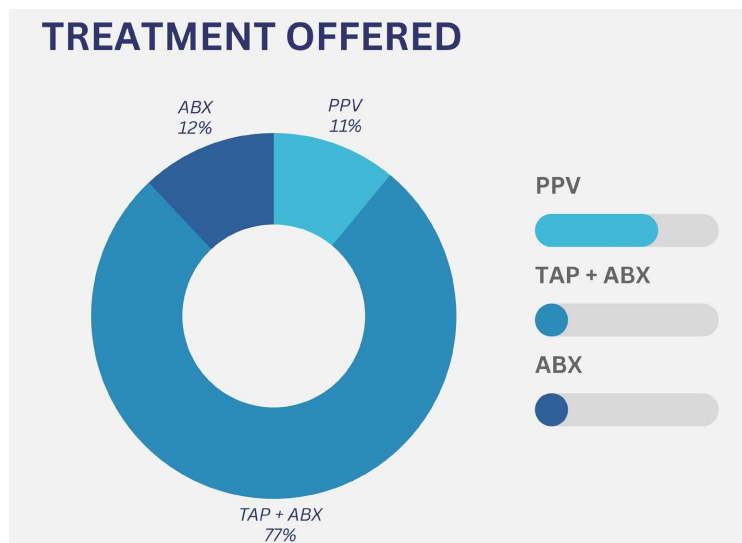
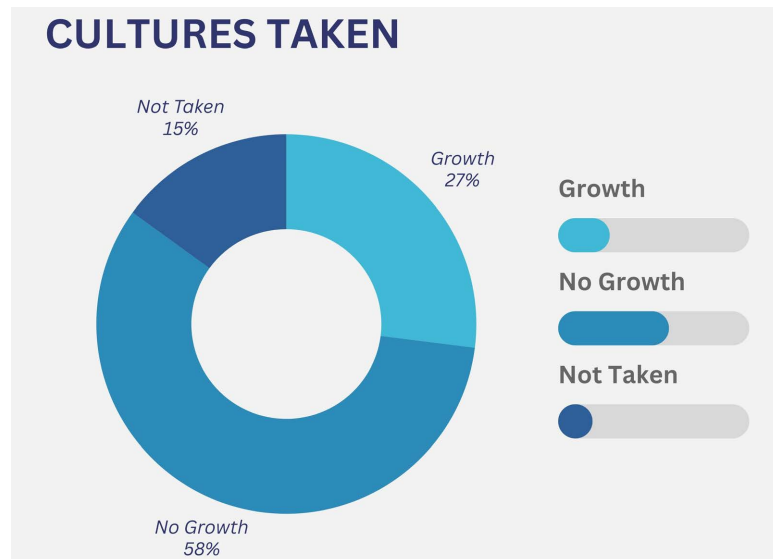
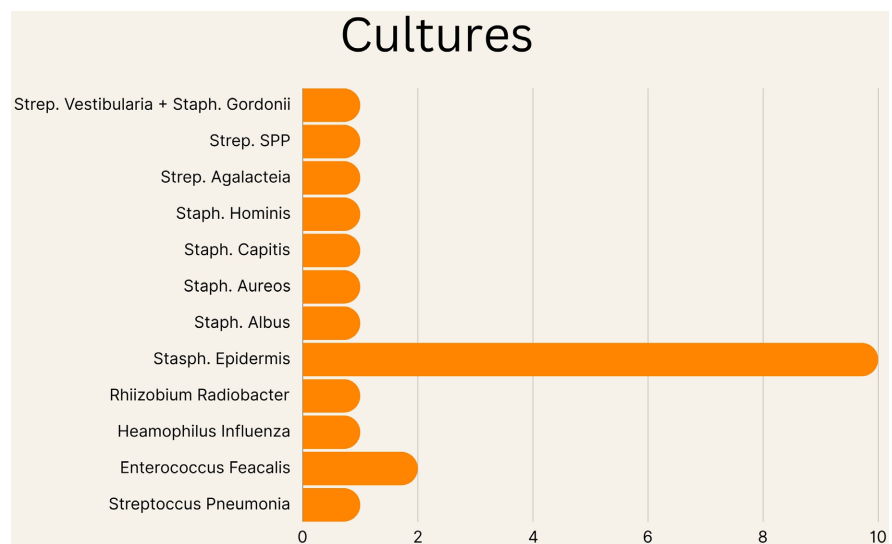


Figure 9. Figure illustrating the different treatments received by the patients diagnosed with endophthalmitis in Malta between 2009 and 2020, with the majority (77%) receiving an intravitreal tap and antibiotics, 12% receiving intravitreal antibiotics alone and 11% of patients underwent a vitrectomy.



(a)



(b)

Figure 10. (a) Figure illustrating that majority of the patients diagnosed with endophthalmitis in Malta between 2009 and 2020 had cultures taken in the form of an intravitreal tap (85%). This resulted in 58% of the total patients with endophthalmitis having no growth in their cultures while 27% had positive cultures; (b) Figures illustrating that a variety of microbes were cultured, with the majority resulting positive for *Staph. Epidermidis*. Two cultures were positive for *Enterococcus faecalis* and in others the following bacteria were grown: *Streptococcus pneumonia*, *Haemophilus influenza*, *Rhizobium Radiobacter*, *Staph. Albus*, *Staph. Aureous*, *Staph. Capitalis*, *Staph Hominis*, *Step Agalactea*, *Strep. SPP* and *Strep. Vestibula* with *Staph. Gordonii*.

Despite the majority of patients being tapped and a culture sent prior to treatment (86%), 58% of these patients had negative cultures (**Figure 10(a)**). A variety of microbes were cultured, with the majority resulting positive for *Staph. Epidermidis*. Two cultures were positive for *Enterococcus faecalis* and in others the following bacteria were grown: *Streptococcus pneumonia*, *Haemophilus in-*

fluenza, Rhizobium Radiobacter, Staph. Albus, Staph. Aureous, Staph. Capitalis, Staph Hominis, Step Agalacteia, Step. SPP and Strep. Vestibula with Staph. Gordonii (Figure 10(b)).

4. Discussion

Endophthalmitis is defined as a purulent inflammation of the intraocular fluids usually due to an infection. It is very serious with significant sight threatening complications. It is one of the rare but possible complications post intraocular surgeries and procedures including intravitreal injections [1]. The aim of this audit was to compare the local incidence of endophthalmitis and compare it to other international studies, with plan to adjust local protocols as necessary.

During this audit, a number of limitations were noted. No data on the total number of ophthalmic surgeries 2009-2010 was available. There was also no data available on the penetrating eye traumas. Medical notes at times were incomplete with casualty notes missing and did not define the presenting complaint or suspected underlying cause. Five medical files were missing and hence these patients were not included in the study, which may lead to skewed data.

The authors identified the number of patients with endophthalmitis through Mater Dei theater data; patients who sought treatment at Gozo General Hospital or privately were not included. Tapping and cultures are usually done by the more junior members of the team, which can result in variation in method and successful culture.

The incidence of endophthalmitis post cataract surgeries in Mater Dei Hospital was 0.178% which is higher when comparing to a recent retrospective cohort study in the US with an incidence of 0.04% [2], while a case series from Asian countries have reported an incidence varying from 0.023% to 0.076% [3] [4]. The incidence of endophthalmitis post pars plana vitrectomy in Mater Dei Hospital was 0.269% which was compared to 0.05% obtained from a systematic review and Meta-Analysis of Chen *et al.* [5]. This meant that there is a 5 fold higher risk of endophthalmitis post vitrectomy in MDH. The incidence of endophthalmitis post intravitreal injections in Malta was 0.086% (0.027% when given at Mosta Health Centre while 0.1% when given at Mater Dei Hospital). An incidence of 0.016% was quoted in a retrospective cohort study in the US [2], while a case series from Asian Countries reported an incidence varying between 0.01% to 0.1% [6].

These worrying numbers might be mildly falsely elevated since there were 3 endophthalmitis cases which came from the private sector post operatively; 2 patients came from Gozo and 1 patient had been operated abroad. Unfortunately, we had no data on the number of surgeries done privately and the number of surgeries done in Gozo General Hospital.

It was noted that locally, the highest risk factor for endophthalmitis was found to be diabetes, followed by previous ocular eye surgery, being immunocompromised and trauma respectively. Endophthalmitis was mostly reported in the 61 -

90 age group. This also corresponds to the age group with highest number of surgeries.

Similar to studies abroad, the commonest organism responsible for endophthalmitis, especially post operative endophthalmitis, is *Staphylococcus Epidermidis*, which is a gram positive, anaerobic bacteria one typically finds on the human skin flora. The second commonest organism was enterococcus faecalis [7] [8]. 15% of patient did not have a culture sent most probably since the tap was dry. This corresponded well to the 22% percent of dry taps reported in the study of Bhikoo *et al.* which reviewed around 600 endophthalmitis cases an American tertiary ophthalmological hospital [9]. It is interesting to note that from all the cultures taken, 68 percent of the cultures resulted back as no growth, which can be compared to 55% no growth in Bhikoo *et al.*'s study [9].

Although the diagnosis of endophthalmitis is a clinical diagnosis, by identifying the responsible organism with cultures methods is important not just to confirm the diagnosis but to guide treatment. By knowing what organism is responsible and its sensitivities, treatment can be targeted. This is mostly helpful in patients who fail to improve after the first dose of broad spectrum intravitreal antibiotics, usually because the infection is caused by an atypical or antibiotic resistant organism.

Another important reason for cultures is that it helps in identifying commonalities and the possible cause of an outbreak of cases. The current practice of giving intravitreal vancomycin when diagnosing endophthalmitis is still recommended as studies show that the majority of gram-positive bacteria were sensitive to vancomycin *in vitro* [10]. The audit data showed 90% of cultures were gram positive.

For gram negative cover, intravitreal Amikacin is administered, to which only around 7% of gram-negative bacteria are resistant [11]. However, Amikacin carries the risk of macular toxicity and another option such as a third generation cephalosporin, like Ceftazidime which also has a very broad spectrum cover for gram negative bacteria, can be considered [12].

Most patients treated for endophthalmitis had an improvement in their final visual acuity (VA) when compared to their presenting VA, 80% as one can see in the results. Most of the treatment involved an intravitreal tap with intravitreal antibiotics, oral antibiotics (Ciprofloxacin 750 mg BD) and topical antibiotics drops (Fortified Gentamycin and Ceftazidime). This accounted to 77% while another 11% were offered a vitrectomy as an addition to the treatment. Studies have shown that early vitrectomy in endophthalmitis leads to VA gain and its benefits usually outweigh the risks [13]. This suggests that the current treatment offered is comparable to international standards, however, despite the availability of care and easy access to patients, the authors believe that change in pre and post operative care would be beneficial. A standard operating procedure would be beneficial, both as a safeguard for surgeons as well as for the patient, reducing risk of liability and improved patient outcomes. The results obtained from this audit also suggest that there needs to be a pathway for suspected endophthalmi-

tis cases, to ensure that each patient receives the same high standard of care. A register of endophthalmitis cases would also be beneficial in ensuring that data is more easily accessible, and reauditing done in a more timely and regular manner.

5. Conclusion

After reviewing the results of the audit and comparing them to studies abroad, it can be concluded that the local numbers are higher than the accepted average, taking into consideration sources of error during data collection for this audit. The authors suggest that having a local standard operating procedure for pre and post operative care in the above mentioned procedures, as well as an agreed protocol in terms of response of suspected endophthalmitis would standardise care and improved patient safety. A local register for diagnosed endophthalmitis cases would allow better data and statistics to be audited. Post implementation a repeat of the audit can be done.

Funding

No funding was present.

Conflicts of Interest

We would like to declare no conflict of interest.

References

- [1] Vaziri, K., Schwartz, S., Kishor, K. and Flynn, H. (2015) Endophthalmitis: State of the Art. *Clinical Ophthalmology*, **9**, 95-108. <https://doi.org/10.2147/OPTH.S76406>
- [2] Pershing, S., Lum, F., Hsu, S., Kelly, S., Chiang, M.F., Rich, W.L. and Parke, D.W. (2020) Endophthalmitis after Cataract Surgery in the United States: A Report from the Intelligent Research in Sight Registry, 2013-2017. *Ophthalmology*, **127**, 151-158. <https://doi.org/10.1016/j.ophtha.2019.08.026>
- [3] Jabbarvand, M., Hashemian, H., Khodaparast, M., Jouhari, M., Tabatabaei, A. and Rezaei, S. (2016) Endophthalmitis Occurring after Cataract Surgery: Outcomes of More Than 480000 Cataract Surgeries, Epidemiologic Features, and Risk Factors. *Ophthalmology*, **123**, 295-301. <https://doi.org/10.1016/j.ophtha.2015.08.023>
- [4] Yao, K., Zhu, Y., Zhu, Z., Wu, J., Liu, Y., Lu, Y., Hao, Y., Bao, Y., Ye, J., Huang, Y., Li, Z., Shentu, X.C. and Yu, Y. (2013) The Incidence of Postoperative Endophthalmitis after Cataract Surgery in China: A Multicenter Investigation of 2006-2011. *British Journal of Ophthalmology*, **97**, 1312-1317. <https://doi.org/10.1136/bjophthalmol-2013-303282>
- [5] Chen, G., Tzekov, R., Li, W., Jiang, F., Mao, S. and Tong, Y. (2019) Incidence of Endophthalmitis after Vitrectomy: A Systematic Review and Meta-Analysis. *Retina*, **39**, 844-852. <https://doi.org/10.1097/IAE.0000000000002055>
- [6] Xu, K., Chin, E.K., Bennett, S.R., Williams, D.F., Ryan, E.H., Dev, S., Mittra, R.A., Quiram, P.A., Davies, J.B., Parke, D.W., Johnson, J.B., Cantrill, H.L. and Almeida, D.R.P. (2018) Endophthalmitis after Intravitreal Injection of Vascular Endothelial Growth Factor Inhibitors: Management and Visual Outcomes. *Ophthalmology*, **125**, 1279-1286. <https://doi.org/10.1016/j.ophtha.2018.01.022>

- [7] Mithal, K., Mathai, A., Pathengay, A., Jalali, S., Relhan, N., Motukupally, S.R., Sharma, S. and Das, T. (2013) Endophthalmitis Following Intravitreal Anti-VEGF Injections in Ambulatory Surgical Centre Facility: Incidence, Management and Outcome. *British Journal of Ophthalmology*, **97**, 1609-1612. <https://doi.org/10.1136/bjophthalmol-2013-303222>
- [8] Falavarjani, K.G., Modarres, M., Hashemi, M., Parvaresh, M.M., Naseripour, M., Zare-Moghaddam, A. and Nekoozadeh, S. (2013) Incidence of Acute Endophthalmitis after Intravitreal Bevacizumab Injection in a Single Clinical Center. *Retina*, **33**, 971-974. <https://doi.org/10.1097/IAE.0b013e31826f0675>
- [9] Bhikoo, R., Wang, N., Welch, S., Polkinghorne, P. and Niederer, R. (2020) Factors Associated with Positive Microbial Culture in Patients with Endophthalmitis Based on Clinical Presentation and Multimodal Intraocular Sampling. *Asia-Pacific Journal of Ophthalmology*, **9**, 4-8. <https://doi.org/10.1097/APO.0000000000000263>
- [10] Department of Clinical Microbiology ACH (2019) Antimicrobial Susceptibility Test Results for Gram-Positive Isolates Recovered from Clinical Specimens: 2018. <http://www.labplus.co.nz/clinical-resources/antibiotic-susceptibility-reports/>
- [11] Chen, K.J., Sun, M.H., Hou, C.H., *et al.* (2021) Susceptibility of Bacterial Endophthalmitis Isolates to Vancomycin, Ceftazidime, and Amikacin. *Scientific Reports*, **11**, Article 15878. <https://doi.org/10.1038/s41598-021-95458-w>
- [12] Galloway, G., Ramsay, A., Jordan, K., *et al.* (2002) Macular Infarction after Intravitreal Amikacin: Mounting Evidence Against Amikacin. *British Journal of Ophthalmology*, **86**, 359-360. <https://doi.org/10.1136/bjo.86.3.359>
- [13] Negretti, G.S., Chan, W., Pavesio, C. and Muqit, M.M.K. (2020) Vitrectomy for Endophthalmitis: 5-Year Study of Outcomes and Complications. *BMJ Open Ophthalmol*, **5**, E000423. <https://doi.org/10.1136/bmjophth-2019-000423>