

Laparoscopic Management of Adnexal Torsion during Pregnancy in Dalal Jamm Hospital Center: A Case Report

Ndeye Racky Sall¹, Mame Diarra Ndiaye^{1,2}, Philippe Marc Moreira^{1,2}

¹Department of Gynecology and Obstetrics, Dalal Jamm National Hospital Center, Dakar, Senegal

²Department of Medicine, Cheikh Anta Diop University, Dakar, Senegal

Email: nrackysall@gmail.com

How to cite this paper: Sall, N.R., Ndiaye, M.D. and Moreira, P.M. (2025) Laparoscopic Management of Adnexal Torsion during Pregnancy in Dalal Jamm Hospital Center: A Case Report. *Open Journal of Obstetrics and Gynecology*, 15, 1147-1152.
<https://doi.org/10.4236/ojog.2025.157093>

Received: May 30, 2025

Accepted: July 26, 2025

Published: July 29, 2025

Copyright © 2025 by author(s) and Scientific Research Publishing Inc.

This work is licensed under the Creative Commons Attribution International License (CC BY 4.0).

<http://creativecommons.org/licenses/by/4.0/>



Open Access

Abstract

Background: Adnexal torsion is a surgical emergency caused by the complete or partial rotation of the adnexa around its supporting ligaments. It typically presents with nonspecific symptoms, such as nausea, vomiting, and lower abdominal pain. During pregnancy, diagnosis is particularly challenging, as these symptoms may overlap with normal gestational complaints. A delayed diagnosis can result in adnexal necrosis, potentially compromising both maternal and fetal outcomes. **Objective:** We reported two cases of laparoscopic surgical management of adnexal torsion during pregnancy. **Conclusion:** In our context, the diagnosis and management of adnexal torsion during pregnancy remain significant challenges. This report aims to highlight the feasibility and safety of laparoscopic management in low-resource settings.

Keywords

Adnexal Torsion, Laparoscopy, Pregnancy

1. Introduction

Adnexal torsion is an uncommon surgical emergency, accounting for approximately 2% - 3% of cases of acute pelvic pain [1]. It refers to the complete or partial rotation of the adnexa on its ligamentous supports [2]. Assisted reproductive techniques and pregnancy are recognized risk factors for adnexal torsion [3] [4].

During pregnancy, diagnosis is particularly challenging due to the heterogeneity of symptoms [5]. Delayed diagnosis increases the risk of adnexal necrosis, potentially leading to adverse maternal and fetal outcomes [6].

Advances in pelvic ultrasound technology have enhanced the early detection of

adnexal torsion, even during pregnancy [2] [7]. Transvaginal ultrasonography remains the first-line diagnostic tool for evaluating patients with acute pelvic pain [7] [8].

In high-resource countries, laparoscopic surgery is considered the gold standard for minimizing postoperative complications [8]-[10]. In West Africa, however, data on laparoscopic surgeries during pregnancy remain limited. Recent studies from Yaoundé, though, have evaluated the safety and effectiveness of laparoscopic procedures during pregnancy, supporting their feasibility in similar low-resource settings [11].

This article presents two cases of laparoscopic management of adnexal torsion during pregnancy at a university hospital in Dakar, highlighting the feasibility of this approach in a low-resource setting.

2. Case Report

2.1. Case 1

A 28-year-old primiparous woman at 10 weeks of gestation presented to our department with a 48-hour history of vomiting and paroxysmal pelvic pain. On clinical examination, she was hemodynamically stable, afebrile, and exhibited tenderness in the right iliac fossa.

Pelvic ultrasound confirmed a viable intrauterine pregnancy at 10 weeks of gestation, associated with a trophoblastic hematoma. The right ovary measured 63 × 41 mm, showed a heterogeneous echotexture, was tender on sonographic palpation, and demonstrated marked edema.

Three hours after admission, laparoscopy was performed via a supraumbilical incision. A pneumoperitoneum was established at 15 mmHg using a Veress needle and subsequently reduced to 10 mmHg after trocar placement. Two 5 mm working trocars were inserted—one in the suprapubic region and the other in the left iliac fossa. Intraoperative exploration revealed a right adnexal torsion with three twists. The ovary, containing the corpus luteum, and the distal portion of the fallopian tube appeared necrotic (**Figure 1**). The contralateral adnexa appeared normal. Initial management consisted of detorsion; however, due to the necrotic appearance of the adnexa, a right adnexectomy was subsequently

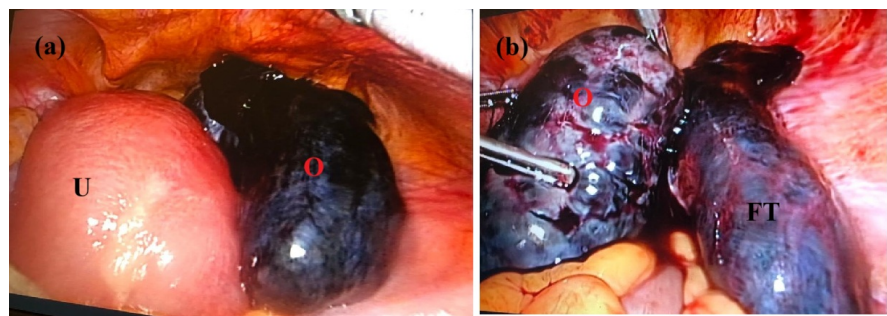


Figure 1. Intraoperative images. (a) Adnexal torsion with a necrotic aspect of the right ovary. (b) Ovary and fallopian tube after detorsion. U, uterus; O, ovary; FT, Fallopian tube.

performed (**Figure 1**). The total operative time was approximately one hour.

Vaginal progesterone supplementation was provided after surgery. On the postoperative day, a follow-up ultrasound revealed a non-progressive pregnancy. Medical management was initiated using misoprostol, with no reported complications.

Histopathological examination confirmed necrotic adnexal tissue with no evidence of malignancy.

Informed consent for laparoscopic surgery was obtained from the couple prior to the procedure, and the patient was thoroughly counseled regarding the associated risks.

2.2. Case 2

Four months later, a 30-year-old primigravida at 13 weeks of gestation was admitted with paroxysmal pelvic pain and vomiting. She had previously been hospitalized at 9 weeks for hyperemesis gravidarum. Clinical examination revealed signs of dehydration.

An initial ultrasound, performed by a gynecology fellow confirmed a viable intra-uterine pregnancy. The patient experienced less pain after receiving analgesics. Due to recurrence of pain, the ultrasound was repeated by a senior gynecologist. It revealed a right ovary measuring 52 × 30 mm with a multifollicular appearance and associated edema, located in the right flank. The contralateral adnexa appeared normal.

Laparoscopy was performed due to suspected adnexal torsion, following the same procedural approach as previously described. Intraoperative exploration revealed a gravid uterus and the right ovary displaced to the right flank. A right adnexal torsion with one and a half twists was diagnosed (**Figure 2**). After detorsion, the ovary appeared viable, exhibiting an acceptable macroscopic appearance. The operative time was approximately 30 minutes.

Progesterone supplementation was administered. The pregnancy progressed without complications and resulted in a successful term vaginal delivery. Informed consent for laparoscopic surgery was obtained, and the patient was fully informed of the associated risks.

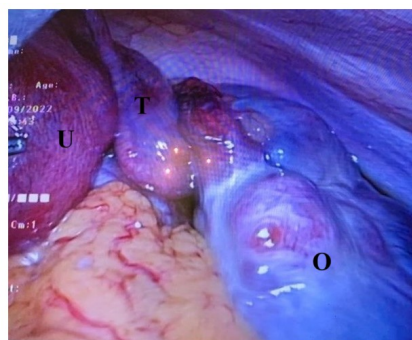


Figure 2. Intraoperative view of right adnexal torsion showing twisted adnexa. U, uterus; T, torsion; O, ovary.

3. Discussion

We report two cases of laparoscopic management of adnexal torsion during pregnancy, with no adverse complications related to the surgical approach. Highlighting the feasibility of performing laparoscopic surgery in emergency settings is important in our country to help build practitioners' confidence

Access to high-quality care remains a significant challenge for patients in low-resource settings, largely due to economic constraints. In our first case, a 48-hour delay in seeking care contributed to adverse maternal and fetal outcomes. Diagnosing adnexal torsion during pregnancy is particularly challenging because its nonspecific symptoms often overlap with common pregnancy-related complaints. Adnexal torsion occurs more frequently during the first trimester. The typical presentation includes acute pelvic pain in the right lower quadrant, often accompanied by nausea or vomiting. Ultrasound findings commonly reveal adnexal enlargement with decreased or absent blood flow [3] [5] [6].

Transabdominal and transvaginal ultrasound are the first-line imaging modalities for evaluating patients with acute pelvic pain. However, ultrasound is highly operator-dependent. As a referral center for prenatal ultrasound diagnosis, our fellows receive dedicated training to enhance their ultrasound skills and reduce variability related to operator expertise. Nonetheless, diagnosing adnexal torsion remains challenging, especially for less experienced practitioners, which may explain the delayed diagnosis in our second patient. Furthermore, several studies have aimed to identify the most specific sonographic signs of adnexal torsion. Findings such as ovarian edema, the "whirlpool sign", and decreased or absent ovarian doppler flow are considered highly specific, although they demonstrate only moderate sensitivity for confirming the diagnosis [2] [7].

At our institution, a laparoscopic approach is preferred for all surgical cases when patients are hemodynamically stable. During pregnancy, laparoscopy is performed up to 14 weeks of gestation, limited by the unavailability of trocars suitable for open laparoscopy beyond this period [12]-[14]. Both of our patients were diagnosed during the first trimester, which allowed for the safe creation of pneumoperitoneum using a Veress needle. In accordance with established guidelines, pneumoperitoneum was initiated at 15 mmHg and reduced after trocar placement [9]. Adverse effects related to pneumoperitoneum appear to be theoretical when intra-abdominal pressure is maintained below 15 mmHg [10]. Moreover, special attention is required during trocar insertion to avoid injury. Despite these precautions, the safety and effectiveness of laparoscopic surgery during pregnancy are well established and widely accepted [10] [12] [13] [14].

We recorded one case of miscarriage, most likely attributable to delayed diagnosis rather than the surgical intervention itself. Postoperative maternal monitoring was conducted according to standard guidelines [13]. During the first trimester, a follow-up ultrasound is recommended after surgery to assess pregnancy progression [13]. In our cases, the adnexal torsions involved the corpus luteum. Given its essential role in progesterone secretion until 12 weeks of gestation, we

opted to provide progesterone supplementation to support the pregnancy [15].

These case reports assess the feasibility of laparoscopic surgery during pregnancy in our setting. Promoting the use of such procedures is essential for improving cultural acceptance and facilitating their integration into routine clinical practice.

4. Conclusion

Enhancing women's health remains a major challenge in low-resource countries. Laparoscopic surgery during pregnancy is considered safe when performed by experienced providers and is recognized as the gold standard for managing adnexal torsion. Strengthening practitioners' competencies and improving access to minimally invasive surgical equipment are realistic and impactful goals that can significantly improve the quality of maternal care.

Acknowledgements

Consent was obtained from all patients.

Conflicts of Interest

The authors declare no conflicts of interest regarding the publication of this paper.

References

- [1] Hibbard, L.T. (1985) Adnexal Torsion. *American Journal of Obstetrics and Gynecology*, **152**, 456-461. [https://doi.org/10.1016/s0002-9378\(85\)80157-5](https://doi.org/10.1016/s0002-9378(85)80157-5)
- [2] Dawood, M.T., Naik, M., Bharwani, N., Sudderuddin, S.A., Rockall, A.G. and Stewart, V.R. (2021) Adnexal Torsion: Review of Radiologic Appearances. *RadioGraphics*, **41**, 609-624. <https://doi.org/10.1148/rg.2021200118>
- [3] Sasaki, K.J. and Miller, C.E. (2014) Adnexal Torsion: Review of the Literature. *Journal of Minimally Invasive Gynecology*, **21**, 196-202. <https://doi.org/10.1016/j.jmig.2013.09.010>
- [4] Gorkemli, H., Camus, M. and Clasen, K. (2002) Adnexal Torsion after Gonadotrophin Ovulation Induction for IVF or ICSI and Its Conservative Treatment. *Archives of Gynecology and Obstetrics*, **267**, 4-6. <https://doi.org/10.1007/s00404-001-0251-x>
- [5] Didar, H., Najafiarab, H., Keyvanfar, A., Hajikhani, B., Ghotbi, E. and Kazemi, S.N. (2023) Adnexal Torsion in Pregnancy: A Systematic Review of Case Reports and Case Series. *The American Journal of Emergency Medicine*, **65**, 43-52. <https://doi.org/10.1016/j.ajem.2022.12.026>
- [6] Wang, Y. and Deng, S. (2020) Clinical Characteristics, Treatment and Outcomes of Adnexal Torsion in Pregnant Women: A Retrospective Study. *BMC Pregnancy and Childbirth*, **20**, Article No. 483. <https://doi.org/10.1186/s12884-020-03173-7>
- [7] Garde, I., Paredes, C., Ventura, L., Pascual, M.A., Ajossa, S., Guerriero, S., et al. (2023) Diagnostic Accuracy of Ultrasound Signs for Detecting Adnexal Torsion: Systematic Review and Meta-Analysis. *Ultrasound in Obstetrics & Gynecology*, **61**, 310-324. <https://doi.org/10.1002/uog.24976>
- [8] Bridwell, R.E., Koymfman, A. and Long, B. (2022) High Risk and Low Prevalence Diseases: Ovarian Torsion. *The American Journal of Emergency Medicine*, **56**, 145-150.

- <https://doi.org/10.1016/j.ajem.2022.03.046>
- [9] Cathcart, A.M., Nezhat, F.R., Emerson, J., Pejovic, T., Nezhat, C.H. and Nezhat, C.R. (2023) Adnexal Masses during Pregnancy: Diagnosis, Treatment, and Prognosis. *American Journal of Obstetrics and Gynecology*, **228**, 601-612. <https://doi.org/10.1016/j.ajog.2022.11.1291>
- [10] Cagino, K., Li, X., Thomas, C., Delgado, D., Christos, P. and Acholonu, U. (2021) Surgical Management of Adnexal Masses in Pregnancy: A Systematic Review and Meta-Analysis. *Journal of Minimally Invasive Gynecology*, **28**, 1171-1182.e2. <https://doi.org/10.1016/j.jmig.2021.01.020>
- [11] Tompeen, I., Kiar, C.G.A., Ebong, C., Yaneu, J.N., Meka, E.N.U. and Ndoua, C.C.N. (2025) Feasibility and Safety of Laparoscopy in Pregnancy in Yaoundé, Cameroon. *Open Journal of Obstetrics and Gynecology*, **15**, 679-687. <https://doi.org/10.4236/ojog.2025.154056>
- [12] Kumar, S.S., Collings, A.T., Wunker, C., Athanasiadis, D.I., DeLong, C.G., Hong, J.S., et al. (2024) SAGES Guidelines for the Use of Laparoscopy during Pregnancy. *Surgical Endoscopy*, **38**, 2947-2963. <https://doi.org/10.1007/s00464-024-10810-1>
- [13] Pearl, J.P., Price, R.R., Tonkin, A.E., Richardson, W.S. and Stefanidis, D. (2017) SAGES Guidelines for the Use of Laparoscopy during Pregnancy. *Surgical Endoscopy*, **31**, 3767-3782. <https://doi.org/10.1007/s00464-017-5637-3>
- [14] Collinet, P., Ballester, M., Fauconnier, A., Deffieux, X. and Pierre, F. (2010) Les risques de la voie d'abord en coelioscopie. *Journal de Gynécologie Obstétrique et Biologie de la Reproduction*, **39**, S123-S135. [https://doi.org/10.1016/s0368-2315\(10\)70039-9](https://doi.org/10.1016/s0368-2315(10)70039-9)
- [15] Sawyer, H.R. (1995) Structural and Functional Properties of the Corpus Luteum of Pregnancy. *Journal of Reproduction and Fertility. Supplement*, **49**, 97-110.