

Femuroacetabular Mixed Impingement with Anterolateral Chondrolabral Lesion and Periarticular Tenosynovial Giant Cell Tumor in the Right Psoas Compartment

—A Case Report

Stephanie Windemuth, Richard Herzog

Department of Orthopedics and Trauma Surgery, Lucerne Cantonal Hospital, Wolhusen, Switzerland

Email: stephanie.windemuth@luks.ch

How to cite this paper: Windemuth, S. and Herzog, R. (2026) Femuroacetabular Mixed Impingement with Anterolateral Chondrolabral Lesion and Periarticular Tenosynovial Giant Cell Tumor in the Right Psoas Compartment. *Open Journal of Orthopedics*, 16, 160-164.

<https://doi.org/10.4236/ojo.2026.163016>

Received: February 2, 2026

Accepted: March 28, 2026

Published: March 31, 2026

Copyright © 2026 by author(s) and Scientific Research Publishing Inc. This work is licensed under the Creative Commons Attribution International License (CC BY 4.0).

<http://creativecommons.org/licenses/by/4.0/>



Open Access

Abstract

Tenosynovial giant cell tumor (TGCT) is a fibrohistiocytic, typically benign tumor deriving from the synovia and hemosiderin deposition. Any joint can be affected and symptoms are unspecific like joint pain, swelling and stiffness. There are different treatment methods, however the standard therapy is early surgical resection. We describe a case, where a 23-year-old patient suffered from a cam-emphasized mixed impingement with a labral tear, and therefore received a hip arthroscopy performing an extracapsular approach. Incidental findings in the MRI showed an unknown periarticular tumor in the right psoas compartment—later identified as TGCT, which was simultaneously resected arthroscopically in toto. Our case report shows, that even relatively big, extraarticular, benign lesions can be resected endoscopically, which offers a great minimal invasive alternative compared to open surgery to minimize postoperative immobilisation and pain.

Keywords

Tenosynovial Giant Cell Tumor (TGCT), Hip Arthroscopy, Femoroacetabular Impingement, Labral Tear, Case Report

1. Introduction

Tenosynovial giant cell tumor is a so-called fibrohistiocytic and typically benign tumor deriving from the synovium of joints, tendon sheaths and bursae and is characterized by hyperplasia of the synovia and hemosiderin deposition [1] [2].

TGCTs are divided into two subgroups: localized (formerly giant cell tumor of tendon sheath, nodular tenosynovitis) and diffuse (formerly pigmented villonodular sclerosis, tenosynovitis, fibrous xanthoma of synovium) [1]. Approximately 90% of TGCTs are localized and involve the joint, bursa and tendon sheaths, while the diffuse form mostly appears intraarticular [3] [4]. Any joint can be affected, however, the localized form mostly affects small joints as the hand and wrist, followed by knee, whereas the diffuse form more likely affects big joints, like the knee followed by the ankle and hip [5].

2. Symptoms, Signs, Diagnostics

Clinical presentation shows no distinctive clinical manifestation. The median duration of symptoms till diagnosis lies between ten months to three years. Symptoms differ among patients and between the related type of tumor, intra- or extra-articular location and the affected joint [1]. TGCT affects mostly young patients and, although usually not lethal, often restricts the quality of life by the cause of substantial morbidity [5]. Symptoms include joint pain, swelling or a painful soft-tissue mass [3], and in case of diffuse TGCT hemarthrosis or bone and cartilage destruction with severe disability are common [5].

The preferred imaging technique for detection and characterization of TGCT is magnetic resonance imaging (MRI), as well as for follow-up imaging, and preferably in combination with Gadolinium contrast administration [5].

3. Treatment

Nowadays treatment for TGCT includes surgical excision, radiation, and systemic targeted therapy [6]. After discovering an overexpression of colony-stimulating factor 1 (CSF-1) in TGCT, recent studies focus on developing selective tyrosine kinase inhibitors targeting these CSF-1 receptors [6]. But still, early surgical resection is the standard therapy to reduce articular destruction and the recurrence rate [4]. Treatment depends on the extent of joint involvement. The localized form of TGCT has macroscopically well-identified and sharp marginal layers, which allows for complete surgical resection and a recurrence rate of only 0 - 15% [6]. However, the diffuse TGCT lacks these well-defined margins, leading to a more challenging resection and a higher recurrence rate of 14% - 55% [6], therefore an extensive synovectomy is recommended [5].

4. Case Report

A 23-year-old female patient was suffering from progredient pain in the right groin, mostly exercise-related but also at rest. Nighttime awakenings due to pain did not occur. Two years before, she received a hip arthroscopy due to cam-emphasized mixed impingement with a labral tear (12 o'clock) on the contralateral site and presented symptom-free ever since.

She worked full time as a saleswoman and in her free time, she enjoyed sporting activities such as running and going to the gym. As a teenager she used to play

volleyball.

Clinical examination showed a limited flexion/extension of the right hip of 100/0/20° (left 120/0/30°) as well as limited outer and internal rotation of 45/0/15° in supine position (left 50/0/30°), whereas tested in prone position outer and internal rotation was symmetrical to the left site with a range of 20/0/40°. Abduction/adduction was symmetrical with a range of 45/0/30°. Impingement-test was positive on the right hip joint.

A conventional x-ray of the right hip showed a preserved joint gap and a slight crossing sign (<30%), as well as a herniation pit in Dunn-projection. Additional imaging via Arthro-MRI showed an acetabular retroversion and flattening of the femoral offset with an alpha angle of 60°, as well as a labral tear at 9 - 12 o'clock. Incidental findings included an unclear lesion inside of the iliopsoas muscle reaching to the anterior joint capsule with a size of 18 × 18 × 30 mm (**Figures 1(A)-(D)**). The lesion showed a similar intensity as muscle tissue with a sharp hypointense margin. Suspected diagnoses arising from the MRI included nodular fasciitis, atypical iliopsoas ganglion, soft tissue tumor and chondroma.

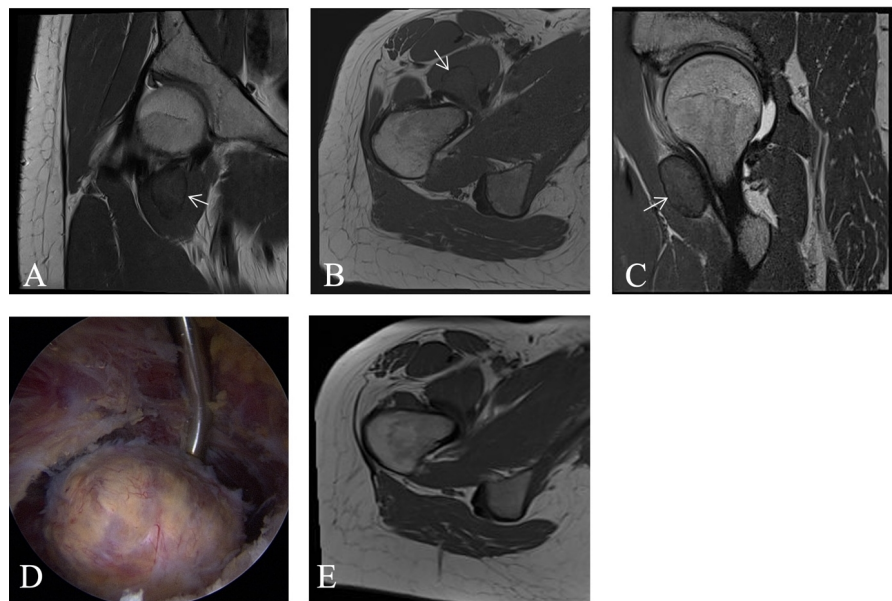


Figure 1. Preoperative MRI of the right hip in coronar (A), transversal (B) and sagittal (C) plane. Arrow marking the TGCT in (A)-(C). D: Arthroscopic view into the psoas compartment imaging the dissected tumor. E: Postoperative MRI of the right hip in transversal plane showing no tumor recurrence 3 years after surgery.

Conclusively, diagnostics of this patient discovered a femuroacetabular mixed impingement with an anterolateral labral tear and an unknown periarticular tumor in the right psoas compartment. Because of a crossing sign of nearly 30° a pelvic osteotomy should be discussed. Alternatively, a light pincer reduction with a stronger compensatory offset correction could be performed, as our patient received already at the contralateral side with high postoperative satisfaction.

Therapeutically our patient received a hip arthroscopy performing our usual

extracapsular approach (Minimally Invasive Capsulotomy in Hip Arthroscopy [7]), allowing endoscopic visualization of the well-defined, yellowish firm tumor. In a slight flexed position of the hip, the tumor could be mobilized in toto using a radio frequency device while protecting healthy muscle tissue. After performing a standard hip arthroscopy with pincer reduction, labral fixation and offset-correction, the tumor was en-bloc removed over an expansion of the anterolateral portal (**Figure 1(D); Figure 2**).

Histological examination identified multiple foam cells, histiocytes and multinucleated giant cells, compatible with a giant cell tumor arising from the joint or tendon sheath (tenosynovial giant cell tumor). There were no signs of malignancy.

Follow-ups five months and two years after surgery showed a free range of motion and negative impingement tests in clinical examination. The patient presented pain free. The soft tissue appeared unremarkable. Follow-up x-rays and MRIs showed a proper impingement correction and no tumor recurrence (**Figure 1(E)**).

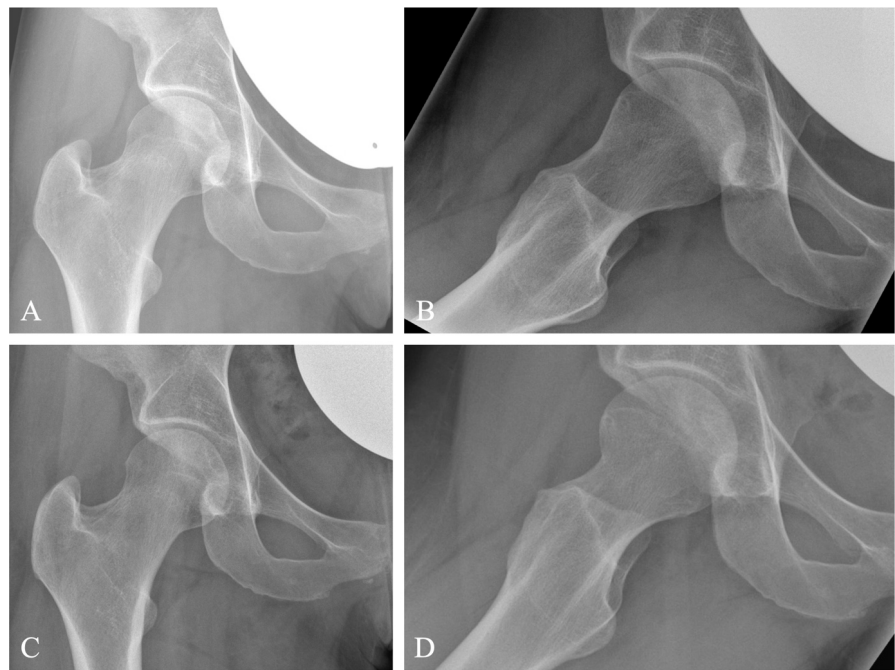


Figure 2. (A), (B): Preoperative x-rays of the right hip in ap (A) and axial projection (B). (C), (D): Postoperative x-rays after arthroscopic offset correction in ap (C) and axial (D) projection.

5. Discussion and Conclusion

Nowadays, in every specialty, more and more minimal invasive operative techniques are established. With our case report, we want to demonstrate, that endoscopic resection can be a good minimal invasive option for the complete resection even of relatively big, extraarticular benign lesions of the hip. This bears a great minimally invasive option for patients and preserves a faster recovery than open surgery. Our patient suffered of a localized giant cell tumor, which is a benign

tumor. In cases of malignity, open surgery might be nevertheless necessary because of the risk of spread and non-sufficient R0 excision by endoscopic surgery.

Conflicts of Interest

The authors declare no conflicts of interest regarding the publication of this paper.

References

- [1] Kager, M., Kager, R., Fałek, P., Fałek, A., Szczypiór, G., Niemunis-Sawicka, J., Rzepecka-Wejs, L., Starostawska, E. and Burdan, F. (2022) Tenosynovial Giant Cell Tumor. *Folia Medica Cracoviensia*, **62**, 93-107. <https://doi.org/10.24425/fmc.2022.141702>
- [2] Sbaraglia, M., Bellan, E. and Dei Tos, A.P. (2020) The 2020 WHO Classification of Soft Tissue Tumours: News and Perspectives. *Pathologica*, **113**, 70-84. <https://doi.org/10.32074/1591-951X-213>
- [3] Robert, M., Farese, H. and Miossec, P. (2022) Update on Tenosynovial Giant Cell Tumor, an Inflammatory Arthritis with Neoplastic Features. *Frontiers in Immunology*, **13**, Article 820046. <https://doi.org/10.3389/fimmu.2022.820046>
- [4] Noailles, T., Brulefert, K., Briand, S., *et al.* (2017) Giant Cell Tumor of Tendon Sheath: Open Surgery or Arthroscopic Synovectomy? A Systematic Review of the Literature. *Orthopaedics & Traumatology: Surgery & Research*, **103**, 809-814. <https://doi.org/10.1016/j.otsr.2017.03.016>
- [5] Stacchiotti, S., Dürr, H.R., Schaefer, I.M., *et al.* (2023) Best Clinical Management of Tenosynovial Giant Cell Tumour (TGCT): A Consensus Paper from the Community of Experts. *Cancer Treatment Reviews*, **112**, Article 102491. <https://doi.org/10.1016/j.ctrv.2022.102491>
- [6] Chan, A.S., Katiyar, V., Dy, P. and Singh, V. (2023) Updates on the Treatment of Tenosynovial Giant Cell Tumor. *Hematology/Oncology and Stem Cell Therapy*, **16**, 307. <https://doi.org/10.56875/2589-0646.1032>
- [7] Forster-Horvath, C., Domb, B.G., Ashberg, L. and Herzog, R.F. (2017) A Method for Capsular Management and Avoidance of Iatrogenic Instability: Minimally Invasive Capsulotomy in Hip Arthroscopy. *Arthroscopy Techniques*, **6**, e397-e400. <https://doi.org/10.1016/j.eats.2016.10.015>