

Approach in Treating Pathologic Femoral Neck Fractures with Distal Shaft Lesion, Using Hip Arthroplasty Stem and Küntscher Nail Extension

Jose Gabriel Barcelon, Rapin Phimolsarnti

Department of Health, East Avenue Medical Center, Quezon City, Republic of the Philippines

Email: jgpbarcelon@gmail.com

How to cite this paper: Barcelon, J.G. and Phimolsarnti, R. (2025) Approach in Treating Pathologic Femoral Neck Fractures with Distal Shaft Lesion, Using Hip Arthroplasty Stem and Küntscher Nail Extension. *Open Journal of Orthopedics*, 15, 421-429. <https://doi.org/10.4236/ojo.2025.1511043>

Received: October 7, 2025

Accepted: November 25, 2025

Published: November 28, 2025

Copyright © 2025 by author(s) and Scientific Research Publishing Inc. This work is licensed under the Creative Commons Attribution International License (CC BY 4.0).

<http://creativecommons.org/licenses/by/4.0/>



Open Access

Abstract

This case series presents a novel approach for treating pathologic femoral neck fractures with distal shaft lesions using a cemented bipolar hemiarthroplasty stem augmented with a Küntscher nail extension. Two patients with metastatic disease and complex fractures underwent this procedure. Both demonstrated improved mobility and pain relief postoperatively. This technique offers a promising strategy for achieving fracture healing and functional restoration in challenging clinical scenarios. Further research is warranted to evaluate long-term outcomes and comparative effectiveness.

Keywords

Pathologic Fracture, Femoral Neck Fracture, Hemiarthroplasty, Küntscher Nail, Metastatic Disease, Combined Fixation

1. Introduction

Pathologic fractures of the femur, especially those occurring in the neck region, pose significant treatment challenges, particularly when accompanied by lesions that compromise bone integrity. Traditional methods of fixation often fail to offer sufficient stabilization in these complex cases, leading to high rates of failure and reoperation.

In this case series, we detail the innovative use of a femoral arthroplasty stem combined with a Küntscher nail extension in two patients (58 and 51-year-old females) with a pathologic neck fracture and a distal shaft lesion, both with associated multiple metastatic lesions and comorbidities.

This approach not only addressed the immediate mechanical needs for stabilizing the fracture but also enhanced the overall structural support of the compromised femur, aiming for improved functional outcomes and patient quality of life.

2. Case Presentation

Case 1: A 58-year-old female patient with a history of breast carcinoma presented with a pathological fracture of the left femur due to metastatic disease. She also presented with advanced stage CA breast with bone, bone marrow, liver and brain metastasis. The patient underwent a long stem cemented bipolar hemiarthroplasty utilizing an Exeter Küntscher nail stem (Exeter offset 33, Head 40, ID 28, Offset 0, K-nail 90 mm) to manage the fracture and address the associated metastatic lesions. Given the extent of bone destruction and the patient's overall condition, bipolar hemiarthroplasty was chosen over total hip arthroplasty to minimize surgical time and potential complications. The operation was executed without complications.

Following the surgery, the patient displayed significant improvement in mobility and pain relief. Pre-operative VAS pain score was 8/10; post-operative at 1 month was 3/10. Her pre-operative Harris Hip Score was 35, improving to 62 at the 1-month follow-up. At the time of discharge, the results of treatment indicated enhanced functional outcomes, allowing the patient to ambulate with minimal assistance. The prognosis was positive, with plans for regular follow-up appointments for monitoring and ongoing management of her metastatic disease.

This case emphasizes the complexities of treating pathologic fractures in the context of metastatic breast cancer and illustrates the success of cemented bipolar hemiarthroplasty and Küntscher nail extender as a beneficial intervention, restoring early mobility and function (**Figures 1-7**).

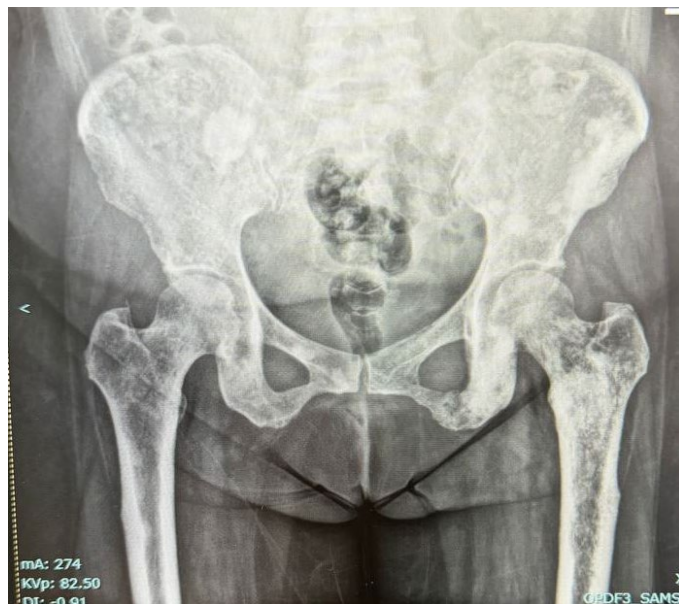

Figure 1. Pelvis AP X-ray noting lytic lesion on bilateral proximal femur and pelvis.

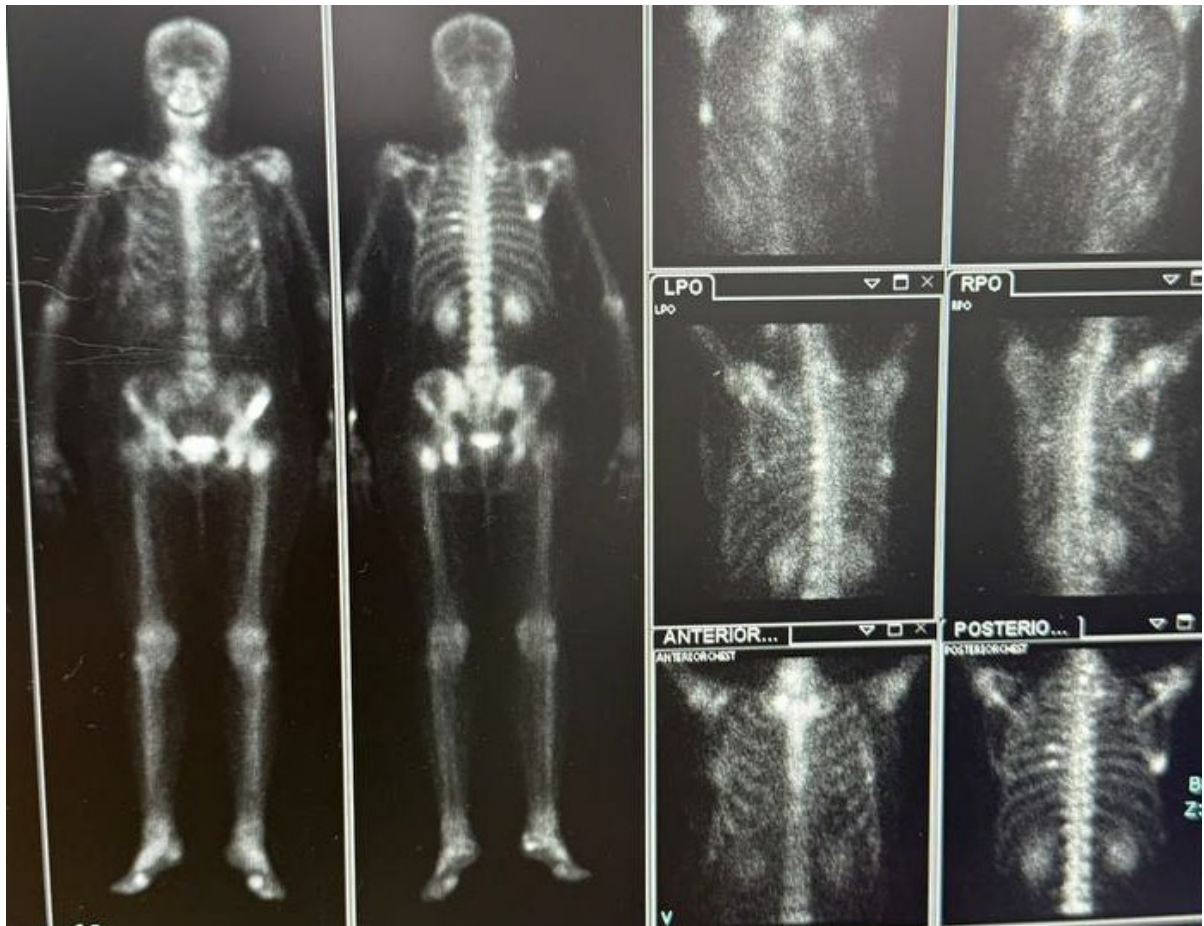


Figure 2. Bone scan increase uptake on proximal left femur, pelvis, and chest.

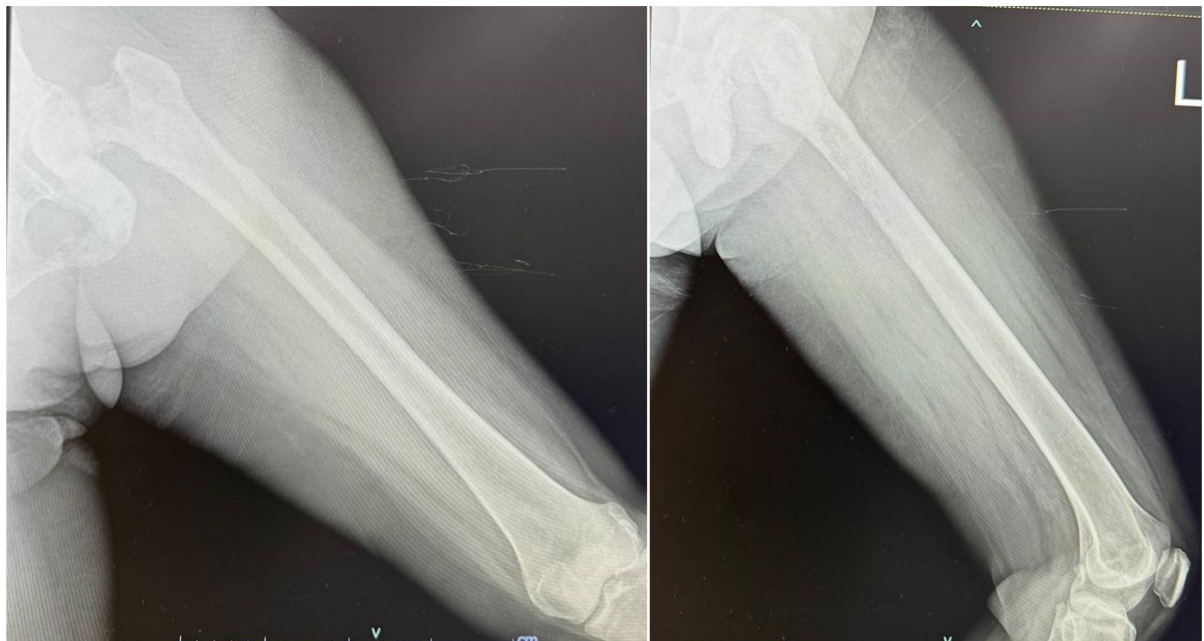

Figure 3. Thigh AP and lateral view X-rays noting on follow up noting pathologic fracture of the left femoral neck with lysis on the mid-distal aspect of the femur.

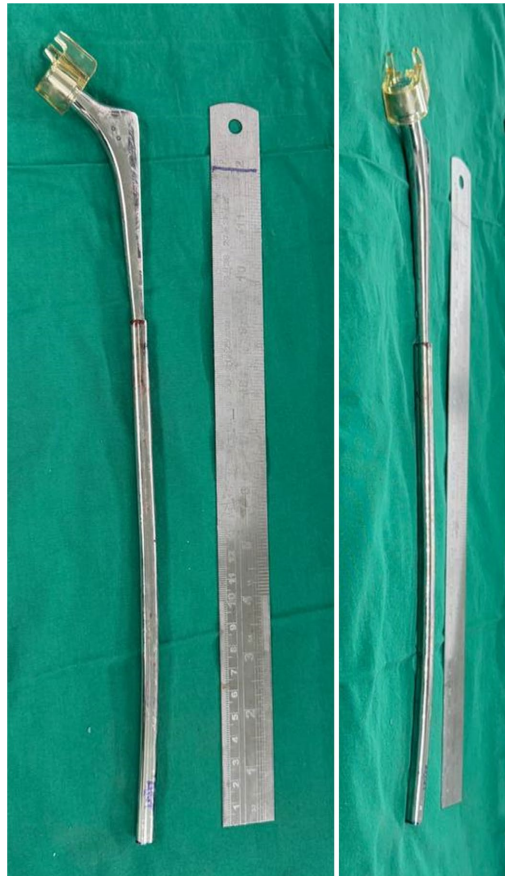

Figure 4. Improved PHA stem with K-nail attachment.

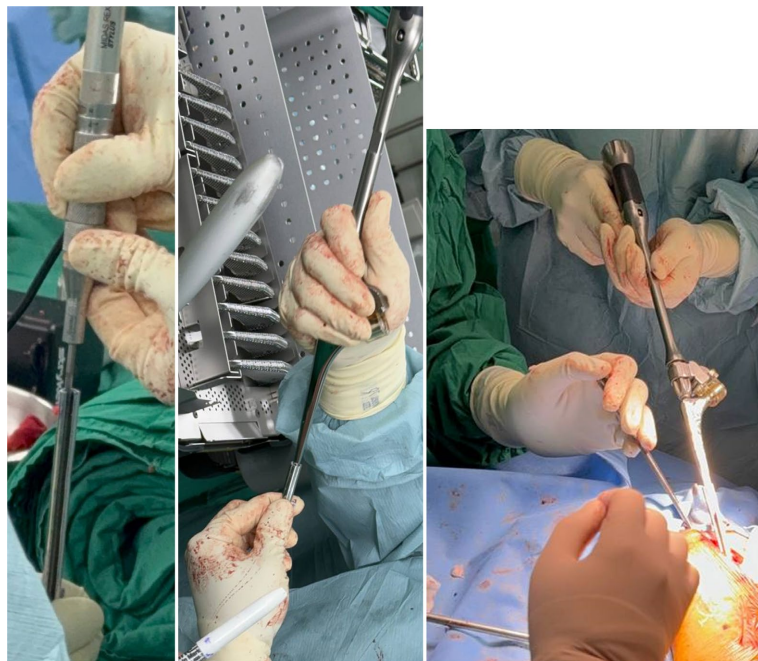


Figure 5. Step 1 - 3 showing Küntscher nail preparation utilizing a high-speed burr in properly sizing the entry point of the distal PHA stem up to nail insertion with the standard nailing techniques.

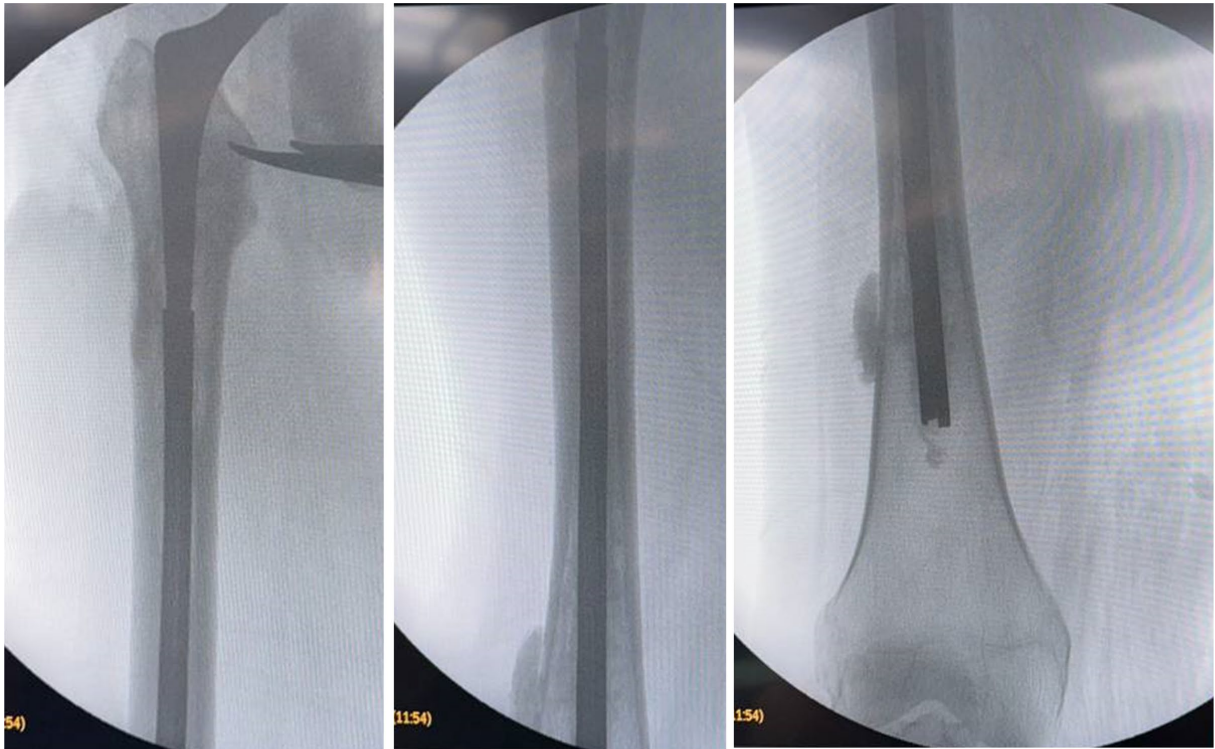

Figure 6. Cementation and implant application with imaging showing distal reach of the implant.

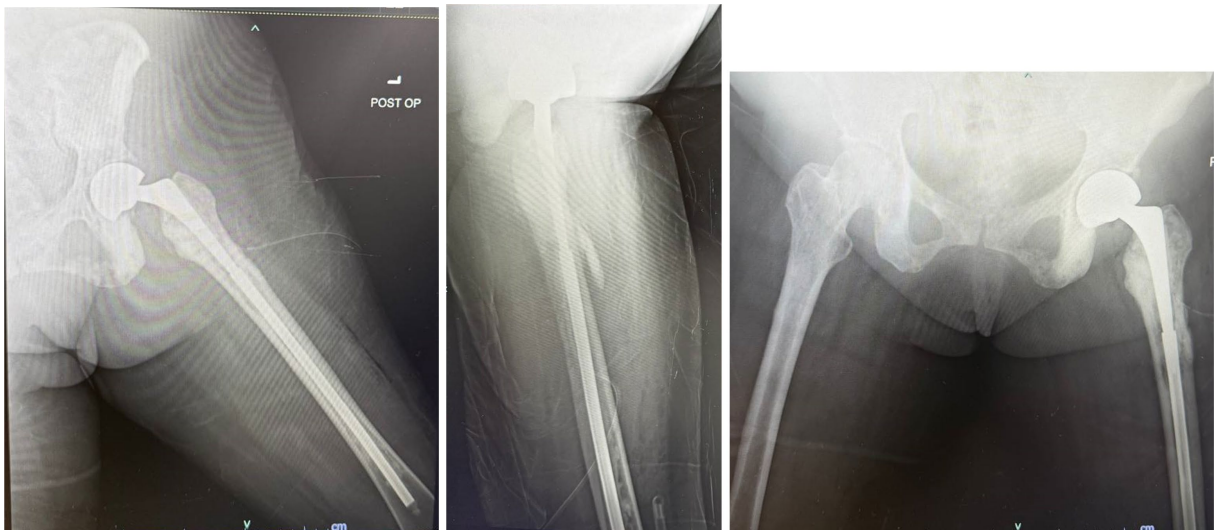


Figure 7. Post-operative X-rays showing good implant length obtained with the technique.

Case 2: A 51-year-old female patient with a history of advanced stage breast carcinoma presented with severe left hip pain, subsequently diagnosed as a pathologic neck fracture of the left femur. Comprehensive assessment revealed multiple bone metastasis, spinal metastasis T10, L1 - L4, skull, sacrum, both pelvis, humerus, both femur, manubrium, sternum, and multiple bilateral ribs. Due to persistence of pain on the left hip and noted pathologic fracture, the patient underwent a cemented bipolar hemiarthroplasty, incorporating an extended Küntscher nail.

Given the patient's diffuse metastatic disease and compromised bone quality, bipolar hemiarthroplasty was deemed preferable to total hip arthroplasty to reduce operative time and the risk of complications. The procedure utilized a 25/36 head and a 50 mm stem fixed to a Küntscher nail extension to address both the pathologic fracture and aiding in the structural integrity of the entire femur which showed bony metastasis. Operative time was 85 minutes, with an estimated blood loss of 250 ml.

Remarkably, at the first month follow-up, the patient was able to ambulate with a 4 point walker, demonstrating significant progress in mobility and recovery. Pre-operative VAS pain score was 9/10, improving to 4/10 at 1 month. Her pre-operative Harris Hip Score was 30, increasing to 58 at the 1-month follow-up (**Figure 8** and **Figure 9**).

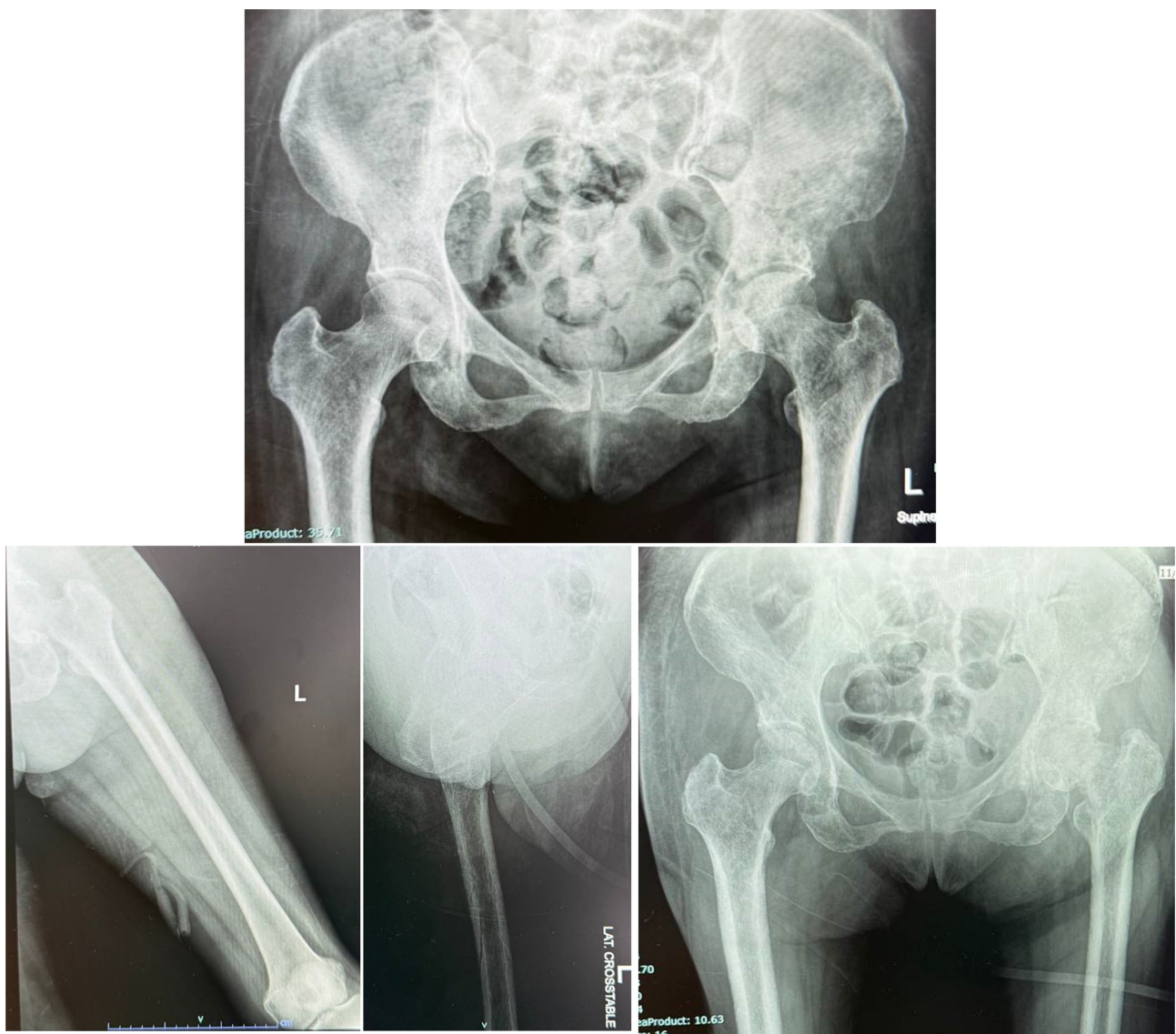


Figure 8. Plain X-rays films on first check up and subsequent follow up of the patient showing a pathologic neck fracture of the left femur.

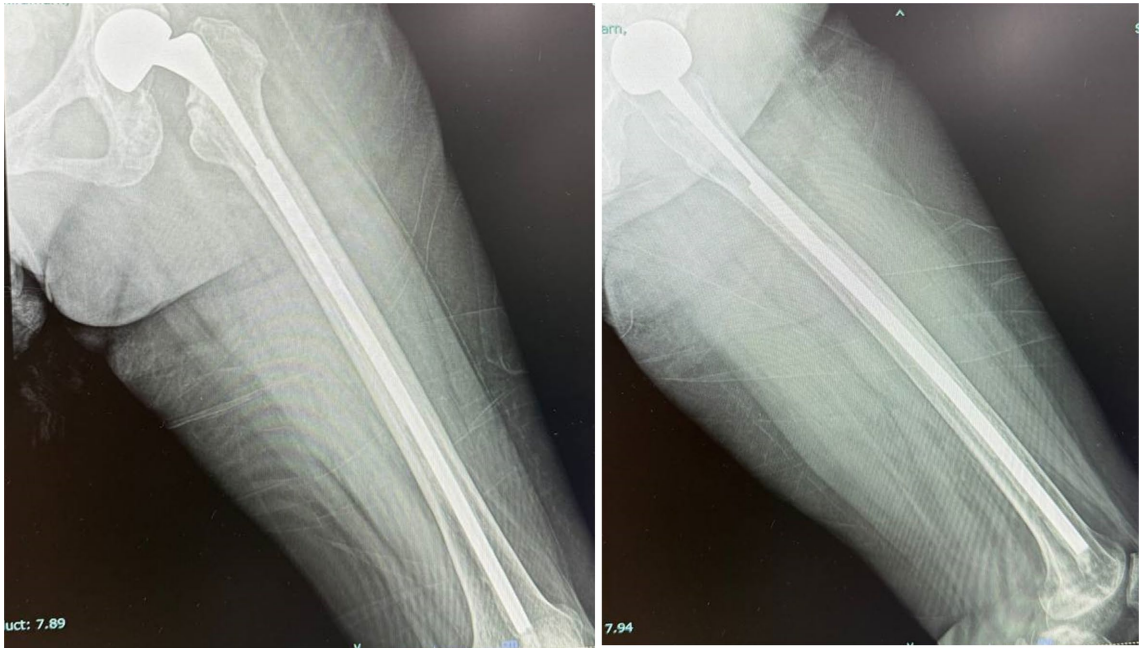

Figure 9. Post-operative X-rays films showing good implant length obtained with the technique.

3. Discussion

Pathologic fractures of the femoral neck with distal shaft metastasis present a significant surgical challenge, demanding innovative orthopedic strategies to address both the femoral neck fracture and oncologic concerns regarding bone integrity due to malignancy. The cases presented successful management and outcomes by using a cemented bipolar hemiarthroplasty stem augmented with an extended Küntscher nail.

The decision to utilize an extended nail technique stems from the need to use specific implants such as the bipolar hemiarthroplasty stem due to the femoral neck fracture and reinforce this with a longer device due to its lack in length. Historically, Küntscher nails were utilized for almost every fracture type [1], over the years, Küntscher tried to develop an own nail for every possible fracture type and ultimately combining this approach with the traditional hip arthroplasty stems mitigates the risk of implant loosening and subsequent failure, often observed with traditional long stems in total hip arthroplasties (THA) that are used in compromised femoral canals.

While THA is a common treatment for femoral neck fractures, the extensive bone destruction present in these cases necessitated a more tailored approach. Hemiarthroplasty, combined with the extended Küntscher nail, offered a customized solution addressing both the fracture and the compromised bone structure. This approach minimizes surgical time and tissue trauma, crucial factors in this context considering the patient's significant underlying oncologic burden. The literature indicates that utilizing modified implants can be highly beneficial in complex femoral reconstructions [2].

The decision to use the Küntscher nail extension was based on a combination

of factors including the location and size of the distal lesion, the overall bone quality as assessed on pre-operative radiographs and bone scans, and a Mirels' score greater than 8, indicating a high risk of further fracture.

However, it is important to note the lack of studies specifically evaluating this combined technique, the use of an extended Küntscher nail in conjunction with a hemiarthroplasty, for the management of pathologic femoral fractures. These cases, therefore, contribute valuable clinical data to this relatively unexplored area.

The patient's ability to ambulate postoperatively at the first month follow-up underscores the effectiveness of this combined approach in achieving both fracture healing and functional recovery. This successful outcome aligns with successful outcomes reported in similar cases using unconventional techniques [3], demonstrating that a well-planned, customized approach can lead to significant improvements in patient mobility and quality of life. Moreover, the successful use of the extended Küntscher nail aligns with observations in previously reported cases using similar augmentation techniques for structural support in cases of significant bone loss [4] [5]. The lack of substantial research focusing on this specific combination for pathologic fractures further emphasizes the significance of this study in expanding our understanding of effective treatment strategies.

4. Conclusions

This case underscores the value of integrating established orthopedic techniques, such as the use of Küntscher nails, with modern arthroplasty approaches in managing complex pathological fractures with distal site metastasis. The successful outcome highlights the potential of this technique and contributes valuable data to the limited body of literature describing innovative approaches for managing such complex fractures. This combined technique offers a promising strategy for achieving both fracture healing and functional restoration in challenging clinical scenarios. Further research, particularly studies focusing on the long-term outcomes and comparative effectiveness of this technique compared to other established methods for pathologic fractures, is warranted to solidify its role in clinical practice.

5. Limitations

This study is limited by its small sample size (two patients) and the short follow-up duration (1 month). The absence of a control group makes it difficult to definitively conclude that the described technique is superior to other treatment options. Further, the subjective nature of pain scores and functional assessments should be considered when interpreting the results.

Conflicts of Interest

The authors declare no conflicts of interest regarding the publication of this paper.

References

- [1] Vécsei, V., Hajdu, S. and Negrin, L.L. (2011) Intramedullary Nailing in Fracture

Treatment: History, Science and Küntscher's Revolutionary Influence in Vienna, Austria. *Injury*, **42**, S1-S5. [https://doi.org/10.1016/s0020-1383\(11\)00419-0](https://doi.org/10.1016/s0020-1383(11)00419-0)

- [2] Wroblewski, B.M., Browne, A.O. and Hodgkinson, J.P. (1992) Treatment of Fracture of the Shaft of the Femur in Total Hip Arthroplasty by a Combination of a Küntscher Nail and a Modified Cemented Charnley Stem. *Injury*, **23**, 225-227. [https://doi.org/10.1016/s0020-1383\(05\)80002-6](https://doi.org/10.1016/s0020-1383(05)80002-6)
- [3] Behery, O.A., Kouk, S., Meftah, M. and Tejwani, N.C. (2020) Total Hip Arthroplasty for Femoral Neck Fracture in the Setting of Challenging Extraction of an Intramedullary Femoral Nail: A Case Report. *Journal of Orthopaedic Case Reports*, **10**, 85-89. <https://doi.org/10.13107/jocr.2020.v10.i09.1914>
- [4] Sharma, A., Jain, A. and Gupta, R. (2016). Use of a Cement-Loaded Küntscher Nail in First-Stage Revision Hip Arthroplasty for Massive Femoral Bone Loss Secondary to Infection: A Report of Four Cases. ResearchGate.
- [5] Goosen, J.H. and Van Hellemond, G.G. (2013) Primary Total Hip Arthroplasty with a Retained Intramedullary Femoral Nail. *Acta Orthopaedica Belgica*, **79**, 114-116.