Open Journal of Modern Neurosurgery, 2024, 14, 256-266
https://www.scirp.org/journal/ojmn
ISSN Online: 2163-0585
ISSN Print: 2163-0569

Implementing P-15/ABM Bone Graft as a Standardized Technique for Lumbar Fusion Approaches

Diana Chávez Lizárraga, Jesús Alberto Pérez Contreras, Emmanuel Cantú Chávez, Ana Sofía Peña Blesa

Angeles del Pedregal Hospital, Ciudad de México, México
Email: diancha@gmail.com

How to cite this paper: Lizárraga, D.C., Contreras, J.A.P., Chávez, E.C. and Blesa, S.P. (2024) Implementing P-15/ABM Bone Graft as a Standardized Technique for Lumbar Fusion Approaches. *Open Journal of Modern Neurosurgery*, **14**, 256-266.
https://doi.org/10.4236/ojmn.2024.144027

Received: August 20, 2024
Accepted: September 23, 2024
Published: September 26, 2024

Copyright © 2024 by author(s) and Scientific Research Publishing Inc.
This work is licensed under the Creative Commons Attribution International License (CC BY 4.0).
http://creativecommons.org/licenses/by/4.0/
Open Access

Abstract

Introduction: Lumbar fusion as low back pain treatment continues to be a challenge because of the multiple techniques and materials available, most popular techniques include Transforaminal lumbar interbody fusion (TLIF), Lateral lumbar interbody fusion (LLIF) and Anterior lumbar interbody fusion (ALIF). Successful lumbar fusion is associated with better clinical outcomes, and it is enhanced and targeted through the use of bone graft materials as an osteogenic cell binding peptide P-15, bound to an anorganic bone mineral (ABM). This peptide improves bone formation when used in fixation devices in a targeted and limited way to the implant surface by activating osteoblast precursor cells; by the osteogenic, osteoinductive and osteoconductive stimuli. The main objective of this study is to standardize the lumbar fusion process in the 3 techniques and achieve a more efficient and predictable lumbar fusion, evaluating results with radiological and clinical scales. Material and Methods: Patients underwent lumbar fusion with the use of P-15 Osteogenic Cell Binding Peptide, bound to an anorganic bone mineral (P-15/ABM) bone graft (5 cc) in three different techniques (TLIF, LLIF, ALIF), achieving a total of 100 lumbar levels. Radiological outcomes included fusion rates per Hounsfield Units at computed tomography (CT) scan and Lenke scale. Clinical outcomes were evaluated via the Oswestry Disability Index (ODI), Short Form Performance (SPF-36) and Visual Analog Scale (VAS and VASs) for pain and satisfaction. Results: 67 patients completed the 12 months follow-up, showing no differences in fusion rates between techniques. (Computed Tomography Hounsfield Units) CTHU reaches more than 200 UH at 3 months follow-up and continues fusion process till 12-month follow-up. Clinical scales showed no disability at ODI, improvement at VAS and VASs scales, absence of health restrictions at SPF-36 score since 6 months follow up. Conclusion: Bone graft

volume of 5 cc is adequate for achieving successful lumbar fusion, regardless of the surgical technique employed.

Keywords

Lumbar Fusion, Spine Surgery, Bone Graft, Peptide p-15

1. Introduction

Multiple lumbar fusion techniques and materials are available for the treatment of lower back pain. The annual prevalence of lower back pain in the general adult population of the United States ranges from 10% to 30%, with a lifetime prevalence among American adults reaching 65% - 80%. The current challenge lies in selecting the appropriate technique for each patient and identifying the optimal materials, with the aim of providing patients with pain stability, restoration of lordosis, and correction of deformity. [1]

The techniques include Transforaminal Lumbar Interbody Fusion (TLIF), Lateral Lumbar Interbody Fusion (LLIF), and Anterior Lumbar Interbody Fusion (ALIF). TLIF offers unilateral disc access and potential direct monolateral decompression, reducing perineural scar tissue formation and enabling both interbody and posterolateral fusion. LLIF accesses the spine between the anterior vessels and psoas muscles, avoiding both structures to facilitate efficient disc space clearance and large interbody device application. This allows for distraction for foraminal decompression and endplate preparation for rapid, complete fusion. ALIF advantages include achieving a complete anterior discectomy under direct visualization, following anterior longitudinal ligament (ALL) resection, and inserting large, lordotic cages. [2]

Nowadays, successful lumbar fusion is associated with better clinical outcomes and is now enhanced and addressed through the use of bone graft materials. The selection of the bone graft used depends on clinical conditions and expected results. [3]

It has been demonstrated in vitro that P-15 Osteogenic Cell Binding Peptide, bound to an anorganic bone mineral (P-15/ABM) enhances cell attachment and provides an environment that allows cell migration, cell differentiation, and morphogenesis. The P-15 peptide can modulate cell number and tissue structure by improving viable cell attachment and regulating apoptosis. The P-15 sequence has been shown to accelerate the bone formation process on the surface of the inorganic bone matrix. This peptide has shown to improve bone formation when used in fixation devices or bone defects in a targeted manner, limited to the implant surface (ectopic bone growth), by activating osteoblast precursor cells. [4] [5]

The P-15 peptide sequence has been shown to accelerate the bone formation process on the surface of the inorganic bone matrix. This is a notable advancement, as current bone graft materials typically do not contain the cellular components

necessary to directly stimulate osteogenesis, or new bone formation. Rather, these existing materials merely provide an osteoconductive scaffold, serving as a base upon which new bone can grow. Osteoconduction refers to the ability of a material to support bone growth on its surface, without actively inducing the differentiation of osteogenic cells. The P-15 sequence represents a significant step forward in overcoming the limitations of traditional osteoconductive bone graft substitutes by directly promoting the bone formation process. [6]-[12]

It was known that the diameter and composition of these cages could influence the amount and distribution of bone graft material required. Therefore, consideration of the surgical approach and strategic placement of bone graft was necessary to optimize the chances of achieving lumbar fusion. [13]

The objectives of this study are to achieve faster and more efficient fusion using P-15/ABM bone graft, evaluate results using radiological and clinical scales, and determine the optimal amount of graft material required for successful lumbar fusion on any approach (TLIF, LLIF, ALIF).

By establishing a standardized approach, the aim is to enhance the consistency and efficacy of surgical interventions, optimize the lumbar fusion process, avoid excessive use of bone grafts, improve patient outcomes, minimize potential complications, and contribute to the advancement of spine procedures.

2. Materials and Methods

This is a prospective study, where information was obtained from the records and follow-ups of patients who underwent surgeries between May 2021 and August 2023 by a single surgeon. The surgeries used a total of 5 cc of p-15/ABM as bone graft at any technique. Patients were followed clinically and radiologically for 12 months, with their prior informed consent for the use of their information and follow-up data.

The inclusion criteria for this study are all patients undergone surgical procedures using p-15/ABM as bone graft utilizing the following techniques: TLIF, LLIF, ALIF. Participants must have completed comprehensive follow-up assessments at 3, 6 and 12 months, which included lumbar spine X-rays and computed tomography (CT) scans.

Exclusion criteria for this study are patients who have undergone previous lumbar revision procedures, who are not eligible, and any cases lacking a minimum of 1 year of clinical follow-up data will be excluded.

The surgical techniques employed in this study utilized a standardized amount of bone graft material. TLIF procedure involved the placement of 2.5 cc of graft within the intervertebral cage and an additional 2.5 cc of graft in the intersomatic space. The LLIF technique utilized 5 cc of graft material packed into the intervertebral cage. Similarly, the ALIF approach incorporated 5 cc of graft within the cage. (**Figure 1**)

The radiological outcomes were determined using the Lenke fusion scale and (Computed Tomography Hounsfield Units) CTHU with a cut-off point of >200

UH to define fusion. The clinical outcomes were assessed through the Oswestry Disability Index (ODI), the Short Form Performance (SPF-36) Health Questionnaire, and the visual analogue scale for pain and satisfaction (VAS, VASS).

Figure 1. Interbody implants for Transforaminal Lumbar Interbody Fusion (TLIF), Lateral Lumbar Interbody Fusion (LLIF), and Anterior Lumbar Interbody Fusion (ALIF) with standardized amount of bone graft material.

Statistical Analysis

We analyzed the parameters using Fisher's exact test, Pearson's correlation coefficient (r) for linear variables, and ANOVA for differences between groups of quantitative variables.

A p-value < 0.05 was considered statistically significant. All graphs, calculations, and statistical analyses were performed using GraphPad Prism software version 10.

3. Results

The present study evaluated a cohort of 67 patients who underwent lumbar fusion treatment using p-15/ABM as bone graft, with a total of 100 lumbar levels. Clinical and radiological assessments reveal the distribution of surgical techniques used, including ALIF (15 levels), TLIF (75 levels), and LLIF (10 levels).

Fusion rates exceeding 200 Hounsfield Units (HU) were observed in 91.29% of patients as early as 3 months post-operation, measured by simple lumbar spine computed tomography in **Figure 2**.

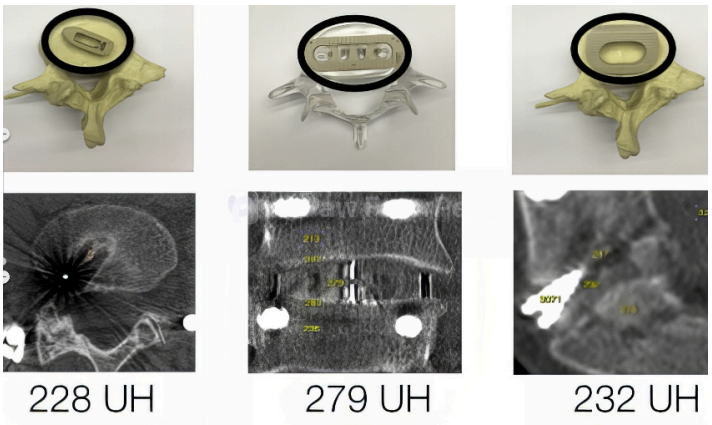

Figure 2. Examples of fusion rate at 3 months follow up measured by CT scan.

The progression of fusion showed that 100% of patients achieved more than 200 HU after 6 months, and a statistically significant p-value of 0.0036 at the 12-month follow-up in Figure 3.

This data suggests a high success rate in achieving bone fusion following the surgical procedure, with the majority of patients showing significant progress within the first three months and all patients reaching the desired fusion threshold by six months post-operation. The statistical significance at 12 months further supports the effectiveness of the treatment in promoting long-term fusion stability.

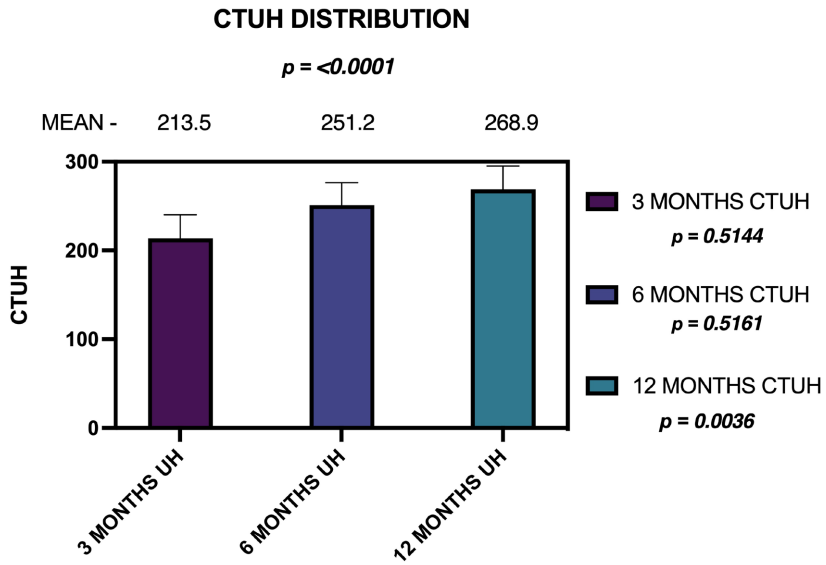

Figure 3. Distribution of Hounsfield Units in the 3-, 6- and 12-month follow-up on simple lumbar spine tomography.

Radiolucent images were observed in the implants and platforms that determine lumbar fusion on the Lenke scale, with solid fusion and frank consolidation (Lenke B) in 67.16% of patients at 3 months follow-up, solid fusion (Lenke A) in 40.29% of patients at 6 months follow-up, and 92.53% of patients at 12 months follow-up, showing a significant difference ($p \leq 0.0001$). There were no differences between surgical techniques employed ($p = 0.0704$) in relation to Hounsfield units in Figure 4 and Figure 5.

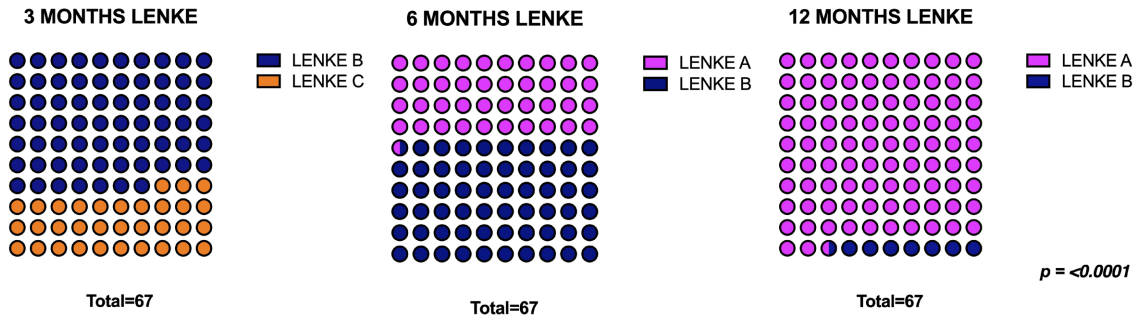

Figure 4. Distribution of lumbar fusion according to the Lenke scale at 3-, 6-, and 12-month follow-up.

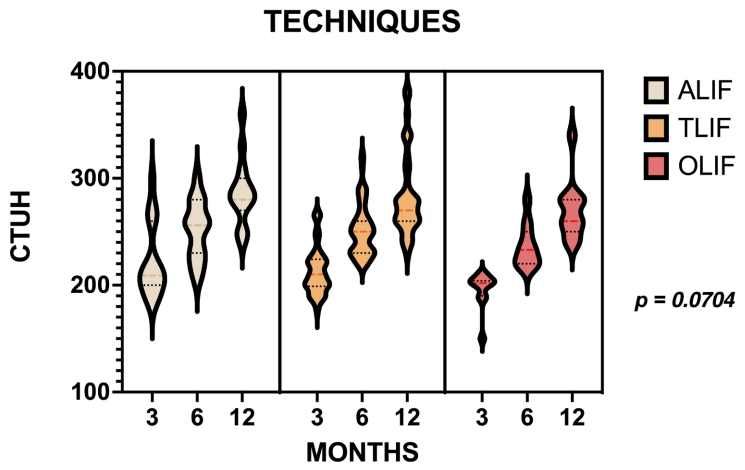

Figure 5. Correlation between techniques used and Hounsfield units with follow-up at 3-, 6- and 12-month.

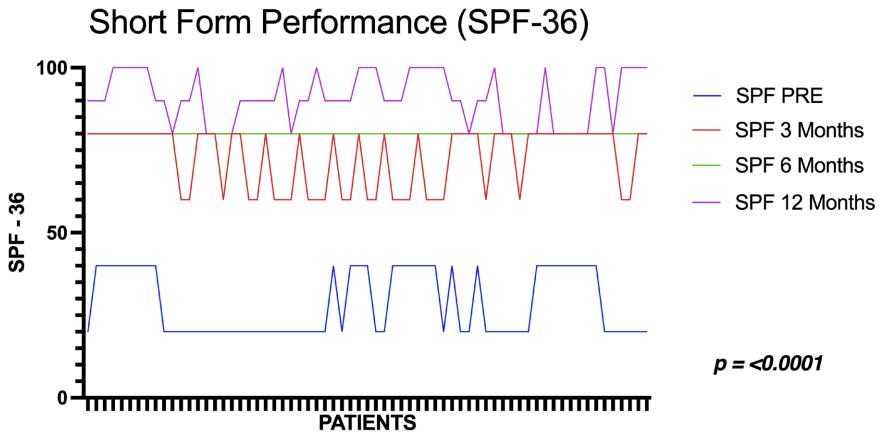

Figure 6. SPF-36 survey scores with follow-up at 3-, 6- and 12-month.

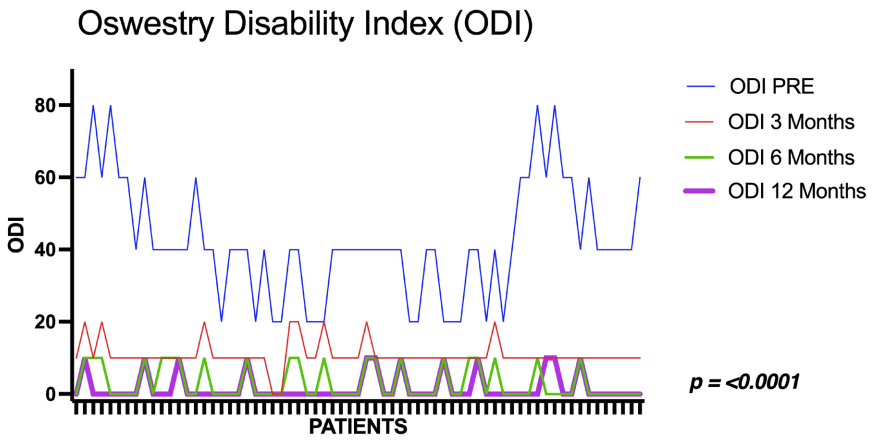

Figure 7. Percentages of functional limitation in the Oswestry disability index at 3-, 6- and 12-month.

Clinical results measured by pain and functionality scales have shown significant improvement in overall health status as assessed by the SPF-36 survey. Scores

increased by 40 to 60 points at the 6-month follow-up. At the ODI scale, the studied population was determined to have minimal functional limitation, which correlated with improvements in visual analog scales for pain and satisfaction from 3 months of follow-up onwards. These findings were statistically significant ($p < 0.0001$) in Figures 6-9.

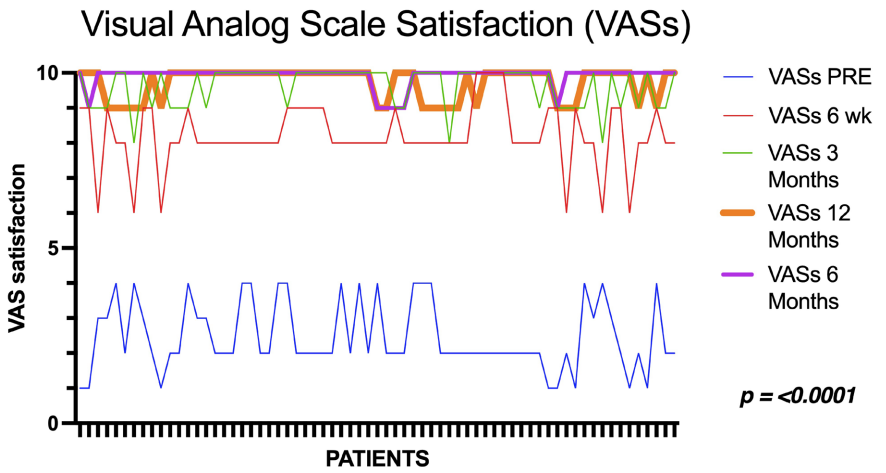

Figure 8. Visual analogue scale of satisfaction at follow-up at 6 weeks, 3-, 6- and 12-month.

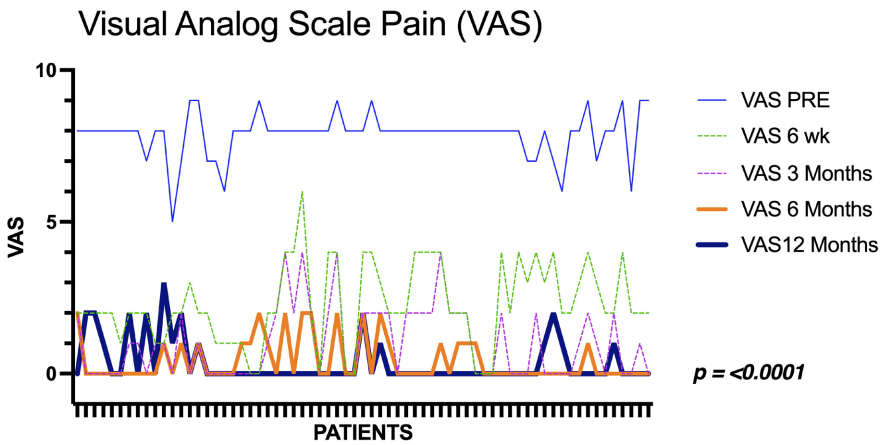

Figure 9. Visual analogue pain scale at 6 weeks, 3-, 6- and 12-month follow-up.

4. Discussion

Recent advancements in spinal surgery have significantly transformed the landscape of surgical procedures. The introduction of novel technologies, such as image-guided navigation and more sophisticated implants, has enabled surgeons to perform interventions with enhanced precision and minimize associated risks. These developments have led to improved patient outcomes and reduced recovery times. However, it is important to note that spinal fusion remains a critical aspect that is often overlooked and with different results depending on the technique and the combinations and quantities of grafts used.

A diverse array of bone graft options is available for utilization in medical

procedures. However, it is imperative to acknowledge that certain alternatives present significant challenges. For instance, the iliac crest graft, despite being a commonly employed technique, may entail considerable pain and morbidity for the patient. Similarly, autografts, while representing an autologous option, are frequently constrained by the quality and quantity of available osseous material. [14] [15]

Since its FDA approval in Mexico, P-15/ABM has been available in 1 cc, 2.5 cc, 5 cc, and 10 cc pouches. Our experience indicates that using less than 5 cc is insufficient to fill the cages adequately, whereas using more than 5 cc results in excessive graft material and waste.

What was observed in this generation of osteobiological agents, to which p-15/ABM belongs, indicates that they promote accelerated bone formation. The general consensus has been that more graft material is better; however, p-15/ABM can potentially cause reactions around neurological structures, inflammation, seromas, and ectopic bone formation. [16] [17] This study demonstrates that excessive use is not necessary and that we can reduce its indiscriminate application. These findings have important implications for clinical practice, suggesting that healthcare providers should carefully consider the appropriate amount of p-15/ABM to use in each individual case, rather than defaulting to larger quantities.

There exists a growing demand from patients to regain their quality of life and functional status more efficiently and with reduced impact. This patient-driven requirement presents a challenge for healthcare professionals, who must seek innovative solutions to meet these needs and expectations.

The results of this study indicate a positive trend in patient outcomes with notable improvements in both pain management and functional capacity, higher fusion rates, and shorter time. The SPF-36 survey results suggest a substantial boost in patients perceived health status, while the Oswestry Disability Index demonstrates that patients experienced only minimal functional limitations post-treatment. The improvement in pain and satisfaction scores, evident from the 3-month mark, further supports the effectiveness of the intervention.

Standardization of implementing p-15/ABM as a bone graft offers several key benefits. It provides a uniform approach that can be consistently applied, ensuring a more systematic and streamlined process. It is adaptable to various lumbar fusion techniques as needed. Minimizes differences in outcomes that may arise from the selection of graft materials. This consistency can lead to more reliable and predictable results. Furthermore, the standardization of lumbar fusion techniques may potentially reduce overall expenses by enabling economies of scale and eliminating the need for customized approaches.

This approach represents an important step in optimizing lumbar fusion procedures, potentially leading to improved patient outcomes and more efficient surgical practices. The future of grafting procedures is increasingly focused on gene therapies and genetic engineering techniques. [18] Specifically, the utilization of growth factors such as p-15/ABM has demonstrated promising potential as an

alternative method for enhancing lumbar fusion and, consequently, improving clinical outcomes. These therapeutic approaches, based on molecular biology, possess the potential to overcome the limitations associated with traditional grafting methods [19] [20], thereby offering more efficacious and personalized solutions for patients requiring spine fusion procedures.

As research and development in this field progresses, there will be increased use of these innovative therapies, which may result in improved success rates and enhanced quality of life for patients undergoing these procedures. We recommend implementing this bone graft in various spinal surgery centers. This strategy will include a diverse range of patients with different comorbidities and various surgeons, enabling us to assess whether the standardized use proposed in this study produces consistent clinical and radiological outcomes.

5. Conclusions

This study has established that a bone graft volume of 5 cc is adequate for achieving successful lumbar fusion, regardless of the surgical technique employed. The findings highlight the importance of this specific graft quantity in facilitating osseointegration and consolidation, which are essential for optimal clinical outcomes. Furthermore, the observed improvement in fusion rates over a 3 to 12-month period underscores the significance of monitoring patient progress post-surgery. With consistent results across various techniques when using p15/ABM, surgeons are encouraged to consider this option as a reliable choice for enhancing fusion success. Overall, these insights not only inform surgical practices but also contribute to advancing research in spinal surgery.

Conflicts of Interest

The authors declare that they have no conflict of interest in this work.

References

[1] Urits, I., Burshtein, A., Sharma, M., Testa, L., Gold, P.A., Orhurhu, V., *et al.* (2019) Low Back Pain, a Comprehensive Review: Pathophysiology, Diagnosis, and Treatment. *Current Pain and Headache Reports*, **23**, Article No. 23. https://doi.org/10.1007/s11916-019-0757-1

[2] Mobbs, R. (2011) Prospective Analysis of Graft Options for Anterior Lumbar Interbody Fusion (Alif): Fusion and Complication Rates. Spine Society of Australia.

[3] Khan, S.N. and Shahzad, H. (2023) Osteobiologics and Value-Based Care: Challenges and Opportunities. *International Journal of Spine Surgery*, **17**, S44-S52. https://doi.org/10.14444/8560

[4] Khan, S.N., Cammisa, F.P., Sandhu, H.S., Diwan, A.D., Girardi, F.P. and Lane, J.M. (2005) The Biology of Bone Grafting. *Journal of the American Academy of Orthopaedic Surgeons*, **13**, 77-86. https://doi.org/10.5435/00124635-200501000-00010

[5] Cheng, C.T., Vyas, P.S., McClain, E.J., Hoelen, T.A., Arts, J.J.C., McLaughlin, C., *et al.* (2024) The Osteogenic Peptide P-15 for Bone Regeneration: A Narrative Review of the Evidence for a Mechanism of Action. *Bioengineering*, **11**, Article 599. https://doi.org/10.3390/bioengineering11060599

[6] Axelsen, M.G., Overgaard, S., Jespersen, S.M. and Ding, M. (2019) Comparison of Synthetic Bone Graft ABM/P-15 and Allograft on Uninstrumented Posterior Lumbar Spine Fusion in Sheep. *Journal of Orthopaedic Surgery and Research*, **14**, Article No. 2. https://doi.org/10.1186/s13018-018-1042-4

[7] Sherman, B.P., Lindley, E.M., Turner, A.S., Seim III, H.B., Benedict, J., Burger, E.L., *z*. (2010) Evaluation of ABM/P-15 versus Autogenous Bone in an Ovine Lumbar Interbody Fusion Model. *European Spine Journal*, **19**, 2156-2163. https://doi.org/10.1007/s00586-010-1546-z

[8] Thorwarth, M., Schultze-Mosgau, S., Wehrhan, F., Kessler, P., Srour, S., Wiltfang, J., *et al*. (2005) Bioactivation of an Anorganic Bone Matrix by P-15 Peptide for the Promotion of Early Bone Formation. *Biomaterials*, **26**, 5648-5657. https://doi.org/10.1016/j.biomaterials.2005.02.023

[9] Yang, X.B., Bhatnagar, R.S., Li, S. and Oreffo, R.O.C. (2004) Biomimetic Collagen Scaffolds for Human Bone Cell Growth and Differentiation. *Tissue Engineering*, **10**, 1148-1159. https://doi.org/10.1089/ten.2004.10.1148

[10] Lauweryns, P. and Raskin, Y. (2015) Prospective Analysis of a New Bone Graft in Lumbar Interbody Fusion: Results of a 2-Year Prospective Clinical and Radiological Study. *International Journal of Spine Surgery*, **9**, Article 2. https://doi.org/10.14444/2002

[11] Mobbs, R.J., Maharaj, M. and Rao, P.J. (2014) Clinical Outcomes and Fusion Rates Following Anterior Lumbar Interbody Fusion with Bone Graft Substitute I-Factor, an Anorganic Bone Matrix/P-15 Composite. *Journal of Neurosurgery*: *Spine*, **21**, 867-876. https://doi.org/10.3171/2014.9.spine131151

[12] Zhang, Y., Lin, G., Zhang, J., Guo, J., Wang, S., Yang, Y., *et al*. (2016) Radiographic Evaluation of Posterior Selective Thoracolumbar or Lumbar Fusion for Moderate Lenke 5C Curves. *Archives of Orthopaedic and Trauma Surgery*, **137**, 1-8. https://doi.org/10.1007/s00402-016-2570-1

[13] Christensen, F.B. (2004) Lumbar Spinal Fusion: Outcome in Relation to Surgical Methods, Choice of Implant and Postoperative Rehabilitation. *Acta Orthopaedica Scandinavica*, **75**, 1-43. https://doi.org/10.1080/03008820410002057

[14] Sathe, A., Lee, S., Kim, S., Eun, S.S., Choi, Y.S., Lee, S., *et al*. (2022) Comparative Analysis of ABM/P-15, Bone Morphogenic Protein and Demineralized Bone Matrix after Instrumented Lumbar Interbody Fusion. *Journal of Korean Neurosurgical Society*, **65**, 825-833. https://doi.org/10.3340/jkns.2021.0296

[15] Yoo, J.S., Ahn, J., Patel, D.S., Hrynewycz, N.M., Brundage, T.S. and Singh, K. (2019) An Evaluation of Biomaterials and Osteobiologics for Arthrodesis Achievement in Spine Surgery. *Annals of Translational Medicine*, **7**, S168. https://doi.org/10.21037/atm.2019.06.80

[16] Malham, G.M., Louie, P.K., Brazenor, G.A., Mobbs, R.J., Walsh, W.R. and Sethi, R.K. (2022) Recombinant Human Bone Morphogenetic Protein-2 in Spine Surgery: Recommendations for Use and Alternative Bone Substitutes—A Narrative Review. *Journal of Spine Surgery*, **8**, 477-490. https://doi.org/10.21037/jss-22-23

[17] Greene, A.C. and Hsu, W.K. (2019) Orthobiologics in Minimally Invasive Lumbar Fusion. *Journal of Spine Surgery*, **5**, S11-S18. https://doi.org/10.21037/jss.2019.04.15

[18] Collon, K., Gallo, M.C. and Lieberman, J.R. (2021) Musculoskeletal Tissue Engineering: Regional Gene Therapy for Bone Repair. *Biomaterials*, **275**, Article ID: 120901. https://doi.org/10.1016/j.biomaterials.2021.120901

[19] Komar, A.A. (2023) Molecular Peptide Grafting as a Tool to Create Novel Protein Therapeutics. *Molecules*, **28**, Article 2383.

https://doi.org/10.3390/molecules28052383

[20] Hasan, S., Al-Jamal, M., Miller, A., Higginbotham, D.O., Cavazos, D.R., Waheed, M., *et al.* (2023) Efficacy and Outcome Measurement of iFactor/ABM/P-15 in Lumbar Spine Surgery: A Systematic Review. *Global Spine Journal*, **14**, 1422-1433. https://doi.org/10.1177/21925682231217253

Abbreviations

p-15: 15 amino acid peptide fragment
ABM: Anorganic Bone Mineral
TLIF: Transforaminal Lumbar Interbody Fusion
LLIF: Lateral Lumbar Interbody Fusion
XLIF: Extreme Lateral Interbody Fusion
OLIF: Oblique Lateral Interbody Fusion
ALIF: Anterior lumbar interbody fusion
CT: Computed Tomography
ODI: Oswestry Disability Index
SPF-36: Short Form Performance
VAS: Visual Analog Scale Pain
VASs: Visual Analog Scale Satisfaction
CTUH: Computed Tomography Hounsfield Units
ALL: Anterior Longitudinal Ligament