

# Correlation between Ultrasound Findings and Histological Data of Thyroid Nodules at Louga Regional Hospital

Hamidou Deme<sup>1,2\*</sup>, Cheikh Ahmadou Bamba Gueye<sup>1</sup>, Papa Amadou Mbaye<sup>1</sup>,  
Muhammad El Bachir Fall<sup>1</sup>, Aïcha Ndichout<sup>1</sup>, Ibrahima Diasse<sup>1</sup>, Ibrahima Faye<sup>1</sup>, Sokhna Ba<sup>2</sup>

<sup>1</sup>Radiology and Medical Imaging Department, Louga Regional Hospital, Louga, Senegal

<sup>2</sup>Radiology and Medical Imaging Department, Fann National University Hospital, Dakar, Senegal

Email: \*midouthio@gmail.com

**How to cite this paper:** Deme, H., Gueye, C.A.B., Mbaye, P.A., Fall, M.E.B., Ndichout, A., Diasse, I., Faye, I. and Ba, S. (2026) Correlation between Ultrasound Findings and Histological Data of Thyroid Nodules at Louga Regional Hospital. *Open Journal of Medical Imaging*, 16, 32-42. <https://doi.org/10.4236/ojmi.2026.161005>

**Received:** December 16, 2025

**Accepted:** January 31, 2026

**Published:** February 3, 2026

Copyright © 2026 by author(s) and Scientific Research Publishing Inc. This work is licensed under the Creative Commons Attribution International License (CC BY 4.0). <http://creativecommons.org/licenses/by/4.0/>



Open Access

## Abstract

**Objectives:** To clarify the role of cervical ultrasound in the investigation and characterization of thyroid nodules and its predictive value for malignancy or benignity by searching for a correlation between ultrasound findings and histology results. **Materials and Methods:** We performed a prospective study of 34 patients who underwent surgery for nodular thyroid disease at the Louga Regional Hospital Centre over a ten-month period, from 1 January 2023 to 31 October 2023. **Results:** There were 33 women and 1 man, giving a sex ratio of 0.03. The average age of patients was 42.35 years. Thyroid nodules were discovered in 94.1% of cases due to anterior cervical swelling. A family history of thyroid goiter was noted in 23.5% of patients, and 20.6% of patients had thyroid hyperfunction. On ultrasound, 52.9% of nodules were solitary and 47.1% were part of a multinodular goiter. The nodules were bilobar in 41.2% of cases, with an average size of 26.2 mm. The nodules were solid in 52.9% of cases, mixed in 41.2% and spongiform in 5.9%. The form was oval for 33 nodules (97.1%) and non-oval for 1 nodule (2.9%); 5.9% of nodules had irregular borders. In terms of echogenicity, 17.6% of nodules were hyperechoic, 50% were isoechoic, 20.6% were mildly hypoechoic, 5.9% were severely hypoechoic and 5.9% were anechoic. Microcalcifications were found in 5.9% of cases. The nodules were classed as EU-TIRADS 2 in 5.88% of cases, EU-TIRADS 3 in 64.71%, EU-TIRADS 4 in 20.59% and EU-TIRADS 5 in 8.82% of cases. On histology, 17.6% of nodules were malignant. The risk of malignancy was 0% for score 2, 4.5% for score 3, 28.6% for score 4 and 100% for score 5. The risk of malignancy was associated with nodule size, non-oval shape, irregular contours, hypoechoic appearance and the presence of microcalcifications. **Conclusion:** Pertinent ultrasound analysis remains highly useful in the pre-surgical identification of

factors predictive of malignancy in thyroid nodules.

## Keywords

Thyroid Nodule, Ultrasound, Histology

---

## 1. Introduction

A nodule is defined as any localized enlargement of the thyroid gland [1]. Its frequency is 4% to 7% for palpable nodules and 30% to 50% for nodules discovered by ultrasound [2].

The discovery of a thyroid nodule raises the question of whether it may be cancerous. The advent of fine needle aspiration cytology has greatly helped to resolve this issue. This test is now considered the most effective way of distinguishing between benign and malignant nodules [3] [4]. In some medical facilities, however, fine needle aspiration is not available. Clinicians must then rely on a range of clinical and paraclinical arguments to make the best possible diagnosis if they want to avoid unnecessary and costly interventions.

The aim of this study was to demonstrate the role of cervical ultrasound in the investigation and characterization of thyroid nodules and its predictive value in determining malignancy or benignity by searching for a correlation between ultrasound findings and definitive pathological results.

The specific objectives were to:

- Describe the ultrasound features of thyroid nodules;
- Perform EU-TIRADS classification;
- Compare EU-TIRADS classification with histological data.

## 2. Materials and Methods

We conducted a prospective descriptive and analytical study over a ten-month period, from 1 January 2023 to 31 October 2023, in the medical imaging and otorhinolaryngology departments of the Louga Regional Hospital Center.

All patients monitored for a solitary thyroid nodule or within a multinodular goiter, who underwent cervical ultrasound and thyroidectomy (total or partial) during the study period with an available pathological examination result, were included.

The ultrasounds were performed using a Siemens Acuson NX3 Elite machine with a 12 MHz superficial probe for B-mode thyroid examination with color Doppler coupling. We described the ultrasound features of the thyroid nodules, then established the EU-TIRADS classification [5] and finally compared the EU-TIRADS class with the histological data. For patients with heteromultinodular goiter, we considered the nodule with the highest EU-TIRADS score.

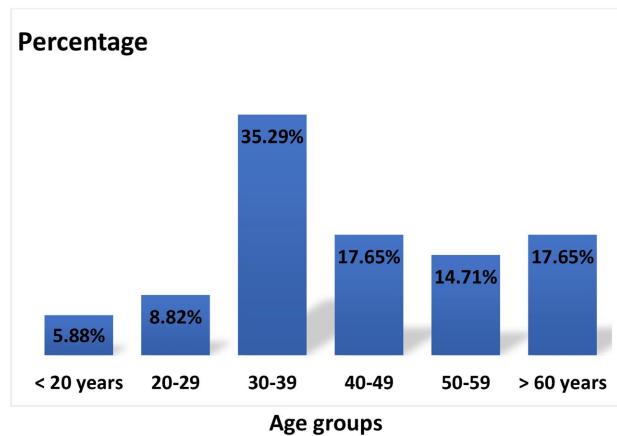
The data was entered and sorted using Excel 2019 software and analyzed using SPSS 29, enabling us to correlate the ultrasound and histological characteristics of

each nodule examined based on the data collected. We performed a chi-square test with a significance level of 5%.

### 3. Results

#### 3.1. Epidemiological, Clinical and Hormonal Data

We collected data from 34 patients. These included 33 women (97.1%) and 1 man (2.9%), giving a sex ratio of 0.03. The average age was 42.35 years, ranging from 18 to 70 years (**Figure 1**) with a standard deviation of 14.55.



**Figure 1.** Distribution of patients by age groups.

Thyroid nodules were discovered in 94.1% of cases presenting with anterior cervical swelling, in 2.9% of cases presenting with exophthalmos, and incidentally in 2.9% of cases. A family history of goiter was found in 23.5% of patients, thyroid surgery in 5.9% of cases, 47.1% of patients had no particular history, and 23.5% were being monitored for other conditions (11.8% for gastroesophageal reflux and 8.8% for diabetes). No patients had a history of cervical irradiation during childhood. 79.4% of patients were euthyroid and 20.6% were hyperthyroid.

#### 3.2. Ultrasound Data

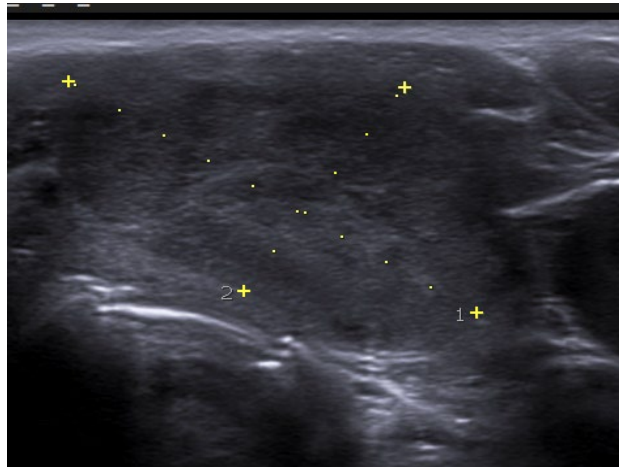
The ultrasound examination detected multiple thyroid nodules in 47.1% of cases and a solitary nodule in 52.9% of cases. The location of the thyroid nodule examined was bilobar in 41.2% of cases.

For patients with multiple nodules, we considered the most significant nodule.

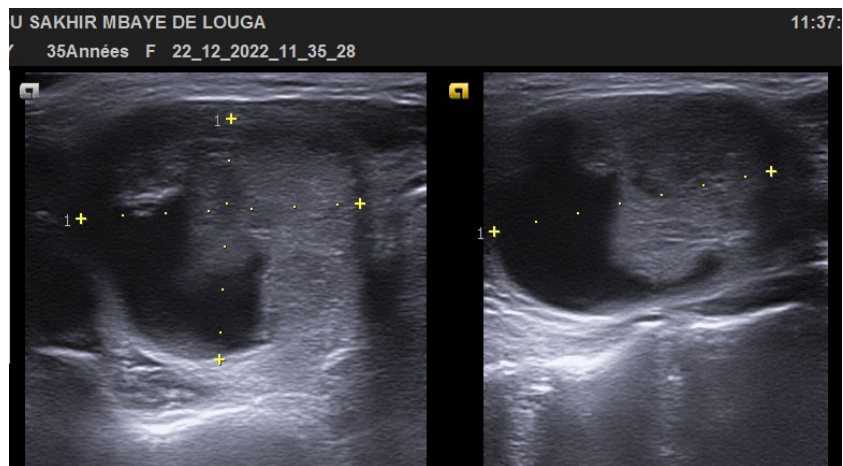
The average size of the nodules was 26.2 mm in length. The shape was oval for 33 nodules (97.1%) and non-oval for 1 nodule (2.9%). The borders of the nodules were regular (**Figure 2**) in 32 cases (94.1%) and irregular in 2 cases (5.9%).

The nodules were solid in 52.9% of cases, mixed in 41.2% (**Figure 3**) and sponge-like in 5.9%.

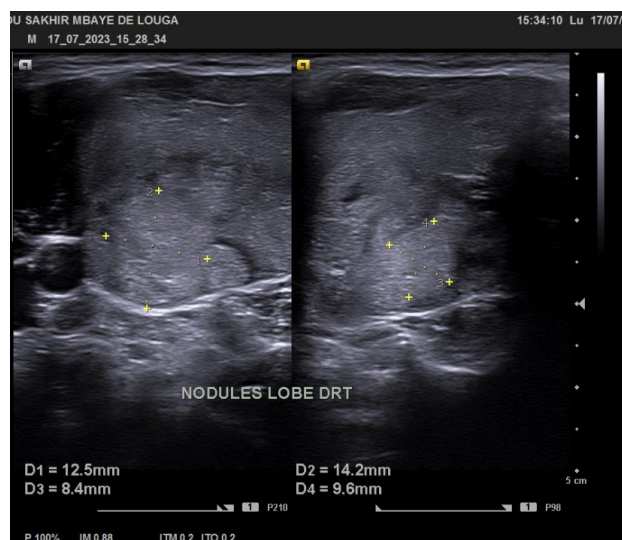
In terms of echogenicity, 17.6% of nodules were hyperechoic (**Figure 4**); 50% were isoechoic; 20.6% were moderately hypoechoic (**Figure 5**); 5.9% were severely hypoechoic; and 5.9% were anechoic.



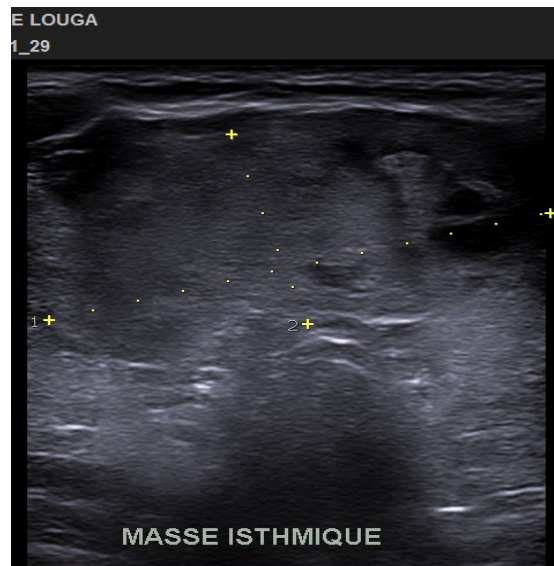
**Figure 2.** Longitudinal section showing an oval-shaped thyroid nodule with regular contours.



**Figure 3.** Axial and longitudinal section of a mixed thyroid nodule with tissue and cystic components.



**Figure 4.** Axial sections showing straight, hyperechoic thyroid nodules.



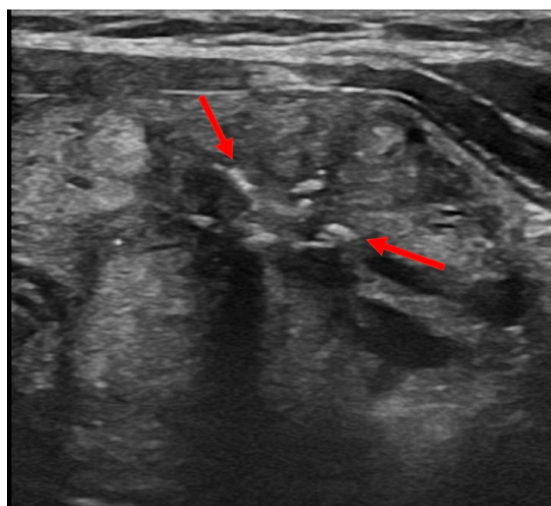
**Figure 5.** Axial section showing a thyroid nodule with a mildly hypoechoic area.

Calcifications were absent in 88.2% of cases, 5.9% of nodules had microcalcifications (**Figure 6**) and 5.9% had macrocalcifications (**Figure 7**). No cervical lymphadenopathy was found in our patients.

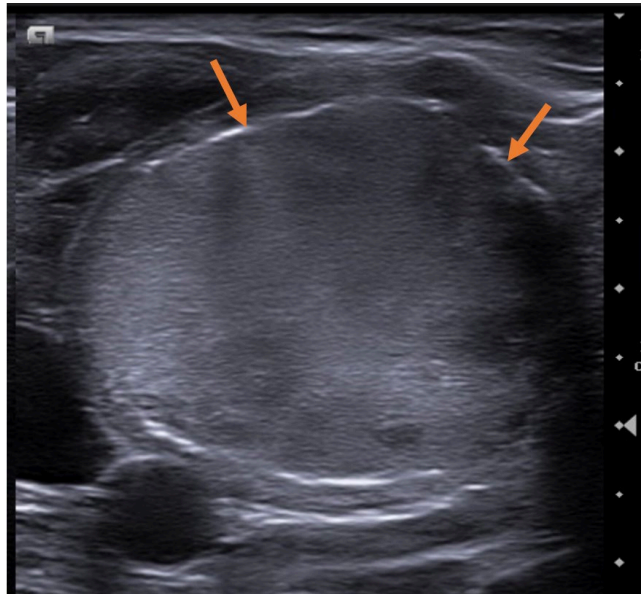
Following ultrasound examination, the thyroid nodules were classified according to the EU-TIRADS system (**Figure 8**).

Of the 34 thyroid nodules removed during surgery, the final histological examination revealed 28 benign nodules (82.4%) with 24 patients having benign follicular lesions and 4 patients having benign cystic lesions, and 6 malignant nodules (17.6%), including 5 papillary carcinomas and 1 oncocytic carcinoma.

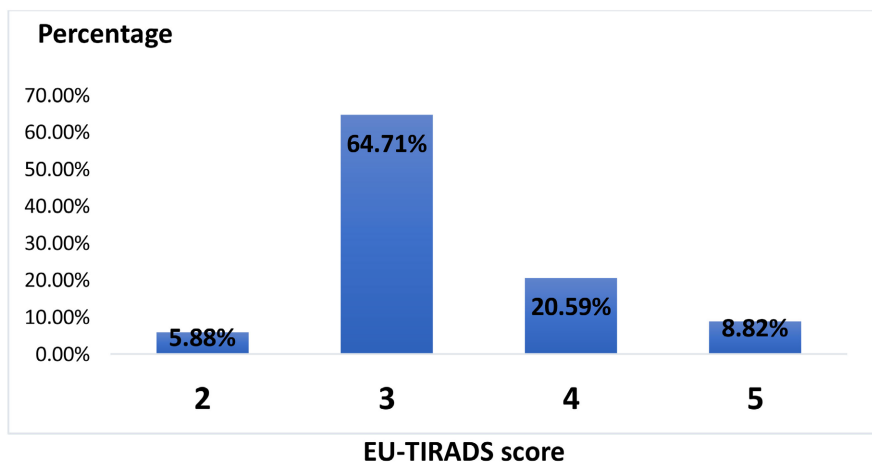
A comparison of histological and ultrasound data showed that there was a highly significant statistical relationship between the EU-TIRADS score and the risk of thyroid cancer ( $p < 0.001$ ) (**Figure 9**).



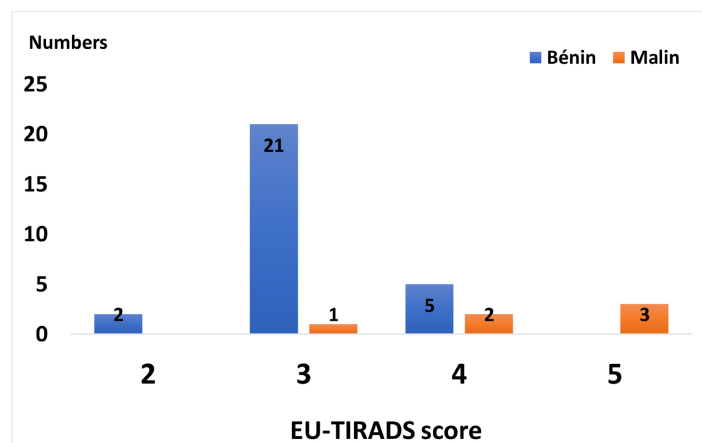
**Figure 6.** Axial section showing a thyroid nodule with central microcalcifications (red arrows).



**Figure 7.** Thyroid nodule showing peripheral macrocalcification in an eggshell pattern (orange arrows).



**Figure 8.** Classification of nodules according to the EU-TIRADS score.



**Figure 9.** Histology of patients according to EU-TIRADS score.

Comparison of histological, ultrasound and epidemiological data showed that the percentage of malignancy increased with age ( $p = 0.02$ ). It was 66.7% in the over-60 age group. The risk of malignancy was almost identical for solitary nodules and multinodular thyroid goiter (18.8% vs. 16.7%) ( $p = 0.87$ ). There was no statistical relationship between the location of the nodule and malignancy ( $p = 0.19$ ). The suspicion of malignancy was higher for nodules smaller than 30 mm ( $p = 0.03$ ), for non-oval-shaped nodules ( $p = 0.03$ ) and for nodules with irregular contours ( $p = 0.002$ ). A highly hypoechoic character had a statistically significant relationship with the prediction of cancer ( $p = 0.02$ ). The presence of macrocalcifications suggested benignity, while the presence of microcalcifications suggested malignancy ( $p = 0.006$ ).

#### 4. Discussion

The average age of patients in our study was 42.35 years, ranging from 18 to 70 years. The frequency of thyroid nodules increases with age. This has been clearly demonstrated by Mortensen *et al.*'s assessments [6]. In our study, the percentage of malignancy increased with age ( $p = 0.02$ ) and was 66.7% in the over-60 age group. This was also the case in a Moroccan study by Abousaad [7]. In the latter study, the malignancy rate in patients over 60 years of age was 57.1%. Extreme ages have a higher risk of malignancy in the literature [8]-[10]. According to Belfior *et al.* [11], this risk is around 50% after 60 years of age.

In our study, there was a predominance of females with a sex ratio of 0.03. According to Mazzaferri *et al.* [12], females are more represented than males, with a ratio of 3 females to 1 male, thus demonstrating the role played by the presence of sex steroid receptors in follicular cells.

Multinodular thyroid goiter was for a long time considered "benign" compared to solitary nodules [13]-[15]. This notion has been revised by several authors who found that the risk of malignancy was identical for both groups [16]. In our series, this risk was almost identical for solitary nodules and multinodular thyroid goiter (18.8% vs. 16.7%).

The average size of nodules in our series was 26.2 mm in length. These results are comparable to those found in Diourbel (Senegal) [17], with an average size of 28 mm, and those of Abousaad [7], who found 24 mm. Some authors [18] [19] find that a size greater than 4 cm is highly suspicious, while others disagree with this notion [20] [21]. In Sfar *et al.*'s study [22], nodules larger than two centimeters were cancerous with a statistically significant relationship ( $p = 0.001$ ) and, according to Zhao *et al.*'s study [23], smaller nodules are associated with an increased risk of cancer (with  $p < 0.01$ ), which is consistent with our study, where the suspicion of malignancy was higher for nodules smaller than 30 mm ( $p = 0.03$ ).

The orientation of the nodule is a predictive criterion for malignancy, and a non-oval nodule is one of the five strong signs of suspected malignancy [5]. In our study, the malignancy rate of non-oval nodules was 100% with a statistically significant relationship ( $p = 0.03$ ). This is also consistent with the results of the Mo-

roccan study by Azal [24], which found a significant correlation ( $p = 0.0001$ ). The contours of the nodules are also important. Indistinct and/or irregular contours are arguments in favour of malignancy. In our study, irregular contours were found in 5.9% of nodules and were malignant in 100% of cases, with a statistically significant relationship ( $p = 0.002$ ). This is the case in the studies by Abousaad [7] and Bouaity *et al.* [25], with respective malignancy rates of 80.6% and 75.8%. In several studies, such as that by Azizi *et al.* [26], irregular contours had a statistically significant relationship in predicting cancer ( $p = 0.001$ ), as was the case for Sfar *et al.* [22] ( $p = 0.01$ ) and Ríos *et al.* [27] ( $p = 0.0001$ ).

The echogenicity of thyroid nodules is important to consider. Nodules can be anechoic, hyperechoic, isoechoic, or hypoechoic [28]. Hyperechoic nodules are rarely malignant (1.3% to 4%) [29]. Hypoechoic nodules are more than half the time cancerous. This is the most common form of thyroid cancer. With regard to the echogenicity of nodules, our series is consistent with those of Azal [24] and Abousaad [7].

Calcifications are frequently found. Their presence increases the risk of cancer by a factor of 2.5, which could reach 75% for solitary nodules [30]. In the series by El korbi *et al.* [31], malignant nodules contained microcalcifications with a statistically significant relationship with cancer prediction ( $p = 0.02$ ), as in the studies by Hasnaoui *et al.* [32] ( $p < 0.01$ ) and Abousaad [7] ( $p = 0.0001$ ). This is consistent with the results of our series, where microcalcifications had a statistically significant relationship with cancer prediction ( $p = 0.006$ ).

The EU-TIRADS score of the European Thyroid Association [5] is a 4-point score (from 2 to 5). Each score corresponds to a risk of cancer. The score is based on four highly suspicious signs: high hypoechoogenicity, micro-lobulated or spiculated contours, disharmonious shape, and microcalcifications. A single sign is sufficient to classify the nodule as score 5. The results of our study are broadly consistent with this system, as are those of Azal [24] (Table 1).

**Table 1.** Percentage of malignancy according to the EU-TIRADS classification based on studies.

	EU-TIRADS score	Azal [24] (Maroc)	EU-TIRADS [5]	Our study
2	Frequency	7.75%	5%	5.88%
	<b>Malignancy</b>	<b>0%</b>	<b>≈0%</b>	<b>0%</b>
3	Frequency	53.44%	63%	64.71%
	<b>Malignancy</b>	<b>7.69%</b>	<b>2% - 4%</b>	<b>4.5%</b>
4	Frequency	29.3%	27%	20.59%
	<b>Malignancy</b>	<b>15.38%</b>	<b>6% - 17%</b>	<b>28.6%</b>
5	Frequency	9.48%	5%	8.82%
	<b>Malignancy</b>	<b>76.92%</b>	<b>26% - 87%</b>	<b>100%</b>

The main limitation of our study remains the small sample size ( $n = 34$ ).

## 5. Conclusion

The comparison of ultrasound and histological data in our study has enabled us to objectively identify the following criteria for malignancy in thyroid nodules: size, non-oval shape, irregular contours, hypoechoic appearance, and the presence of microcalcifications. A pertinent ultrasound analysis remains highly useful in the pre-surgical identification of factors predictive of malignancy in a thyroid nodule, supplemented by ultrasound-guided fine needle aspiration, which remains, however, rarely available in routine practice.

## Conflicts of Interest

The authors declare no conflicts of interest regarding the publication of this paper.

## References

- [1] Wémeau, J.L., Sadou, J.L., d'Herbomez, M., Monpeyssen, H., Tramalloni, J., Leteurtre, E., *et al.* (2011) Recommandations de la Société française d'endocrinologie pour la prise en charge des nodules thyroïdiens. *Presse Médicale*, **40**, 793-826.
- [2] Borges-Martins, L., Betea, D., Thiry, A.M., Petrossians, P. and Beckers, A. (2006) Nodules de la thyroïde. *Revue Médicale de Liège*, **61**, 309-316.
- [3] Pacini, F., Schlumberger, M., Dralle, H., Elisei, R., Smit, J.W.A., Wiersinga, W., *et al.* (2006) European Consensus for the Management of Patients with Differentiated Thyroid Carcinoma of the Follicular Epithelium. *European Journal of Endocrinology*, **154**, 787-803. <https://doi.org/10.1530/eje.1.02158>
- [4] Schlumberger, M. (2007) Cancer papillaire et folliculaire de la thyroïde. *Annales d'Endocrinologie*, **68**, 120-128. <https://doi.org/10.1016/j.ando.2007.04.004>
- [5] Russ, G., Bonnema, S.J., Erdogan, M.F., Durante, C., Ngu, R. and Leenhardt, L. (2017) European Thyroid Association Guidelines for Ultrasound Malignancy Risk Stratification of Thyroid Nodules in Adults: The Eu-Tirads. *European Thyroid Journal*, **6**, 225-237. <https://doi.org/10.1159/000478927>
- [6] Mortensen, J., Woolner, L.B. and Bennett, W.A. (1955) Gross and Microscopic Findings in Clinically Normal Thyroid Glands. *The Journal of Clinical Endocrinology & Metabolism*, **15**, 1270-1280. <https://doi.org/10.1210/jcem-15-10-1270>
- [7] Abousaad, B. (2017) Corrélation du score TIRADS à l'histologie des nodules thyroïdiens: Étude rétrospective et revue de la littérature. Thèse d'Exercice de Médecine, Université Cadi Ayyad de Marrakech.
- [8] Gatta, G., Capocaccia, R., De Angelis, R., Stiller, C. and Coebergh, J.W. (2003) Cancer Survival in European Adolescents and Young Adults. *European Journal of Cancer*, **39**, 2600-2610. <https://doi.org/10.1016/j.ejca.2003.09.004>
- [9] Shirzad, M., Larijani, B., Hedayat, A., Kamalian, N., Baradar-Jalili, R., Bandarian, F., *et al.* (2003) Diagnostic Value of Frozen Section Examination in Thyroid Nodule-Surgery at the Shariati Hospital (1997-2000). *Endocrine Pathology*, **14**, 263-268. <https://doi.org/10.1007/s12022-003-0019-x>
- [10] Van Tol, K.M., De Vries, E.G.E., Dullaart, R.P.F. and Links, T.P. (2001) Differentiated Thyroid Carcinoma in the Elderly. *Critical Reviews in Oncology/Hematology*, **38**, 79-91.
- [11] Belfiore, A., La Rosa, G.L., La Porta, G.A., Giuffrida, D., Milazzo, G., Lupo, L., *et al.* (1992) Cancer Risk in Patients with Cold Thyroid Nodules: Relevance of Iodine In-

- take, Sex, Age, and Multinodularity. *The American Journal of Medicine*, **93**, 363-369. [https://doi.org/10.1016/0002-9343\(92\)90164-7](https://doi.org/10.1016/0002-9343(92)90164-7)
- [12] Desforges, J.F. and Mazzaferri, E.L. (1993) Management of a Solitary Thyroid Nodule. *New England Journal of Medicine*, **328**, 553-559. <https://doi.org/10.1056/nejm199302253280807>
- [13] Burger, A. (2002) Nodules et goitres thyroïdiens. *Forum Médical Suisse—Swiss Medical Forum*, **44**, 1039-1043. <https://doi.org/10.4414/fms.2002.04684>
- [14] Mansi, L., Moncayo, R., Cucurullo, V., Dottorini, M.E. and Rambaldi, P.F. (2004) Nuclear Medicine in Diagnosis, Staging and Follow-Up of Thyroid Cancer. *The Quarterly Journal of Nuclear Medicine and Molecular Imaging*, **48**, 82-95.
- [15] Ríos, A., Rodríguez, J.M., Canteras, M., Galindo, P.J., Balsalobre, M.D. and Parrilla, P. (2004) Risk Factors for Malignancy in Multinodular Goitres. *European Journal of Surgical Oncology (EJSO)*, **30**, 58-62. <https://doi.org/10.1016/j.ejso.2003.10.021>
- [16] Hegedüs, L., Bonnema, S.J. and Bennedbæk, F.N. (2003) Management of Simple Nodular Goiter: Current Status and Future Perspectives. *Endocrine Reviews*, **24**, 102-132. <https://doi.org/10.1210/er.2002-0016>
- [17] Deme, H., Lamah, A., Ndiade, A., Balde, D., Wade, A., Akpo, L.G., *et al.* (2025) Corrélation échographique et cytologique dans le diagnostic des nodules thyroïdiens. *Journal de Radiologie et de Médecine Nucléaire d'Afrique*, **4**, 40-46.
- [18] Cannoni, M., Demard, F. and Bourdinière, J. (1995) Les nodules thyroïdiens du diagnostic à la chirurgie. Arnette, 1 p.
- [19] Tourniaire, J. and Henry, J.F. (1993) Prise en charge du nodule thyroïdien isolé: Evaluation clinique. Commentaires. *Annales d'Endocrinologie*, **54**, 226-231.
- [20] Mazzaferri, E.L. (1992) Thyroid Cancer in Thyroid Nodules: Finding a Needle in the Haystack. *The American Journal of Medicine*, **93**, 359-362. [https://doi.org/10.1016/0002-9343\(92\)90163-6](https://doi.org/10.1016/0002-9343(92)90163-6)
- [21] Modigliani, E. (1993) Commentaires sur l'évaluation du traitement chirurgical des nodules thyroïdiens isolés. *Annales d'Endocrinologie*, **54**, 283-285.
- [22] Sfar, R., Lahmar, I., Driss, N. and Essabbah, H. (2008) Quels critères alternatifs à la cytoponction d'un nodule thyroïdien? *Annales d'Otolaryngologie et de Chirurgie Cervico-faciale*, **125**, 122-127. <https://doi.org/10.1016/j.aorl.2008.02.002>
- [23] Zhao, L., Yan, H., Pang, P., Fan, X., Jia, X., Zang, L., *et al.* (2018) Thyroid Nodule Size Calculated Using Ultrasound and Gross Pathology as Predictors of Cancer: A 23-Year Retrospective Study. *Diagnostic Cytopathology*, **47**, 187-193. <https://doi.org/10.1002/dc.24068>
- [24] Azal, H. (2021) Impact de l'échographie dans la prise en charge des nodules thyroïdiens. Thèse d'Exercice de Médecine, Université Cadi Ayyad de Marrakech.
- [25] Bouaity, B., Darouassi, Y., Chihani, M., Touati, M.M. and Ammar, H. (2016) Analyse des facteurs prédictifs de malignité des goitres nodulaires: À propos de 500 cas. *Pan African Medical Journal*, **23**, Article 88. <https://doi.org/10.11604/pamj.2016.23.88.8405>
- [26] Azizi, G., Faust, K., Ogden, L., Been, L., Mayo, M.L., Piper, K., *et al.* (2021) 3-D Ultrasound and Thyroid Cancer Diagnosis: A Prospective Study. *Ultrasound in Medicine & Biology*, **47**, 1299-1309. <https://doi.org/10.1016/j.ultrasmedbio.2021.01.010>
- [27] Ríos, A., Rodríguez, J.M., Torregrosa, N.M., Torregrosa, B., Cepero, A., Abellán, M.D., *et al.* (2018) Evaluación del nódulo tiroideo con ecografía y elastografía de alta resolución sin la punción-aspiración con aguja fina. *Medicina Clínica*, **151**, 89-96. <https://doi.org/10.1016/j.medcli.2017.09.016>

- [28] Alexander, L.F., Patel, N.J., Caserta, M.P. and Robbin, M.L. (2020) Thyroid Ultrasound: Diffuse and Nodular Disease. *Radiologic Clinics of North America*, **58**, 1041-1057. <https://doi.org/10.1016/j.rcl.2020.07.003>
- [29] Bruneton, J.N., Balu-Maestro, C., Marcy, P.Y., Melia, P. and Mourou, M.Y. (1994) Very High Frequency (13 MHz) Ultrasonographic Examination of the Normal Neck: Detection of Normal Lymph Nodes and Thyroid Nodules. *Journal of Ultrasound in Medicine*, **13**, 87-90. <https://doi.org/10.7863/jum.1994.13.2.87>
- [30] Khoo, M.L.C., Asa, S.L., Witterick, I.J. and Freeman, J.L. (2002) Thyroid Calcification and Its Association with Thyroid Carcinoma. *Head & Neck*, **24**, 651-655. <https://doi.org/10.1002/hed.10115>
- [31] El korbi, A., Harrathi, K., Belhadj Rhouma, S., Kolsi, N., El Abed, W. and Koubaa, J. (2014) Facteurs prédictifs de malignité d'un nodule thyroïdien. *Annales Françaises d'Otorhino-Laryngologie et de Pathologie Cervico-Faciale*, **131**, A14-A15. <https://doi.org/10.1016/j.aforl.2014.07.045>
- [32] Hasnaoui, M., Masmoudi, M., Belaid, T. and Mighri, K. (2020) Place de la classification TIRADS dans la stratification du risque de malignité d'un nodule thyroïdien. *Annales d'Endocrinologie*, **81**, 228. <https://doi.org/10.1016/j.ando.2020.07.237>