

Ultrasound of the Rotator Cuff in Non-Fractured Shoulder Trauma: 30 Cases at the Yalgado Ouedraogo University Hospital of Ouagadougou (Burkina Faso)

Milckisédek Judicaël Marouruana Some^{1*}, Aïda Ida Tankoano², Pakisba Ali Ouedraogo¹, Ladouon Sylvie Simboro³, Bassirou Kindo¹, Siaka Ben Aziz Dao⁴, Rabiou Cisse⁴

¹Department of Medical Imaging, The Ouahigouya Regional University Hospital, University of Ouahigouya, Ouahigouya Burkina Faso

²Department of Medical Imaging, Souro Sanou University Hospital, Nazi Boni University, Bobo Dioulasso, Burkina Faso

³Department of Medical Imaging, Workers' Health Office, Ouagadougou, Burkina Faso

⁴Department of Medical Imaging, Yalgado Ouedraogo University Hospital, Joseph Ki Zerbo University, Ouagadougou, Burkina Faso

Email: *melckisedekj@yahoo.fr

How to cite this paper: Some, M.J.M., Tankoano, A.I., Ouedraogo, P.A., Simboro, S.L., Kindo, B., Dao, S.B.A. and Cisse, R. (2024) Ultrasound of the Rotator Cuff in Non-Fractured Shoulder Trauma: 30 Cases at the Yalgado Ouedraogo University Hospital of Ouagadougou (Burkina Faso). *Open Journal of Medical Imaging*, 14, 64-71.

<https://doi.org/10.4236/ojmi.2024.142006>

Received: April 3, 2024

Accepted: May 7, 2024

Published: May 10, 2024

Copyright © 2024 by author(s) and Scientific Research Publishing Inc. This work is licensed under the Creative Commons Attribution International License (CC BY 4.0).

<http://creativecommons.org/licenses/by/4.0/>



Open Access

Abstract

Introduction: Ultrasound is the imaging technique of choice for the study of rotator cuff lesions. However, in the case of shoulder trauma, it is rarely requested in our context. This study aimed to show ultrasound lesions of the rotator cuff in cases of non-fracture shoulder trauma at the CHUYO in Ouagadougou. **Methodology:** This was a prospective descriptive cross-sectional study running from August 1 to November 30, 2017, in the medical imaging department of CHUYO. The study population consisted of patients received in the department for ultrasound in the context of non-fracture shoulder trauma. **Results:** We collected 20 cases (66.67%) of rotator cuff lesions out of 30 non-fracture shoulder injuries. The mean age of the patients was 27.6 years. Road traffic accidents accounted for 60% of injuries, sports accidents for 30%, and domestic accidents for 10%. Ultrasound lesions were mainly tendon ruptures (36.67%) and tendinitis (23.33%). Ruptures were non-transfixing in 90.90% of cases. The supraspinatus was the most affected (81.81%). **Conclusion:** Ultrasound can help diagnose rotator cuff injuries, particularly in non-fractured shoulder trauma.

Keywords

Traumatic Shoulder, Rotator Cuff, Ultrasound

1. Introduction

Shoulder trauma is a major cause of osteoarticular trauma. Indeed, Rambert in France reported 54.34% of shoulder trauma cases, Kocher and Feagin in the USA 11.2%, Diarra in Mali 9.73%, and Ouédraogo in Burkina Faso 6.73% [1] [2] [3] [4]. Several types of shoulder trauma have been identified, dominated by fractures and dislocations. In addition to bone and joint injuries, there are also post-traumatic tendon injuries, notably to the rotator cuff. Rutten *et al.* in the USA found 46% cases of rotator cuff lesions in non-fractured shoulder trauma, Rambert in France 41%, and Kocher and Feagin 25% [1] [2] [5]. In our context, the diagnosis and management of shoulder trauma most often focus on fractures and dislocations, as shown by studies by Badr in Morocco, Diarra in Mali, and Ouédraogo in Burkina Faso [3] [4] [6]. Post-traumatic shoulder treatment aims to reduce, consolidate, and above all, recover shoulder function. This is generally not possible without diagnosis and management of tendon and ligament injuries, requiring MRI or ultrasound. Ultrasound offers comparable results to MRI at a much lower cost and can detect discrete abnormalities and several different tendon pathological entities [7-8]. In Africa, however, there is very little demand for this procedure in the management of shoulder trauma. Indeed, in a study carried out by Badr in Morocco, it was performed in 2.4% of cases, and no ultrasonography was performed in the studies by Diarra in Mali and Ouédraogo in Burkina [3] [4] [6]. We therefore proposed to study ultrasound lesions of the rotator cuff in cases of non-fracture shoulder trauma at the CHUYO in Ouagadougou.

2. Materials and Methods

2.1. Study Design, Period and Setting

This descriptive cross-sectional study with prospective data collection covered a period of four (04) months from August 1er to November 30, 2017, and took place in the radiodiagnostic and medical imaging department of the Centre Hospitalier Universitaire Yalgado Ouédraogo (CHUYO).

2.2. The Study Population, Inclusion Criteria and Non-Inclusion

The target population consisted of all patients received in the medical imaging department of CHUYO for ultrasonography in the context of non-fractural shoulder trauma. All patients were systematically recruited during the study period. All patients who presented to the medical imaging department with any notion of shoulder trauma, without radiographic fracture, and who had given their consent to participate in this study, were included. Patients with an associated shoulder fracture and those with no shoulder X-ray were excluded.

2.3. Data Collection and Analysis

All adult patients with shoulder trauma, hospitalized or not, were examined by traumatologists and systematically underwent radiographic examination. Patients

without a shoulder fracture were invited to undergo additional ultrasonography. The variables studied were epidemiological (age, sex), clinical (circumstances of onset and mechanism of trauma), and ultrasonographic (epidemiology of lesions, type of rotator cuff injury, topography of tendon damage, associated lesions).

Data were collected on an individual data collection sheet, entered on a PC, and analyzed using EPI-INFO software version 3.5.1. We performed a descriptive analysis of the variables collected in the form of proportions.

Informed consent was obtained from patients, and data confidentiality was respected.

3. Results

3.1. Epidemiological Data

Of the 30 patients selected (presenting with non-fractured shoulder trauma), 20 (66.67%) showed a rotator cuff lesion on shoulder ultrasound.

Our study included 18 men and 12 women, giving a sex ratio of 1.5. Of the patients with rotator cuff injuries, fifteen (15) were male and 05 female.

The mean age of patients in the study was 30 years, with extremes of 16 and 55 years. It was 27.6 years, with extremes of 16 and 50 years for patients with rotator cuff injuries. Young adults under 35 accounted for 70%.

Figure 1 shows the age distribution of patients with rotator cuff injuries.

3.2. Clinical Data

The circumstances in which the injury occurred were road traffic accidents in 18 cases, followed by sports accidents in 8 cases, and domestic accidents in 4 cases. For patients with a cuff injury, road traffic accidents were the most common circumstance, accounting for 12 cases (60%). This was followed by sports accidents in 6 cases (30%). Domestic accidents were found in 2 cases (10%).

Direct impact was the mechanism in 12 cases of cuff injury (60%), dominated by a fall onto the hand (62%); indirect impact was the mechanism in 8 cases (40%).

The left shoulder was affected in 19 patients (63.33%) and the right in 11 (36.67%). The dominant shoulder was the right shoulder in all our patients. Rotator cuff lesions were localized to the left shoulder in 13 cases (65%) and to the

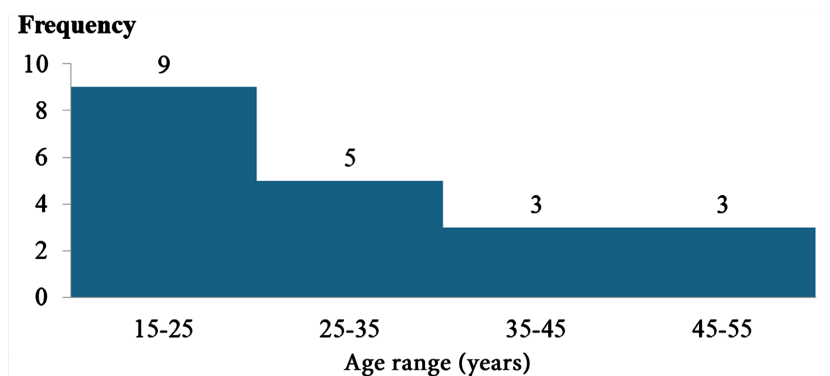


Figure 1. Age distribution of patients with rotator cuff injuries.

right shoulder in 7 cases (35%). No patient had simultaneous involvement of both shoulders.

Ultrasound was performed before one week in 8 cases and between one week and one month in 12 cases, in the remaining 10 cases it was performed one month after shoulder trauma.

The distribution of patients with a cuff injury according to the time taken to perform the ultrasound scan can be found in **Table 1**.

3.3. Ultrasound Data

The equations are an exception to the prescribed specifications of this template. You Ultrasound examination revealed rotator cuff lesions in 20 patients (66.67%), with or without other associated lesions; in seven (23.33%), the ultrasound examination was normal; and the remaining 03 patients (10%) had isolated lesions other than those of the rotator cuff (synovitis of the long biceps tendon, calcification, and osteophyte).

Ultrasound revealed three main types of lesions: tendon ruptures in 36.67% of patients, tendinitis (23.33%), and tendon deinsertions (10%). **Table 2** shows the echostructure of rotator cuff lesions.

We noted 10 cases of non-transfixing ruptures of minimal severity, involving all cuff tendons, and one case of medium transfixing rupture of the supraspinatus. The supraspinatus tendon was the most severely affected (81.81%).

All cases of tendon disinsertion involved the supraspinatus (100%).

Table 1. Distribution of patients with cuff injury according to time to ultrasound.

| Delay | Frequency |
|------------------------|-----------|
| <7 days | 7 |
| >7 days and <1 month | 8 |
| >1 month and <3 months | 3 |
| >3 months | 2 |
| Total | 20 |

Table 2. Echostructure of rotator cuff lesions.

| Echostructure of rotator cuff injuries | Frequency n = 20 | Percentage (%) |
|--|---------------------|----------------|
| Hypoechoic defect | 9 | 45 |
| Anechoic defect | 4 | 20 |
| Superficial flat spot | 1 | 5 |
| Hypoechoic appearance of the tendon without defect | 7 | 35 |
| Loss of tendon fibrillation | 3 | 15 |
| Tendon thickening | 6 | 30 |
| Doppler vascularization of the tendon | 5 | 25 |

In the case of tendonitis, the supraspinatus was affected in 5 cases (71.44%) and the infraspinatus in 2 cases (28.56%).

Standard radiography was performed in all 30 patients. It was normal in 24 patients and abnormal in the other six (06) (3 cases of condensation of the trochanter, 2 cases of reduction of the subacromial space, and one case of osteophyte).

Among our 20 patients with rotator cuff damage on ultrasound, standard radiography was normal in 90%, and in 10% we noted indirect signs of tendon damage.

3.4. Illustration

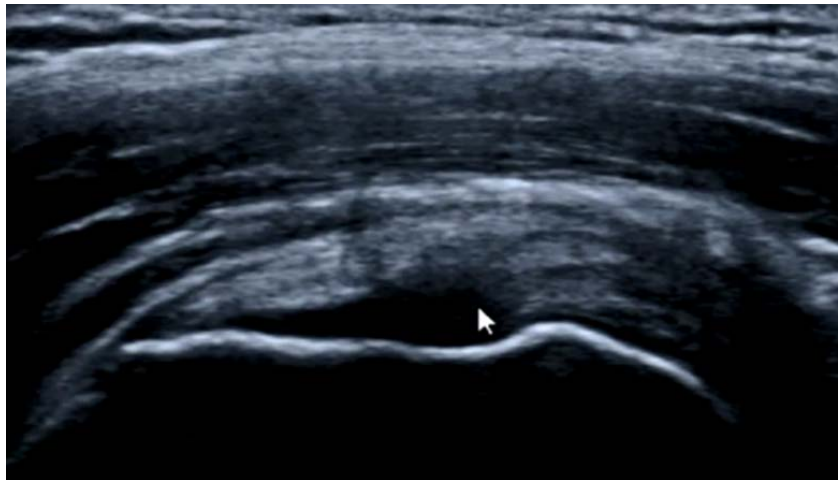


Figure 2. A 28-year-old patient, road traffic accident. Trauma to the right shoulder. Pain with limitation of right shoulder movement. Ultrasound at 14 days. High-frequency probe, coronal section. Evidence of an anechogenic defect of the deep aspect of the supraspinatus (white arrow). Source: CHUYO IMR Department.

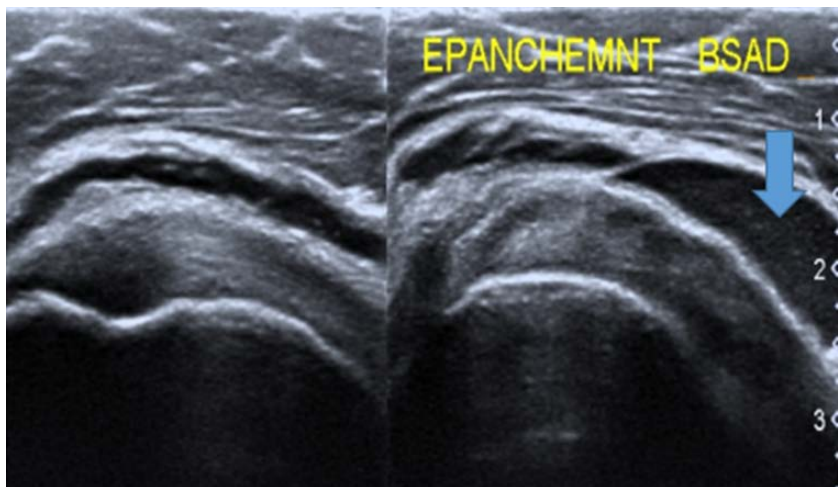


Figure 3. A 20-year-old patient in a road traffic accident. Trauma to the right shoulder. Swelling with pain on mobilization of the right shoulder. Ultrasound at 5 days. High-frequency probe, longitudinal section. Echogenic fluid effusion in the left subacromial-deltoid bursa (blue arrow). Source: CHUYO IMR Department.

4. Discussion

We documented 30 cases of shoulder trauma, including 20 cases of rotator cuff injury (66.67%), 36.67% of which were tendon ruptures. Our results are similar to those of Rambert [1] and Rutten [5] *et al.*, who reported 34% and 46% cases of rotator cuff tendon damage respectively.

The mean age of patients with cuff lesions was 27.6 years. Of the 11 patients with tendon ruptures, 63.63% were young adults under 35 years of age and 27.27% were adults over 35 years of age. Our results are similar to those of Flurin [14] (26.7 years), Kocher *et al.* [2], and Kaplan *et al.* [9], who found an average age of 25 years. However, this differs from Badr [6], who found that 66.66% of cuff tears were over 36 years of age. Other authors have also reported a higher mean age. Mall *et al.* [10] and Walcott *et al.* [11] reported mean ages of 54.7 and 47.9 respectively. Rotator cuff tears in young adults are most often associated with violent trauma, such as the direct impact on the shoulder stump, falls with the arm abducted and sports accidents [11] [12]. In an older population, cuff injuries most often occur following moderate trauma to an already weakened cuff, according to the literature [11] [12] [13] [14].

The male sex was the most represented, with a sex ratio of 3. Our results are comparable to those of Badr [6] who reported a sex ratio of 3, Ouédraogo [4] where it was 3.02, and Seidou [15] where it was 2.09. This finding can be explained by the fact that men engage in risky behaviors and activities that expose them more to accidents.

The circumstances in which trauma occurred were dominated by road traffic accidents (60%). Ouédraogo [4] noted that 73% of patients were victims of traffic accidents. This could be explained by the increase in the number of vehicles on the road in recent years.

Ultrasound was normal in 7 cases. No additional Magnetic Resonance Imaging (MRI) was performed in our series. Rutten *et al.* had noted 2 cases of normal ultrasound; these were confirmed by additional MRI [5]. In the literature, ultrasound findings are often comparable to those of MRI [7] [16] [8].

Tendon ruptures were the most frequent rotator cuff lesions (36.67%), followed by tendinitis (23.34%) and tendon disinsertion (10%). Rambert [1] found the same order of frequency, with 34% of tendon ruptures, 7% of tendinitis and 0% of tendon disinsertion. Rutten *et al.* found 46% tendon ruptures [5]. According to the literature, tendon ruptures are the most frequent form of rotator cuff injury [7] [16].

Pathological images of the rotator cuff included hypoechoic and anechoic tendon defects, hypoechoic tendons without associated defects, tendon thickening, loss of tendon fibrillation, tendon vascularization on Doppler and tendon flattening. Our results corroborate those reported in the literature [7] [17] [16] [18].

Non-transfixing ruptures were the most common in our series, accounting for 91% of cases versus 9% of transfixing ruptures. Rambert found 58% non-transfixing

ruptures and 42% transfixing ruptures [1], while Rutten *et al.* reported 57% transfixing ruptures and 43% non-transfixing ruptures [5]. Lesions depend on the severity of the impact and/or the condition of the tendon.

In our study, the supraspinatus was most affected (81.81% of cases). Our high rates of supraspinatus involvement are in line with the literature [8] [13] [19] [16].

Of our 20 patients with rotator cuff damage, radiographs were normal in 90% of cases. All patients with rotator cuff damage in Rambert's study [1] had normal radiographs. Clinicians' spontaneity in requesting standard radiographs is linked to the fact that, in trauma cases, there is a tendency to look mainly for bony lesions. However, systematic ultrasound can show traumatic lesions on normal radiographs, as demonstrated in our study and in those of Rambert [1] and Rutten *et al.* [5].

5. Conclusion

Ultrasound plays a vital role in the diagnosis of rotator cuff injuries in shoulder trauma in our context. These lesions are frequent and dominated by tendon ruptures, tendinitis, and deinsertions. Trauma to the shoulder occurs mainly in young adult males, and the main cause is road traffic accidents. Standard X-rays, which are indispensable in traumatology, are sometimes limited in the case of shoulder trauma, hence the importance of ultrasound. To improve patient care, ultrasound should be more widely prescribed for shoulder trauma. Ultrasound is almost as sensitive as MRI, so in our context, MRI should be reserved for cases of symptomatic shoulder trauma with normal radiography and ultrasound.

Conflicts of Interest

The authors declare no conflicts of interest regarding the publication of this paper.

References

- [1] Rambert, E. (2015) Utilité de l'échographie articulaire post-traumatique du membre supérieur et de la cheville: à partir d'une série monocentrique, continue et prospective de 87 cas. Ph.D. Dissertation, Université Grenoble Alpes, Saint-Martin-d'Hères. <https://dumas.ccsd.cnrs.fr/dumas-01259467>
- [2] Kocher, M.S. and Feagin Jr, J.A. (1996) Shoulder Injuries during Alpine Skiing. *The American Journal of Sports Medicine*, **24**, 665-669.
- [3] Neguesson, D. (2002) Etude des aspects épidémiologiques, lésionnels et thérapeutiques des traumatismes ostéo-articulaires de janvier en décembre 2000: À propos de 5127 cas. Ph.D. Dissertation, Université des Sciences, des Techniques et des Technologies, Bamako.
- [4] Ouédraogo, F. (2016) Les lésions ostéo-articulaires post traumatiques de l'épaule au center hospitalier universitaire Yalgado Ouédraogo. Ph.D. Dissertation, Université Joseph Ki-Zerbo, Ouaga.
- [5] Rutten, M.J., Collins, J.M., de Waal Malefijt, M.C., Kiemeney, L.A. and Jager, G.J. (2010) Unsuspected Sonographic Findings in Patients with Posttraumatic Shoulder

- Complaints. *Journal of Clinical Ultrasound*, **38**, 457-465.
<https://doi.org/10.1002/jcu.20745>
- [6] Badr, E. (2011) Les traumatismes de l'épaule à propos de 374 cas. Ph.D. Dissertation, Université Sidi Mohammed Ben Abdellah, Fès.
- [7] Bianchi, S., Noomane, M., Keller, A., Khan, H.G. and Garcia, J. (2000) Échographie des ruptures tendineuses. *Médecine et Hygiène*, **58**, 1491-1494.
- [8] Bianchi, S., Cohen, M. and Jacob, D. (2005) Les tendons: Lésions traumatiques. *Journal de Radiologie*, **86**, 1845-1856.
[https://doi.org/10.1016/S0221-0363\(05\)81534-3](https://doi.org/10.1016/S0221-0363(05)81534-3)
- [9] Kaplan, L.D., Flanigan, D.C., Norwig, J., Jost, P. and Bradley, J. (2005) Prevalence and Variance of Shoulder Injuries in Elite Collegiate Football Players. *The American Journal of Sports Medicine*, **33**, 1142-1146.
<https://doi.org/10.1177/0363546505274718>
- [10] Mall, N.A., Lee, A.S., Chahal, J., Sherman, S.L., Romeo, A.A., Verma, N.N. and Cole, B.J. (2013) An Evidenced-Based Examination of the Epidemiology and Outcomes of Traumatic Rotator Cuff Tears. *Arthroscopy: The Journal of Arthroscopic & Related Surgery*, **29**, 366-376. <https://doi.org/10.1016/j.arthro.2012.06.024>
- [11] Walcott, M.E., Daniels, S.D., Sinz, N.J., Field, L.D. and Higgins, L.D. (2017) Traumatic Full-Thickness Transtendinous Rotator Cuff Tears: A Case Series. *Journal of Shoulder and Elbow Surgery*, **26**, 62-67. <https://doi.org/10.1016/j.jse.2016.04.023>
- [12] Farron, A. (2000) Traitement chirurgical des ruptures de la coiffe des rotateurs. *Schweizerische Zeitschrift für Sportmedizin und Sporttraumatologie*, **48**, 24-27.
- [13] Nové-Josserand, L. (2009) L'épaule traumatique: Quelle épidémiologie, quelle lésion? *La Lettre du Rhumatologue*, **356**, 26-28.
- [14] Flurin, P.H., Guillemette, C., Guillo, S., Baudot, C., Nové-Josserand, L., Landreau, P. and Fontes, D. (2007) Ruptures traumatiques de la coiffe des rotateurs chez le rugbyman. *Journal de Traumatologie du Sport*, **24**, 203-206.
- [15] Guidah, S., Souna, B., Mamoudou, A. and Gana, A.A. (2013) La radiographie standard dans le bilan des traumatismes de l'épaule: A propos de 213 cas a l'hopital national de Niamey (Niger). *Mali Médical*, **28**, 41-45.
- [16] Guérini, H., Fermand, M., Godefroy, D., Feydy, A., Chevrot, A., Morvan, G. and Drapé, J. L. (2010) Aspect échographique des lésions non transfixiantes du tendon supra-épineux. *Revue du Rhumatisme Monographies*, **77**, 213-218.
<https://doi.org/10.1016/j.monrhu.2010.04.010>
- [17] Nicolas, S., Franck, L. and Denis, J. (2014) Echographie Musculo Squelettique. 2nd Edition, Elsevier Masson, Amsterdam, 381.
- [18] Beggs, I. (2011) Shoulder Ultrasound. *Seminars in Ultrasound, CT and MRI*, **32**, 101-113. <https://doi.org/10.1053/j.sult.2010.10.003>
- [19] Peetrans, P., Lemone, M. and Jeanmart, L. (1990) Echographie et pathologie traumatique de l'épaule: Coiffe des rotateurs et tendon de la longue portion du biceps. *Radiologie (Berlin)*, **10**, 177-181.