


Polymorphic Clinical Presentation of Crohn's Disease

Rachid El Jim^{1,2} , Oumaima El Abed^{1,2}, Asmae Lamine^{1,2}, Maria Lahlali^{1,2}, Hakima Abid^{1,2}, Amine El Mekkaoui^{1,2}, Mounia El Yousfi^{1,2}, Dafr-Allah Benajah^{1,2}, Mohammed El Abkari^{1,2}, Sidi Adil Ibrahim^{1,2}, Nada Lahmidani^{1,2}

¹Hepato-Gastroenterology Department, Hassan II University Medical Center, Fez, Morocco

²Faculty of Medicine, Dentistry and Pharmacy, Sidi Mohammed Ben Abdellah University, Fez, Morocco

Email: rachid.eljim@usmba.ac.ma

How to cite this paper: El Jim, R., El Abed, O., Lamine, A., Lahlali, M., Abid, H., El Mekkaoui, A., El Yousfi, M., Benajah, D.-A., El Abkari, M., Ibrahim, S.A. and Lahmidani, N. (2025) Polymorphic Clinical Presentation of Crohn's Disease. *Open Journal of Gastroenterology*, 15, 450-464. <https://doi.org/10.4236/ojgas.2025.158041>

Received: July 31, 2025

Accepted: August 22, 2025

Published: August 25, 2025

Copyright © 2025 by author(s) and Scientific Research Publishing Inc. This work is licensed under the Creative Commons Attribution International License (CC BY 4.0).

<http://creativecommons.org/licenses/by/4.0/>



Open Access

Abstract

Introduction: The clinical presentation of Crohn's disease is highly variable and often non-specific. Manifestations range from asymptomatic forms to severe and complicated presentations. Our objective is to analyze the clinical presentation of Crohn's disease in a sample of the Moroccan population and compare it with that of other regions around the world. **Materials and Methods:** We conducted a descriptive retrospective study over an 11-year period, involving a sample of patients diagnosed with Crohn's disease and followed in the Department of Hepato-Gastroenterology at our University Hospital. Several parameters were analyzed, including age, sex, the circumstances of diagnosis, delay of diagnosis and symptoms. **Results:** A total of 231 patients were included in the study, with a majority being female (60.6%). The mean age at diagnosis was 31.4 years (ranging from 7 to 68 years). The average delay between symptom onset and diagnosis was 16.7 months. Among the patients, 61% presented with chronic diarrhea as the main symptom, while 46% experienced abdominal pain. Koenig's syndrome was observed in 20% of the cases, and 14% had ano-perineal manifestations, mainly fistulas, in over 70% of these cases. Extraintestinal manifestations were reported in 19% of patients, with joint involvement being the most common (in over 80% of cases). Furthermore, 17% (n = 39) of patients presented with an initial complication of Crohn's disease, distributed as follows: 16 cases of intra-abdominal abscess, 12 cases of severe malnutrition, 4 cases of severe acute colitis, and 1 case of intestinal obstruction. **Conclusion:** The findings of this study highlight the marked variability in the clinical manifestations of Crohn's disease. Moreover, the significant delay between symptom onset and confirmed diagnosis underscores the need for increased awareness to enable earlier detection and optimal management.

Keywords

Inflammatory Bowel Disease (IBD), Crohn's Disease, Clinical Presentation, Morocco

1. Introduction

Crohn's disease is a chronic inflammatory condition of the digestive tract, belonging to the group of Inflammatory Bowel Diseases (IBD). It can affect any segment of the digestive tract, from the mouth to the anus, with a predilection for the terminal ileum and colon. According to recent epidemiological surveys, there are between 0.1 and 16 cases of Crohn's disease for every 100,000 people worldwide.

Compared to developing nations, industrialized nations have a notably higher prevalence of this condition [1]. However, recent epidemiological data indicate a growing incidence in regions such as the Middle East and North Africa, including Morocco [2]. This trend highlights the critical need to understand regional disparities in disease characteristics, given that the disease has a profound influence on patients' quality of life and the effectiveness of healthcare systems worldwide.

Previous studies have highlighted differences in the anatomical distribution of diseases, their clinical behavior, and concomitant extraintestinal manifestations, which are essential for modifying therapeutic approaches [3]. A recent case report described terminal ileum perforation as an initial manifestation of Crohn's disease, highlighting the potential for severe and atypical presentations at diagnosis [4]. Such findings reinforce the need to recognize the disease's diverse clinical patterns, especially in regions where intestinal tuberculosis can mimic Crohn's disease [5].

Furthermore, in nations characterized by middle-income status, such as Morocco, ailments like intestinal tuberculosis frequently pose significant diagnostic obstacles, thereby underscoring the imperative for localized data.

Research into its clinical presentation in different populations has become an essential field of study, due to the increasing global prevalence of the disease and the complex interaction between genetic and environmental factors influencing its phenotype.

Despite increased awareness of Crohn's disease in North African countries, there is little data defining the clinical characteristics of patients in Morocco. Nevertheless, studying these characteristics is imperative in order to adapt local medical practices and advance a more comprehensive understanding of the phenotypic manifestations of the disease. An enhanced delineation of clinical manifestations can additionally mitigate diagnostic postponements and facilitate the application of targeted therapeutic methodologies.

The aim of this study is to describe the clinical presentation of Crohn's disease in a Moroccan cohort and to compare it with findings from other regions, in order to identify potential regional disparities.

2. Methods

Over the course of 11 years, from 2013 to 2024, we carried out a retrospective descriptive study in our University Hospital Center's hepatogastroenterology department. According to current diagnostic criteria, all patients with a confirmed diagnosis of Crohn's disease based on clinical, biological, endoscopic, radiological, and/or histological evidence were included in the study.

The inclusion criteria included patients who were regularly monitored in the department during the study period, with a confirmed diagnosis of Crohn's disease and sufficiently detailed medical records. Incomplete or unusable records, cases of doubtful diagnosis, and patients with other forms of chronic inflammatory bowel disease, such as ulcerative colitis, were excluded from the analysis.

Koenig's syndrome was defined as postprandial colicky abdominal pain with audible borborygmi relieved after passage of gas or stool, suggestive of partial small bowel obstruction.

Severe malnutrition was defined according to the ECCO/ESPEN guidelines for clinical nutrition in inflammatory bowel disease [6], which consider severe malnutrition to be present when at least one of the following criteria is met: a Body Mass Index (BMI) below 16.5 kg/m², an unintentional weight loss exceeding 10% over 3 to 6 months, or a serum albumin level lower than 30 g/L in the absence of active liver or renal disease.

A case was classified as complicated at initial diagnosis if it met at least one of the criteria defined by the ECCO guidelines. Complicated presentation included the presence of an intra-abdominal abscess or collection confirmed by imaging (ultrasound, CT, or MRI) as a fluid collection with or without air bubbles, consistent with suppurative Crohn's complications. It also included severe malnutrition, as defined above, or severe acute colitis. Finally, cases of acute intestinal obstruction were considered complicated when patients presented sudden-onset abdominal pain with vomiting and radiological evidence of bowel dilatation with air-fluid levels in the absence of perforation, consistent with mechanical obstruction related to Crohn's disease.

The information gathered concentrated on the patients' sociodemographic traits, such as their age at diagnosis, gender, and place of origin. Clinical data included the time between the onset of initial symptoms and diagnosis, initial symptoms (such as chronic diarrhea, abdominal pain, weight loss, ano-perineal manifestations), the possible presence of complicated forms from the outset, as well as extra-digestive manifestations, particularly osteoarticular, cutaneous, ophthalmological, and hepatobiliary manifestations.

Paraclinical data, including the results of biological, endoscopic, and radiological examinations, were also taken into account. Finally, the circumstances of the diagnosis were analyzed, whether they involved scheduled consultations, hospitalizations, or emergency care.

All data were anonymized, entered into a dedicated database, and analyzed using appropriate statistical software (R software).

Data collection and analysis were conducted in strict compliance with the principles of the Declaration of Helsinki and in adherence to national and institutional regulations regarding patient confidentiality. All personal identifiers were removed to ensure data anonymity.

3. Results

3.1. General Manifestations

In addition to specific digestive and extra-digestive signs, several general manifestations were noted:

- Significant weight loss (>5% of body weight): 112 patients (48.5%)—often associated with chronic diarrhea, Koenig syndrome, or malnutrition.
- Long-term fever (>38°C, >1 week, with no other identifiable infectious cause): 7 cases (3%), suggesting a pseudo-infectious condition.

No additional extraintestinal manifestations were seen in our cohort, aside from the ophthalmological, dermatological, and osteoarticular symptoms mentioned above. Specifically, no instances of involvement of the liver, kidneys, lungs, brain, or heart were found.

3.2. Demographic Characteristics and Diagnostic Delay

A total of 231 patients with Crohn's disease were included in this study. The population comprised 60.6% women (n = 140) and 39.4% men (n = 91), with a male-to-female ratio of 0.65. At diagnosis, the average age was 31.4 ± 12.6 years, ranging from 7 to 68 years.

In terms of geographic origin, 45 patients (19.5%) came from rural areas, while 186 patients (80.5%) resided in urban areas.

Patients from rural areas typically experienced a longer diagnostic delay (18.7 months) than those from urban areas (16.2 months). though this difference was not statistically significant ($t = 1.12$, $p = 0.27$). No significant difference in diagnostic delay was observed by gender ($p = 0.42$) or age group (<30 vs ≥ 30 years, $p = 0.11$).

3.3. Initial Clinical Symptoms

Digestive symptoms

The main symptoms that prompted consultation were:

- Chronic diarrhea: observed in 141 patients (61%), often associated with malabsorption syndrome.
- Diffuse or localized abdominal pain, especially in the right iliac fossa, was reported by 106 patients (46%).
- Koenig's syndrome was documented in 46 patients (20%), reflecting partial functional obstruction and suggesting stenotic ileal involvement.
- Alteration of general condition (asthenia, anorexia, weight loss): noted in 103 patients (44.5%). **Figure 1** illustrates the distribution of these digestive symptoms at initial presentation.

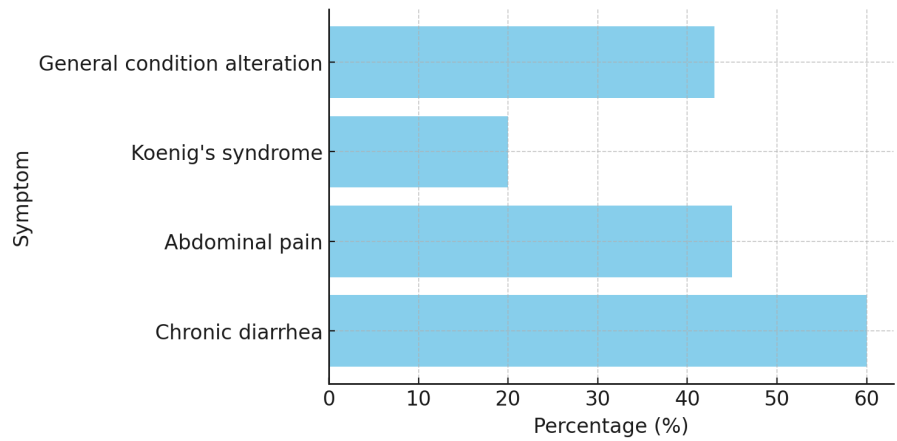


Figure 1. Digestive symptoms at initial presentation.

Ano-perineal involvement

Ano-perineal involvement was found in 32 patients (14%). Among these patients, several types of lesions were observed, sometimes in combination:

Anorectal fistulas: Observed in 23 cases (71.8% of anorectal lesions), representing the most common manifestation. These fistulas were mainly transsphincteric or intersphincteric and often complex.

Anal fissures: Identified in 3 cases (9.3%), located posteriorly in 100% of cases.

Perineal abscesses: Also present in 3 cases (9.3%), often associated with fistulas.

Anal stenosis: Reported in 2 cases (6.2%).

Edematous-fibrous marisks: Observed in 4 cases (12.5%).

Associated proctitis: Found in the majority of the remaining patients without typical anoperineal lesions. **Figure 2** illustrates the distribution of ano-perineal lesions.

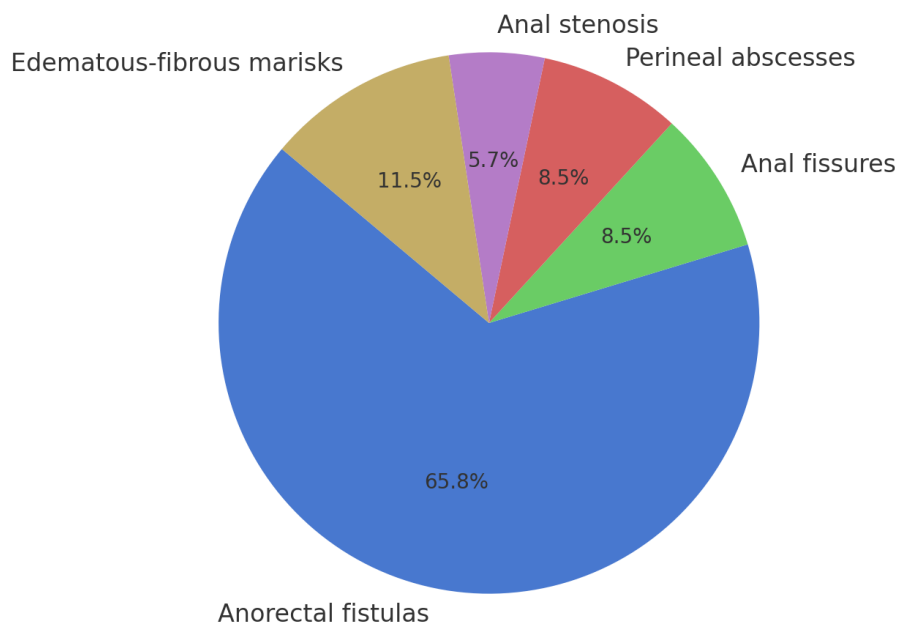


Figure 2. Distribution of ano-perineal lesions.

Extraintestinal manifestations

Forty-four individuals, or 19% of the study population, had extraintestinal manifestations. Musculoskeletal involvement was significantly the most common, accounting for more than 80% of the cases observed.

EIMs were significantly more frequent in males than females (31.1% vs 11.4%, $\chi^2 = 10.95$, $p = 0.001$).

Osteoarticular involvement

- Peripheral arthralgia (hands, wrists, knees, ankles): 26 cases.
- Acute non-erosive peripheral arthritis: 7 cases of the migratory oligoarthritis type.
- Sacroiliitis/suspected axial spondyloarthritis: 3 cases, suggested by inflammatory low back pain.

Dermatological condition

Suggestive skin lesions were observed in 5 patients:

- Erythema nodosum: 4 cases, located on the lower limbs.
- Pyoderma gangrenosum: 1 case.

Ophthalmological involvement

Ocular involvement was reported in 3 patients:

- Episcleritis: 2 cases, and one case of anterior uveitis treated jointly with the ophthalmology department.

Figure 3 illustrates the extraintestinal manifestations breakdown.

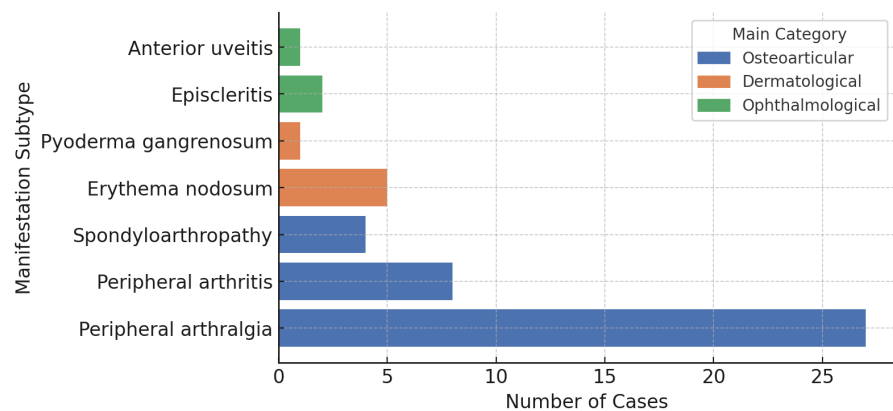


Figure 3. Extraintestinal manifestations breakdown.

Complicated presentation at diagnosis

A cohort of 39 patients (17%) presented with complications characteristic of Crohn's disease at the time of initial diagnosis. These particularly severe presentations included:

- Intra-abdominal collections: 16 cases (6.9%), identified by imaging, associated with microfistulous perforations in two cases.
- Severe malnutrition: 12 cases (5.2%), characterized by a body mass index below 16.5 kg/m² or serum albumin levels below 30 g/L.
- Severe acute colitis: 4 cases (1.7%), requiring intensive medical intervention.

- Acute intestinal obstruction: 1 case (0.4%), attributable to constrictive ileal stenosis.
- Complications were more frequent in males than females (27.5% vs 10.7%, $\chi^2 = 8.41$, $p = 0.004$).
- Rural origin was strongly associated with a higher complication rate (33.3% vs 12.9%, $\chi^2 = 7.54$, $p = 0.006$).

Figure 4 illustrates the complicated presentations at diagnosis.

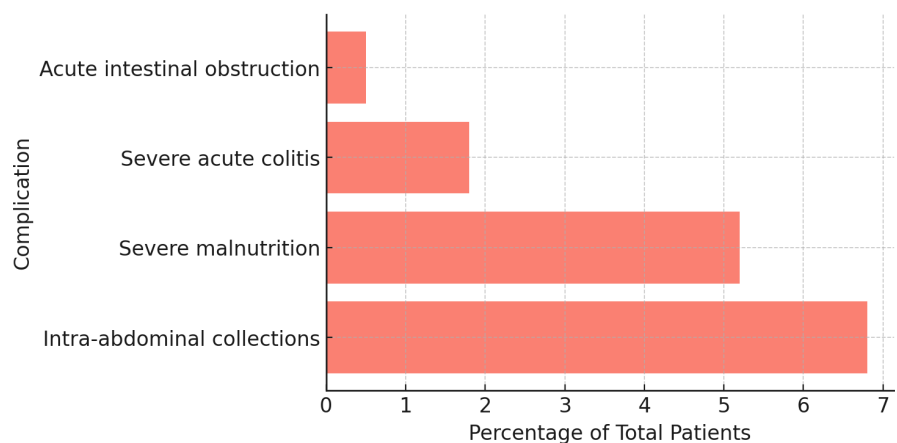


Figure 4. Complicated presentations at diagnosis.

4. Discussion

4.1. Geographic and Demographic Influences

Rural or urban residence

The study revealed that people living in rural areas experienced a longer delay in diagnosis (18.7 months) compared to their urban counterparts (16.2 months), although this disparity was not statistically significant ($p = 0.12$). Other studies support this finding by showing that patients in rural areas may encounter obstacles like restricted access to medical facilities and specialized practitioners, which could result in longer diagnosis times [7] [8].

Age and gender

The average age at which people are diagnosed is 31.4 years, with a predominance of female patients (60.6%). Other research suggests that women may face prolonged diagnostic delays, often associated with misdirection and systemic gender bias in healthcare [9].

4.2. Diagnostic Delay and Its Consequences

Late diagnosis of Crohn's disease is associated with more pronounced disease progression, including a high probability of intestinal complications and the subsequent need for surgery. Numerous studies confirm that prolonged delay exacerbates irreversible intestinal damage [10] [11].

There are many factors that contribute to diagnostic delays, such as subtle initial symptoms, misdiagnosis, or inefficiencies within the healthcare system. In addition,

isolated ileal lesions and extraintestinal manifestations are also associated with prolonged delays [12].

Even though the study emphasizes how demographic and geographic factors affect diagnostic delays, it is crucial to acknowledge the healthcare system's overall role in reducing these delays.

A delay of more than 12 months is regarded as a significant delay and is linked to an increased risk of intestinal complications and advanced forms of Crohn's disease. In Europe, the median time to diagnosis is estimated to be between 8 and 12 months [13].

Initiatives to improve early diagnosis and minimize delays could include raising awareness among healthcare professionals, improving access to diagnostic resources, and addressing systemic biases that perpetuate gender and geographic inequalities. Additionally, more research is required to look at the particular obstacles that women and rural populations face in getting a timely diagnosis and treatment for Crohn's disease.

4.3. Initial Clinical Symptoms

General manifestations

Weight loss is a common symptom of Crohn's disease, affecting approximately 48.5% of patients, often in conjunction with chronic diarrhea, malnutrition, or Koenig's [14]. The chronic inflammation and malabsorption disorders characteristic of Crohn's disease contribute to nutritional deficiencies, leading to progressive weight loss and muscle wasting [15]. Effective management of this weight loss relies on individualized nutritional support and control of inflammation through appropriate medical treatment [15].

About 3% of patients have a persistent fever. This symptom is often considered a pseudo-infectious manifestation, reflecting a systemic inflammatory response related to disease activity [14]. The presence of fever sometimes complicates the clinical picture, requiring a rigorous differential diagnosis to rule out possible infections or other inflammatory conditions [16].

Digestive symptoms

Gastrointestinal symptoms, such as chronic diarrhea, abdominal pain, and unintentional weight loss and conditions affecting the anal and perineal areas, are the main indicators of Crohn's disease's early symptoms. Accurate diagnosis is frequently delayed by these symptoms' variability and resemblance to other gastrointestinal disorders. To enable prompt diagnosis and efficient treatment plans, a more thorough comprehension of these early manifestations is necessary.

Clinical presentations in Africa are comparable to those reported in Western cohorts, with ano-perineal lesions like fissures, fistulas, and abscesses, anemia, and abdominal pain associated with ileal involvement often bloody. Fever, nausea, vomiting, and even childhood growth retardation are examples of systemic symptoms [17].

In our study, chronic diarrhea was one of the predominant initial manifesta-

tions of Crohn's disease, being documented in approximately 61% of people diagnosed with this disease. This symptom is often associated with malabsorption syndrome, which can lead to nutritional deficiencies and significant weight loss [16] [18]. This diarrhea tends to be nearly constant and is often accompanied by spasmodic or cramp-like pain [19].

Abdominal pain is observed in 46% of our patients, manifesting diffusely or locally, particularly in the right iliac fossa. This discomfort frequently results from an active inflammatory process or a subocclusive phenomenon associated with segmental involvement of the intestine [18] [20].

A global meta-analysis demonstrates that approximately 75% to 80% of patients experience abdominal pain at their first consultation [21].

Koenig's syndrome, characterized by postprandial abdominal pain accompanied by borborygmi and subsequent relief after the expulsion of gas or stool, is recognized in 20% of our study. This syndrome is indicative of stenotic involvement of the ileum and often indicates a stenotic progression (B2) according to the Montreal classification [18].

However, data from the African continent remain very limited in the literature due to the small number of published studies, which often take the form of isolated case reports or retrospective regional series.

Anoperineal involvement

In our Moroccan cohort (14%), the prevalence of anoperineal involvement was substantially lower than in other African studies (30% - 50%). Studies, where incidence rates typically range between 30% and 50% [22], and South Africa (up to 50%) [23]. In contrast, large European cohorts such as GETAID (France) and ENEIDA (Spain) report anoperineal involvement in approximately 20% to 30% of cases [24] [25].

Anorectal fistulas are the main manifestation of an anoperineal lesion, occurring in 71.8% of affected individuals. In our series, 69% of these fistulas were complex, frequently classified as transsphincteric or intersphincteric, thus presenting significant therapeutic obstacles [26].

Anal fissures and perineal abscesses are encountered less frequently, each being identified in approximately 9.3% of the patient population. These conditions are generally correlated with the presence of fistulas, which highlight a significant inflammatory attack on the perineum [18].

Anal stenosis is documented in 6.2% of cases, while fibrotic oedematous changes are observed in 12.5% of patients, reflecting the presence of localized chronic inflammation. Finally, proctitis associated with these conditions, even in the absence of classic anoperineal lesions, is frequently observed, suggesting inflammatory pathology of the rectal mucosa [18].

Osteoarticular involvement

More than 80% of cases in the study population have musculoskeletal disorders, making them the most prevalent Extraintestinal Manifestation (EIM) in Crohn's disease patients. This finding is consistent with data in the literature, which iden-

tify musculoskeletal manifestations as the most common EIM in chronic inflammatory bowel diseases [14] [26] including a recent Moroccan study in which 35% of Crohn's patients presented these symptoms [27]. Similarly, a meta-analysis conducted in the EMRO region (which includes North Africa) estimates that the prevalence of arthritis/arthralgia is approximately 13.5% in patients diagnosed with Crohn's disease [28].

Among these conditions, peripheral arthralgia was reported in 26 cases, while 7 patients had acute non-erosive peripheral arthritis of the migratory oligoarthritis type. In addition, sacroiliitis or suspected axial spondyloarthritis, suggested by inflammatory low back pain, was observed in 3 cases. These results are consistent with those of other studies, which highlight the frequency of peripheral arthritis as an EIM, often associated with active intestinal inflammation [29].

Dermatological manifestations

Dermatological manifestations have been reported in 5 patients, including 4 cases of erythema nodosum and 1 case of pyoderma gangrenosum. Erythema nodosum is frequently correlated with inflammatory bowel disease activity, while pyoderma gangrenosum can occur independently of intestinal inflammatory activity [29].

The prevalence rates observed (2.1% for erythema nodosum and 0.5% for pyoderma gangrenosum) are slightly lower than those documented in larger European cohorts. For example, in a cohort of 2402 people diagnosed with inflammatory bowel disease, erythema nodosum was identified in 4.0% of cases, while pyoderma gangrenosum was observed in 0.75% of cases, with a notable correlation with Crohn's disease, female gender, and, in the case of pyoderma gangrenosum, sometimes associated with African ancestry [30].

A recent review confirms that erythema nodosum and pyoderma gangrenosum are the two main skin manifestations in Crohn's disease, one synchronized with intestinal activity, the other capable of developing independently [31].

Complicated presentation at diagnosis

At the time of diagnosis, 17% of the study population had complications characteristic of Crohn's disease, such as intra-abdominal abscesses, severe malnutrition, severe acute colitis, or acute intestinal obstruction.

The relatively high incidence of complex pathological presentations tends to be partly explained by a significant diagnostic delay, frequently observed in scenarios where access to specialized medical care is limited or when initial clinical manifestations lack specificity. In fact, a longer time between the onset of symptoms and receiving a conclusive diagnosis encourages the disease's subtle progression toward more severe manifestations.

These findings are in line with previous research that emphasizes the detrimental effects of delayed diagnosis on the course of the disease and the frequency of complications at diagnosis. The presence of these serious manifestations highlights the importance of early screening and rapid management of Crohn's disease in order to prevent complications and optimize clinical outcomes for patients [32].

Although the study provides valuable information on the prevalence and types of clinical manifestations in Crohn's disease, it is important to take into account the variability of these manifestations between different populations and studies. Differences in the prevalence and clinical presentation of Crohn's disease may be caused by a number of factors, including genetic predisposition, environmental factors, and variations in disease management. Additionally, the literature highlights the necessity of a multidisciplinary approach and the significance of healthcare providers working together to maximize patient care [33].

Comparison with intestinal tuberculosis in Morocco

In Morocco, Intestinal Tuberculosis (ITB) remains endemic, especially in rural areas, and often mimics Crohn's disease, posing a significant diagnostic challenge. Differentiating between the two is critical, as management diverges fundamentally: ITB requires anti-tuberculosis therapy, whereas Crohn's disease relies on immunosuppressive treatment. Notably, it is increasingly dangerous to treat patients with actual Crohn's disease using ATT or to treat TB patients with immunosuppressants in a high-TB endemic setting like Morocco [34].

Local epidemiological data indicate that diagnostic delays in ITB in Morocco commonly fall within the 12 - 18 months range, comparable to the delays observed in our Crohn's cohort (16 - 18 months) and underscoring the real-world overlap with Crohn's diagnostic challenges [35].

Clinically, both diseases present with abdominal pain, chronic diarrhea, weight loss, and a high frequency of ileo-cecal involvement, making reliable discrimination difficult without advanced diagnostics [34].

However, specific features such as complex ano-perineal lesions (found in 13% of our patients) are rare in ITB, thereby favoring Crohn's disease when present [35].

Other manifestation

In our cohort, apart from the osteoarticular, dermatological, and ophthalmological manifestations described above, no other extraintestinal manifestations were identified. Specifically, there were no reports of cardiac, neurological, pulmonary, urinary, or hepatobiliary involvement.

The available epidemiological data, which show that these EIMs are well described in Crohn's disease but are still comparatively uncommon, are consistent with this absence. According to a systematic review, the prevalence of the most prevalent EIMs was only 0.7% for hepatobiliary involvement, 5% for skin involvement, 2% for eye involvement, and roughly 7.9% for joint involvement [36].

Depending on the study, the overall prevalence of at least one MEI in IBD patients ranges from 6% to 47%, while the estimated frequency of multiple MEIs ranges from 1% to 4% [2]. Even less common is pulmonary, neurological, or cardiac involvement, which typically affects fewer than 1% of patients [37].

Both the low prevalence of these manifestations in the general population and the lack of systematic screening in the absence of suggestive symptoms account for their absence in our series. These findings emphasize how crucial long-term clin-

ical monitoring is for spotting potential late-stage IBD-related issues.

5. Conclusions

The clinical picture of Crohn's disease in the Moroccan population is described in this study, emphasizing the variety and complexity of its symptoms. Our results confirm that persistent diarrhea and abdominal discomfort are the most common initial symptoms, while a significant proportion of patients present with anorectal and extra-digestive disorders.

Osteoarticular manifestations appear to be the main extraintestinal disorders, in line with regional and international findings. Conversely, the incidence of dermatological and ophthalmological manifestations remains relatively low. Our cohort did not document any cases of hepatobiliary, urinary, neurological, pulmonary, or cardiac involvement.

The average diagnosis delay, which is especially noticeable in rural areas, emphasizes the ongoing obstacles to early screening and probably plays a role in the high percentage of complex presentations at diagnosis (17%). This finding emphasizes how critical it is to raise clinical awareness, make specialized care more accessible, and employ the right diagnostic tools early on. In summary, these results imply that the clinical phenotype of Crohn's disease in Morocco has many similarities with international cohorts, while being shaped by regional characteristics, particularly with regard to access to healthcare.

They also highlight the need for concrete actions to reduce diagnostic delays, particularly through targeted training for general practitioners and improved access to endoscopic examinations in rural areas.

Conflicts of Interest

The authors declare no conflicts of interest regarding the publication of this paper.

References

- [1] Ng, S.C., Shi, H.Y., Hamidi, N., Underwood, F.E., Tang, W., Benchimol, E.I., *et al.* (2017) Worldwide Incidence and Prevalence of Inflammatory Bowel Disease in the 21st Century: A Systematic Review of Population-Based Studies. *The Lancet*, **390**, 2769-2778. [https://doi.org/10.1016/s0140-6736\(17\)32448-0](https://doi.org/10.1016/s0140-6736(17)32448-0)
- [2] Shehab, M., Azzam, N., Al-Bawardy, B., Abid, S., Bashandi, A., AlShihri, R., *et al.* (2025) P1260 Demographics and Clinical Characteristics of Inflammatory Bowel Disease in the Middle East and North Africa: A Multi-Nation Cross-Sectional (MIRAGE) Study. *Journal of Crohn's and Colitis*, **19**, i2280-i2281. <https://doi.org/10.1093/ecco-jcc/jjae190.1434>
- [3] Al-Fawzan, A.A., Al-Radhi, S.A., Al-Omar, A.S., Al-Mutiri, N.H., Al-Ammari, A.M., El-Gohary, M., *et al.* (2023) A Study of the Epidemiology, Clinical, and Phenotypic Characteristics of Inflammatory Bowel Disease in the Northern-Central Region of Saudi Arabia. *Diagnostics*, **13**, Article 2135. <https://doi.org/10.3390/diagnostics13132135>
- [4] Tadesse, R., Ewnte, B. and Tesfaye, K. (2022) Perforated Ileum as the Initial Presentation of Crohn's Disease, a Case Report. *International Journal of Surgery Case Reports*, **97**, Article ID: 107305. <https://doi.org/10.1016/j.ijscr.2022.107305>

- [5] Mei, P., Feng, W., Shi, P., Zhuang, Y. and Zhang, W. (2022) Clinical Research Progress of Crohn. *Journal of Biosciences and Medicines*, **10**, 35-46. <https://doi.org/10.4236/jbm.2022.108004>
- [6] Bischoff, S.C., Bager, P., Escher, J., Forbes, A., Hébuterne, X., Hvas, C.L., *et al.* (2023) ESPEN Guideline on Clinical Nutrition in Inflammatory Bowel Disease. *Clinical Nutrition*, **42**, 352-379. <https://doi.org/10.1016/j.clnu.2022.12.004>
- [7] Acehan, M.F., Yilmaz, V., Koç, Ö., Güvenir, S.T., Er, R.E., Soykan, A.İ., *et al.* (2025) P0385 Delayed Diagnosis in Inflammatory Bowel Disease in Turkish Population. *Journal of Crohn's and Colitis*, **19**, i873-i874. <https://doi.org/10.1093/ecco-jcc/jjae190.0559>
- [8] Diagnostic Delay in Adult Inflammatory Bowel Disease: A Systematic Review. <https://scispace.com/papers/diagnostic-delay-in-adult-inflammatory-bowel-disease-a-lym4ncq3>
- [9] Sempere, L., Bernabeu, P., Cameo, J., *et al.* (2023) Gender Biases and Diagnostic Delay in Inflammatory Bowel Disease: Multicenter Observational Study. *Inflammatory Bowel Diseases*, **29**, 1886-1894.
- [10] Nguyen, V.Q., Jiang, D., Hoffman, S.N., Guntaka, S., Mays, J.L., Wang, A., *et al.* (2017) Impact of Diagnostic Delay and Associated Factors on Clinical Outcomes in a U.S. Inflammatory Bowel Disease Cohort. *Inflammatory Bowel Diseases*, **23**, 1825-1831. <https://doi.org/10.1097/mib.0000000000001257>
- [11] Kiliç, V., Kivrakoglu, F., Ergin, M., *et al.* (2024) P302 Diagnostic Delayed is Associated with a Poor Prognosis in Patients with Crohn's Disease. *Journal of Crohn's and Colitis*, **18**, i670.
- [12] Fiorino, G. and Danese, S. (2016) Diagnostic Delay in Crohn's Disease: Time for Red Flags. *Digestive Diseases and Sciences*, **61**, 3097-3098. <https://doi.org/10.1007/s10620-016-4298-8>
- [13] Runde, J., Veseli, I., Fogarty, E.C., Watson, A.R., Clayssen, Q., Yosef, M., *et al.* (2023) Transient Suppression of Bacterial Populations Associated with Gut Health Is Critical in Success of Exclusive Enteral Nutrition for Children with Crohn's Disease. *Journal of Crohn's and Colitis*, **17**, 1103-1113. <https://doi.org/10.1093/ecco-jcc/jjad031>
- [14] De Felice, K.M. and Raffais, L.E. (2025) Extraintestinal Manifestations of Crohn's Disease. <https://scispace.com/papers/extraintestinal-manifestations-of-crohn-s-disease-ljimv2a88y>
- [15] Baêta, O.M., Alves, A.K., Moreno, J.M., *et al.* (2023) Doença de Crohn-uma revisão abrangente sobre a epidemiologia, fisiopatologia e patogênese, fatores de risco, diagnóstico clínico, diagnóstico imagiológico, manifestações extra intestinais, tratamento, nutrição e dieta. *Brazilian Journal of Health Review*, **6**, 17438-17454.
- [16] Errante, P.R. and Júnior, S.C.R. (2025) Doença de crohn, diagnóstico e tratamento. <https://scispace.com/papers/doenca-de-crohn-diagnostico-e-tratamento-45ppi58kfj>
- [17] Alegbeleye, B.J. (2019) Crohn's Disease in a Developing African Mission Hospital: A Case Report. *Journal of Medical Case Reports*, **13**, Article No. 80. <https://doi.org/10.1186/s13256-019-1971-5>
- [18] Ha, C., McGovern, D. and Melmed, G.Y. (2022) Crohn's Disease: Clinical Manifestations and Management. In: *Yamada's Textbook of Gastroenterology*, Wiley, 1294-1323.
- [19] Torres, J., Mehandru, S., Colombel, J. and Peyrin-Biroulet, L. (2017) Crohn's Disease. *The Lancet*, **389**, 1741-1755. [https://doi.org/10.1016/s0140-6736\(16\)31711-1](https://doi.org/10.1016/s0140-6736(16)31711-1)
- [20] Lind, E., Fausa, O., Elgjo, K. and Gjone, E. (1985) Clinical Manifestations. *Scandinavian Journal of Gastroenterology*, **20**, 665-670.

- <https://doi.org/10.3109/0036528509089192>
- [21] Colon Crohn Disease—An Overview.
https://www.sciencedirect.com/topics/medicine-and-dentistry/colon-crohn-disease?utm_source=chatgpt.com
- [22] Zouita, B. (2007) Epidemiological, Clinical and Evolutionary Profiles of Crohn's Disease. Doctoral Thesis, Faculty of Medicine and Pharmacy, Cadi Ayyad University, 145 P.
- [23] Hodges, P. and Kelly, P. (2020) Inflammatory Bowel Disease in Africa: What Is the Current State of Knowledge? *International Health*, **12**, 222-230.
<https://doi.org/10.1093/inthealth/ihaa005>
- [24] Amiot, A., Setakhr, V., Seksik, P., Allez, M., Treton, X., De Vos, M., *et al.* (2014) Long-Term Outcome of Enterocutaneous Fistula in Patients with Crohn's Disease Treated with Anti-TNF Therapy: A Cohort Study from the GETAID. *American Journal of Gastroenterology*, **109**, 1443-1449. <https://doi.org/10.1038/ajg.2014.183>
- [25] Ingle, S.B. and Loftus, E.V. (2007) The Natural History of Perianal Crohn's Disease. *Digestive and Liver Disease*, **39**, 963-969. <https://doi.org/10.1016/j.dld.2007.07.154>
- [26] Mazza, M. (2016) Clinical Presentation of Crohn's Disease.
<https://scispace.com/papers/clinical-presentation-of-crohn-s-disease-uajsb3k4um>
- [27] Rizkou, J., Aouroud, H., Lairani, F., Errami, A.A., Oubaha, S., Samlani, Z., *et al.* (2022) Extraintestinal Manifestations in Inflammatory Bowel Disease: About an Epidemiological Survey. *Scholars Journal of Applied Medical Sciences*, **10**, 2414-2418.
<https://doi.org/10.36347/sjams.2022.v10i12.056>
- [28] Momayez Sanat, Z., Vahedi, H., Malekzadeh, R. and Fanni, Z. (2024) A Systematic Review and Meta-Analysis of Extra-Intestinal Manifestation of Inflammatory Bowel Disease in the Eastern Mediterranean Region (EMRO) Countries. *Annals of Medicine & Surgery*, **86**, 2892-2899. <https://doi.org/10.1097/ms9.0000000000001543>
- [29] Faggiani, I., Fanizza, J., D'Amico, F., Allocca, M., Zilli, A., Parigi, T.L., *et al.* (2024) Extraintestinal Manifestations in Inflammatory Bowel Disease: From Pathophysiology to Treatment. *Biomedicines*, **12**, Article 1839.
<https://doi.org/10.3390/biomedicines12081839>
- [30] Farhi, D., Cosnes, J., Zizi, N., Chosidow, O., Seksik, P., Beaugerie, L., *et al.* (2008) Significance of Erythema Nodosum and Pyoderma Gangrenosum in Inflammatory Bowel Diseases: A Cohort Study of 2402 Patients. *Medicine*, **87**, 281-293.
<https://doi.org/10.1097/md.0b013e318187cc9c>
- [31] He, R., Zhao, S., Cui, M., Chen, Y., Ma, J., Li, J., *et al.* (2023) Cutaneous Manifestations of Inflammatory Bowel Disease: Basic Characteristics, Therapy, and Potential Pathophysiological Associations. *Frontiers in Immunology*, **14**, Article 1234535.
<https://doi.org/10.3389/fimmu.2023.1234535>
- [32] Pascual, M.B., Marín-Jiménez, I. and Bighelli, F. (2024) Manifestaciones extraintestinales y comorbilidades en la enfermedad inflamatoria intestinal. *Medicine—Programa de Formación Médica Continuada Acreditado*, **14**, 433-443.
<https://doi.org/10.1016/j.med.2024.04.015>
- [33] Doßow, L. and Arnim, U.V. (2019) Extraintestinale Manifestationen bei chronisch-entzündlichen Darmerkrankungen. *Der Klinikarzt*, **48**, 295-300.
<https://doi.org/10.1055/a-0969-1642>
- [34] Choudhury, A., Dhillon, J., Sekar, A., Gupta, P., Singh, H. and Sharma, V. (2023) Differentiating Gastrointestinal Tuberculosis and Crohn's Disease—A Comprehensive Review. *BMC Gastroenterology*, **23**, Article No. 246.
<https://doi.org/10.1186/s12876-023-02887-0>

- [35] MedCrave Online.
https://medcraveonline.com/GHOA/association-of-crohnsquos-disease-and-anal-tuberculosis-a-case-report.html?utm_source=chatgpt.com
- [36] Jose, F.A. and Heyman, M.B. (2008) Extraintestinal Manifestations of Inflammatory Bowel Disease. *Journal of Pediatric Gastroenterology and Nutrition*, **46**, 124-133.
<https://doi.org/10.1097/mpg.0b013e318093f4b0>
- [37] Yeo, M., Park, J.H., Kang, S.H., Moon, H.S., Sung, J.K., Jeong, H.Y., *et al.* (2023) What Are the Risk Factors for Extraintestinal Manifestations in Inflammatory Bowel Diseases? *Medicine*, **102**, e33031. <https://doi.org/10.1097/md.00000000000033031>