Open Access Library Journal
2025, Volume 12, e13983
ISSN Online: 2333-9721
ISSN Print: 2333-9705

Management of Osteoporotic Disease in Dentistry

Omar Ziyati[1], Aya Sidqui[2], Said Hermas[3], Mustapha Sidqui[4]

[1]Department of Periodontology, Faculty of Dental Medicine of Casablanca, Hassan II University of Casablanca, Casablanca, Morocco
[2]Faculty of Medicine and Pharmacy of Casablanca, Mohammed VI University of Sciences and Health, Casablanca, Morocco
[3]Department of Genecology, Faculty of Medicine and Pharmacology of Casablanca, Hassan II University of Casablanca, Casablanca, Morocco
[4]Dental Emergency Service, Faculty of Dental Medicine of Casablanca, Hassan II University of Casablanca, Casablanca, Morocco
Email: m.sidqui6@gmail.com

How to cite this paper: Ziyati, O., Sidqui, A., Hermas, S. and Sidqui, M. (2025) Management of Osteoporotic Disease in Dentistry. *Open Access Library Journal*, **12**: e13983.
https://doi.org/10.4236/oalib.1113983

Received: July 19, 2025
Accepted: November 25, 2025
Published: November 28, 2025

Copyright © 2025 by author(s) and Open Access Library Inc.
This work is licensed under the Creative Commons Attribution International License (CC BY 4.0).
http://creativecommons.org/licenses/by/4.0/
Open Access

Abstract

The osteoporosis is a disease characterized by a low osseous mass and a deterioration of the architecture of the bone, leading to an increased osseous brittleness and an increased risk of fracture, whose incidence increases with the age. Approximately 40% of women aged 50 years or older are at risk of at least an osteoporotic fracture. The frequency of these fractures is in constant increase, primarily because of the continuous aging of the population. One can from now on precociously identify the disease thanks to the osteodensitometry, which measures the osseous mineral density. The age and the menopause are the two principal determinants of the osseous loss. The factors of risk are mainly the family antecedents and the oestrogenic deficiency. The purpose of the preventive treatments of the osteoporosis is to prevent the osseous loss by slowing down the osseous replanning, which accelerates after the menopause. The curative treatments seek to increase the osseous mass and to prevent new fractures without deteriorating the quality of the bone. The dentist must take into account the existence of an osseous pathology that affects fabrics of support of the tooth and the resistance of the jawbones. The disease prevention of the oral loss of osseous tissue passes by the maintenance of the dental bodies, which requires measurements aiming at eliminating the carouses and periodontal affections (mainly reductions in the sugar consumption and the elimination of the dental plaque). The treatment will be a complete restoration of teeth: 1) Descaling known and under gingival: Will have to be accompanied by a perfect cleaning of the root in order to avoid any bacterial proliferation? Correction of the badly positioned teeth. 2) Correction of the badly adjusted caps

and the overflowing restorations. 3) Suppression of the trauma occlusal. 4) Maintenance by means of application of the mobile teeth. 5) Regular maintenance. 6) Extractions atromatic. 7) Regularization of peak to the tiniest possible to preserve its capital osseous present. 8) Well-adapted and controlled prostheses.

Subject Areas

Dentistry

Keywords

Osteoporosis, Menopause, Odontology, Maxillary

1. Introduction

In recent years, osteoporosis has seen considerable advances in diagnostic and therapeutic management, benefiting from the interest it receives from the scientific community.

The concept of bone fragility is currently based on both a quantitative and qualitative approach. Understanding it requires a reminder of its current pathophysiological and epidemiological importance.

Indeed, osteoporosis is a general skeletal disease characterized by low bone mass and alterations in the microarchitecture of bone tissue, leading to increased bone fragility with a risk of fracture. It is a particularly concerning condition, its frequency has increased in recent decades due to the aging of the population.

Aside from secondary osteoporosis, which responds to its own pathophysiological mechanisms, postmenopausal osteoporosis has seen increased interest in recent years, both from the medical community and the general public. Age and menopause are the two main, but not exclusive, determinants of bone loss leading to osteoporosis.

Osteoporosis will have consequences in each of the disciplines that make up our practice, from surgery to prosthetic reconstruction, from periodontics to dentofacial orthopedics, but especially in disciplines related to bone structures.

2. In Conservative Dentistry

2.1. Caries and Osteoporosis

Unrelated to osteoporosis, caries is frequently the cause of periapical infection. Often, the infection leads to alveolar bone loss. Two cases arise:

- After anti-infective treatment, this bone loss is reversible in 90% of cases.
- Sometimes, tooth extraction is necessary, and the alveolar bone loss is irreversible.

The consequences of periapical infection are direct, but they are modulated by the patient's attention to their oral health [1].

2.2. Precautions to Take

Prophylaxis involves maintaining dental organs. This requires a wide variety of measures aimed at eliminating caries and periodontal disease, primarily reducing sugar consumption and removing dental plaque. Increasingly, importance is being attached to a balanced diet rich in calcium and protein [2].

3. In Periodontology

3.1. Periodontal Disease and Osteoporosis

Osteoporosis and osteopenia can have an impact on tooth loss and periodontal disease. Medications such as Hormone Replacement Therapy (HRT), which slows the rate of bone loss in the hip, also appear to reduce the rate of alveolar bone loss in postmenopausal women. Compared with calcium and vitamin D, HRT use is proportional to greater tooth preservation [3]-[6].

However, it has been shown [7] that a high intake of calcium and vitamin D is accompanied by a significant reduction in attachment loss and thus a reduced risk of tooth loss in these osteoporotic patients.

Several studies have attempted to find a possible correlation between osteoporosis and periodontal status.

- El-Desouki *et al.* [8] showed in a study of 208 women aged 60 to 69, a relationship between periodontitis and tooth loss, which leads to alveolar bone loss.
- El-Desouki *et al.* demonstrated [8] a strong correlation between osteoporosis and periodontitis.
- Djouajdi-Arama *et al.* [7] found that postmenopausal women receiving hormone replacement therapy have good periodontal health compared to those not treated.
- Sanfilippo *et al.* [3] showed that spinal fractures in postmenopausal women are associated with periodontal disease and suggested that periodontitis may be aggravated in osteoporotic subjects.

A study involving a population of 228 women (50 - 60 years old) [7] showed that the HRT (Hormone Replacement Therapy) group experienced less bleeding on probing than the control group.

Osteoporotic/osteopenic women exhibit an exaggerated inflammatory response to dental plaque [7] [8]. The fact that this exaggerated inflammatory response is observed primarily in osteoporotic/osteogenic patients with estrogen deficiency confirms the anti-inflammatory role of estrogens. Indeed, estrogens have an inhibitory role on the production of inflammatory mediators such as IL-1, TNF-alpha, and IL-6. After menopause, serum IL-1 levels are indeed increased in both osteoporotic and non-osteoporotic women [9]. While IL-1 activity in unaffected women spontaneously returns to premenopausal levels within seven years of menopause, in osteoporotic patients, it persists for up to 15 years after menopause [7]. Djouajdi-Arama *et al.* [7] showed that HRT reduced IL-1 levels in the gingival fluid of postmenopausal women with progressive periodontitis. These studies therefore support the hypothesis that estrogen deficiency increases the amounts of inflam-

matory factors at the periodontal level and, consequently, alveolar bone resorption.

Current data are not sufficient to prove that estrogen deficiency is a factor in the aggravation of periodontal disease. However, there is a group of osteoporotic women who could constitute an at-risk group because they are hypersecretors of certain cytokines, the same ones involved in the destruction of periodontal tissue.

Treatment of periodontal disease appears essential in osteoporotic patients. Bone resorption requires the breakdown of type I collagen, which is found in large quantities in the bone structure. This breakdown occurs upon contact with bacterial collagenase or protease, which are strongly implicated in periodontal disease.

3.2. Precautions to Take

In osteoporotic patients, we note [10]:

- The existence of fragile alveolar bone with faster bone loss, therefore a higher risk of tooth mobility.
- The risk of developing periodontal pockets is greater compared to that of normal subjects.
- The risk of attachment loss is higher.
- Due to the decrease in estrogen levels: hyposialia and a decrease in IgA levels, therefore the risk of infection and inflammation is higher (gingivitis, often erythematous, and periodontitis).

It is deduced that the risk of developing periodontal disease is higher in osteoporotic subjects compared to normal subjects, with a much more rapid progression, which requires special care in these patients.

It is recommended to reinforce the motivation for hygiene in these osteoporotic subjects. Patients who regularly consult their practitioner have significantly better hygiene standards, less bleeding, and fewer deep pockets [10].

In the short term, prevention can largely prevent gingivitis. It therefore helps prevent the progression of gingivitis to periodontitis.

In the medium term, we can hope to reduce the number of periodontal lesions and stabilize treated periodontitis [10]. Long-term results should allow, if not the eradication of the disease, at least a reduction in the number of cases [10].

Removing bacterial plaque from the dentogingival region is the most effective method for preventing gingivitis and periodontitis. This prevention begins with well-instructed hygiene measures and the use of complementary devices [10].

Beyond the scope of plaque prevention and control strategies, there are two types of therapeutic approaches in periodontology: non-surgical treatments and surgical treatments. Broadly speaking, these therapeutic methods aim to eliminate ecological niches for plaque and better control its formation. New approaches aim to regenerate lost tissue [10].

- **Non-surgical treatments**

Non-surgical treatments for periodontitis involve cleaning the dental surfaces to which plaque and tartar adhere by supra-subgingival scaling. This work is usually

followed by subgingival curettage/planing of the dental side of the periodontal pockets. Planing removes the superficial layer of contaminated tissue. It helps reduce the roughness that promotes the persistence of deposits.

Due to the low bone quality and quantity in osteoporotic patients, these treatments must be performed regularly to prevent potential complications and atraumatically to avoid fracturing the alveolar bone plates [10].

- **Surgical treatments**

According to Garcia (1995) [11], in addition to gingival and periodontal damage, the dentist must also be aware of the risks of general demineralization of the alveolar bone, which occurs in osteoporosis, especially after menopause. It is clear that no surgical treatment will be undertaken on this demineralized periodontium until the treating physician controls the calcium situation.

Due to bone demineralization, any bone surgery should be avoided in these osteoporotic patients, if necessary, this surgery can be performed minimally [2]. Pre-prosthetic surgical techniques may be indicated in cases of prosthesis instability. The main pre-prosthetic surgical techniques aim either to recreate a bony relief by detaching the periosteal musculature and deepening the vestibular grooves and/or the floor of the mouth, or to raise the resorbed ridges by implanting biomaterials, currently most commonly calcium hydroxyapatite granules [2].

- **Maintenance of the result**

In osteoporotic patients, multiple follow-up and maintenance sessions are required due to the severity and rapid progression of periodontal disease in these subjects [10].

Maintenance consists of preventing plaque formation through supportive periodontal treatment, following a series of surgical or non-surgical therapies.

This involves:

- Preventing the transformation of gingivitis into periodontitis (primary prevention). This is called preventive maintenance. Patient education and training in oral hygiene techniques are the main goals of this type of maintenance.
- To prevent the recurrence of periodontitis after treatment (secondary prevention). In this case, it is called post-treatment maintenance. It aims to keep plaque levels at a minimum. In addition to hygiene instructions, professional cleanings and root planing will be performed at regular intervals. Local chemotherapy and subgingival irrigation after debridement will ensure continued healing.
- To prevent, slow, or halt the progression of periodontal disease (palliative maintenance) in patients who cannot receive appropriate care, either due to lack of compliance, poor hygiene, or general changes in the body that cannot be treated (immune system deficiency).

4. In Surgical Dentistry

Due to bone atrophy, there is an increased risk of mandibular and tuberosity fractures. Indeed, the cortices are thinned and porous, and the trabeculae are rarefied and disconnected. Fractures, however, remain rare in the elderly. They are the result

of reductions in temporomandibular dislocations and the avulsion of disimpacted or impacted wisdom teeth in osteoporotic patients. Bone consolidation is slow and difficult, and the very frequent edentulism further complicates treatment [2].

Replacement of extracted dental roots with biomaterials, such as hydroxyapatite, has not proven very effective in preventing alveolar bone resorption. The transformation of particles into bone tissue remains questionable, and healing has not been proven histologically. Thus, preserving even the slightest bone relief must be a priority for clinicians concerned about preserving this essential supporting tissue for prostheses. All authors emphasize this point. This is a true "tissue-saving strategy" that practitioners must constantly keep in mind during their daily practice [2].

Extraction must strive to preserve the alveolus as much as possible using a suitable, atraumatic technique, absolutely avoiding any excessive pressure (elevating movement), crushing the bone cortex and preserving the interradicular septum through judicious root separation [2].

Multiple dental extractions must be avoided; if necessary, an atraumatic method, such as splitting multi-rooted teeth, may be used. The risk of mandibular and tuberosity fractures increases in the case of multiple extractions [2].

Alveolectomy, if necessary, must be performed quickly but with rigor and discernment. The rate of resorption after alveolectomy can reach twice that which occurs after a simple extraction, in addition, the resorption continues longer and more intensely [2].

Dry socket must be prevented by properly administered anesthesia, the removal of any sequestrum, and control of the alveolar wound [2].

Ridge regularization should not be systematic, but rather performed cautiously and only when deemed essential.

- **Trauma**

Despite the decrease in bone mineral density and cortical thinning, fractures in osteoporotic patients are rare. Their slow healing is difficult [2].

Spontaneous mandibular fracture occurs in patients who have undergone significant bone loss. The following panoramic dental X-ray demonstrates the obvious problem of orofacial rehabilitation in this type of patient (**Figure 1**) [1].

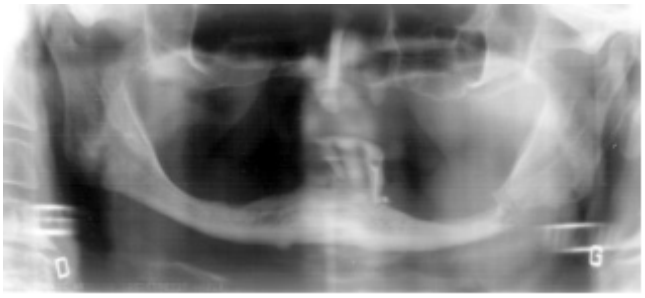

Figure 1. Panoramic dental radiograph showing a mandibular fracture in a 70-year-old osteoporotic patient (M. SIDQUI).

As a preventive measure, note that a short-term study showed that taking calcium and vitamin D supplements during the extraction period reduced post-extraction bone resorption by 36% [1].

Complications in osteoporotic patients

- **Risk of alveolar and mandibular fracture**

The risk of mandibular and alveolar fracture increases in osteoporotic subjects due to bone fragility and the high percentage of edentulism in these subjects [8].

- **Decreased trabecular bone mass leading to decreased chewing strength**

A study was conducted on the effects of estrogen on alveolar bone in a group of 6-month-old rats that underwent ovariectomy and subsequent extraction of their maxillary first molars. The surfaces of the maxillary bone were dissected and examined by scanning electron microscopy to indicate the bone-forming and resorptive areas. The results showed that acute estrogen deficiency induced by ovariectomy stimulates resorption of supporting bone but has less effect on bone formation [12].

According to Pagni *et al.*, the alveolar ridge is composed of basal bone and alveolar bone, only the latter being located around the teeth. During aging and with extractions, alveolar bone tends to decrease in volume through its continuous remodeling, unlike basal bone, which does not appear to change significantly [13]. Alveolar bone resorption occurs horizontally and vertically according to a known pattern; in the posterior maxillary regions, resorption attacks the vestibular aspect more. Healing occurs centrally within the alveolus, and is accompanied by resorption at the marginal level [14].

Furthermore, the quality of the surgical extraction procedure is a major factor in the subsequent resorption [1].

- **Risk of infection**

Menopause is accompanied by a decrease in estrogen hormone levels, which leads to dry mouth due to salivary gland atrophy, which results in a decrease in IGA levels, and therefore a decrease in local defense mechanisms in the oral cavity [7].

- **Risk of osteoradionecrosis linked to bisphosphonates** (**Figure 2**)

Figure 2. Case of a patient with bisphosphonate-related mandibular osteonecrosis (M. SIDQUI).

Since autumn 2004, the Geneva University Hospitals have sent Swissmedic thirteen pharmacovigilance reports concerning maxillary osteonecrosis in patients treated with bisphosphonates, both for neoplastic complications (10 cases) and osteoporosis (3 cases). Zoledronic acid (7 cases), pamidronate (7 cases), and alendronate (Fosamax®, 3 cases) were involved. One patient received etidronate (Didronel®) and another clodronate (Ostac®), followed by pamidronate and zoledronate intravenously. Two osteoporotic patients received only oral alendronate. The duration of treatment ranged from 6 months to 7 years. The medical literature has reported over a hundred similar cases.

In February 2005, Novartis [15] had collected 875 cases of osteonecrosis of the jaws in patients undergoing bisphosphonate treatment. Since then, 182 additional cases of this side effect, first reported by Marx in 2003, have been published. Parenteral bisphosphonate therapy with very high antiresorptive potency (zoledonic acid, pamidronate, alendronate) is primarily associated with the occurrence of this complication.

Although the exact mechanism underlying osteonecrosis remains to be confirmed, it is known that bisphosphonates are potent inhibitors of osteoclastic activity, increase bone mineralization, and reduce bone vascularity, all of which reduce the potential for repair and remodeling. Bone may become highly mineralized and dense and unable to meet the remodeling demands following trauma, ultimately leading to necrosis. Trauma caused by tooth extraction, poorly fitting prosthetics, periodontal and dental disease, and systemic factors (e.g., oral infections, poor oral hygiene, and medical conditions) can increase the risk of osteonecrosis. Spontaneous oral complications have been reported, and although the lesion may be asymptomatic, the most common initial complaints include intraoral pain and roughness due to bone exposure [15].

Osteonecrosis manifests as bone exposure in the oral cavity, most often following a dental procedure (tooth extraction, curettage), but can also occur spontaneously and unrelated to a prosthetic injury. Spontaneously, the exposed bone progresses to necrosis, which can affect large areas of the mandible (two-thirds of cases) or the maxilla (one-third of cases). The loss of all or part of a maxilla then has dramatic functional and aesthetic consequences, given the limited possibilities for rehabilitation.

This complication occurs mainly in patients receiving high-dose bisphosphonate therapy for the treatment of multiple myeloma and the control of bone metastases from breast and prostate cancer. Sporadic cases have also been described in women treated for osteoporosis, including with oral administration.

To reduce the incidence of all the complications mentioned above, several methods are available during various surgical procedures [16]:

1) Preoperative analysis of the situation will allow the selection of an indicated technique that is predictable, reliable, and reproducible by the practitioner. Explaining the various surgical procedures and expected outcomes to the patient will improve their intraoperative cooperation and reduce potential subjective complications.

2) Mastering the technical procedure, taking into account local anatomical characteristics, and using appropriate intraoperative equipment will determine the success of the procedure.

3) Providing postoperative advice, combined with adherence to prescribed medication, has a positive impact on postoperative outcomes.

5. In Removable Dentures

5.1. Osteoporosis and Edentulism

A study by Kozlowski [17] was conducted on 81 postmenopausal women divided into three groups: the first (group I) was normal (n = 29), the second (group II) was osteopenic (n = 27), and the third (group III) was osteoporotic.

The rate of women using dentures in groups II and III is much higher than that of non-osteoporotic women. The predominant type of prosthesis in the maxilla and mandible is partial dentures; however, no statistical differences were found regarding the results of periodontal measurements. In conclusion, the reduction in bone mass of the masticatory organs leads to the loss of permanent teeth and increases the demand for dentures in postmenopausal women [16].

Another study conducted in 2004 [16] aimed at knowing the relationship between craniomandibular disorder and bone mineral status at the skeletal level. It was carried out in 335 women aged 48 to 56 years. Bone mineral density was measured in 3 regions of the mandible. 77 women presented symptoms of craniomandibular dysfunction. The results suggested that the habits and conditions that cause the decrease in skeletal bone mineral density may hinder the functional harmony of the masticatory system and thus increase the risk of craniomandibular disorder. After extraction of one or more teeth, the alveolar portion of the maxilla begins to atrophy. This can be quantified by a resorption rate known as "Residual Ridge Resorption" (RRR). This resorption is assessed through clinical examination, inspection, and palpation, as well as dental radiographs. However, inspection and palpation are not or only slightly quantifiable. The decrease in bone mass was correlated with tooth extraction and therefore with chewing strength. Early tooth loss is responsible for atrophy of the masticatory muscles [1].

5.2. Precautions to Take

It can be deduced that the impact of osteoporosis on prosthetic reconstruction can be summarized as:

- The subsidence of the bearing surfaces leads to prosthetic instability.
- The fragility of the mandibular mucosa, which is no longer a stable attached gingiva but an unstable free gingiva, is highly sensitive to prosthetic trauma.
- The extraosseous exposure of the mental nerve, which becomes a prosthetic obstacle.

- **During the prosthesis development period** [16]

The technique used during primary and secondary impression taking must not excessively stress the peripheral tissues, which could result in slight underlying

osteolysis, however sufficient to lead to a decrease in the adhesion of the maxillary prosthesis.

The intermaxillary relationships, vertical occlusion dimension, sufficient free space for inocclusion, and centric relation will be carefully determined. Articulator adjustments (after positioning the maxillary model, using a facebow) must result in satisfactory stability of the prostheses without harmful effects on the TMJs, muscles, and subprosthetic mucosal and bony tissues. Primary and then secondary balancing, along with regular monitoring, will ensure the sustainability of intermaxillary relationships. The use of porcelain teeth can also contribute to this.

Regarding the choice of teeth, resin teeth are used. According to a study [8], the difference between the values recorded with resin teeth and porcelain teeth is small for a low force: resin teeth are slightly more effective. However, porcelain teeth gain the advantage as soon as the bite force reaches approximately 70 to 80 N, *i.e.*, values comparable to the average forces recorded during chewing in fully edentulous patients with braces. The results are always very similar except for an 80% deformation, for which resin teeth require significantly more force.

In conclusion, in osteoporotic patients, muscle tone is low and chewing force is low; resin teeth are then used as removable prostheses in these patients.

- **Post-prosthetic measures**

Any traumatic injury to the peripheral and subprosthetic tissues requires verification of the occlusion, followed by correction of overextension and excessive pressure. The appearance of a gap between the intrados of the prostheses and the underlying tissues requires further rehabilitation of the bases. Inflammation of the mucosa, or prosthetic stomatitis, must be treated promptly (antiseptics, antifungals, etc.), otherwise, underlying osteolysis may develop [18].

The hygiene recommendations prescribed by the practitioner must be followed: regular brushing of the mucous membranes, tongue, and ridges (7/100 brush), multiple daily brushing of the prosthesis, weekly disinfection of the prosthesis (chlorhexidine, water with 2 or 3 drops of hypochlorite solution), and refraining from wearing the prosthesis for 8 hours out of 24 hours (not necessarily at night). The harmful role of tobacco and alcohol on the oral mucosa will be emphasized. These will be very carefully and regularly examined, two or three times a year. Any suspicious lesion must be diagnosed and treated without fail. It must always be kept in mind that preserving the mucosa from inflammatory or infectious phenomena or trauma contributes to limiting bone resorption [17].

6. In Dentofacial Orthopedics

6.1. Osteoporosis and Bone Remodeling

Bone remodeling must adapt both to the maintenance of calcium-phosphorus homeostasis and to orthostatic and functional biomechanical requirements. The orthodontist will utilize the properties of orthostatic and functional biomechanics. The orthodontist will use the properties of orthodontic biomechanics to create certain dental and alveolar movements [19].

W.E. Roberts demonstrated the importance of understanding host bone response mechanisms in orthodontic treatment planning.

The osteoblast is, as we have shown, the cell of bone formation. It is recognized that moderate loading applied to bone leads to hyperdifferentiation of this cell lineage followed by bone hypertrophy. Conversely, the weightlessness of spaceflight inhibits its differentiation.

Frost modeled bone response to various stresses. From extreme cases such as hypostimulation leading to bone atrophy to spontaneous fracture beyond the elastic phase of the bone, he created a theoretical model that can vary within the same individual. This is why it seems essential to evaluate patients by consulting the dentofacial orthopedics department for malocclusion or dysmorphosis. Orthodontic tooth movement and bone remodeling activity depend on systemic factors such as dietary factors, metabolic bone diseases, age, and the use of certain drugs [20].

Systemic hormones such as androgens, estrogens, and calcitonin are associated with an increase in bone mineral content, bone mass, and a decrease in the rate of bone resorption. Consequently, they may delay orthodontic tooth movement. Conversely, thyroid hormones and corticosteroids may be involved in rapid orthodontic movement and lead to a less stable result. Drugs such as bisphosphonates, vitamin D, and fluoride may likely lead to a reduction in tooth movement after orthodontic force [19] [21].

Nonsteroidal anti-inflammatory drugs have also been shown to reduce bone resorption. Long-term administration of these drugs may therefore delay the necessary response of the bone to the pressure involved. Attention was also focused on the effect of prostaglandins and leukotrienes in orthodontic movement; it appears that there may be new future clinical applications that will result in an acceleration of orthodontic movement. The use of these drugs should be considered by every dentist in the evaluation of the time as well as in the planning of orthodontic treatment [22].

A study conducted by Montoya-Carralero *et al.* [23], involving 16 patients (3 men and 13 women) over 50 years of age, showed success of orthodontic treatment both functionally and aesthetically in both sexes, but this provided they had a healthy periodontium and adequate residual dentition.

6.2. Precautions to Take

An osteoporotic patient often presents with the following clinical features:

- A reduced number of teeth is associated with weakened bone support.
- Masticatory pressure is exerted on a reduced number of teeth (an increased pressure-to-surface ratio).
- A bone healing problem.
- A healthy or reduced periodontium, associated with one or more occlusal prematurities, is often considered a "biological impossibility" for orthodontic treatment.

Orthodontic movement depends on both the anatomical characteristics of the

bone (ridge height, trabecular and cortical structure) and physiological characteristics (bone turnover, balance between formation and resorption, periodontal health).

Osteoporotic bone loss can, in extreme cases, be aggravated by poor periodontal health. Orthodontics can then promote easier plaque control and theoretically slow down osteo-rarefaction [19].

From all these data, we conclude that there are two problems that can be encountered in an osteoporotic patient undergoing orthodontics:

- Instability of orthodontic treatment results.
- More accelerated orthodontic movements compared to normal subjects.

Management:

- Patient preparation: Any periodontal pathology must be eliminated before starting orthodontic treatment. When teeth are mobile, it is difficult to achieve satisfactory orthodontic anchorage [24].
- Reduced force application: In osteoporotic patients, there is an acceleration of orthodontic movement compared to normal patients [22].

7. In Implantology

Osteoporosis and Implant Failure

If age and sex are indeed risk factors for osteoporosis, the rate of implant failure due to poor osseointegration should increase accordingly in a large portion of the population over 50 years of age, particularly in women [24]-[27].

Hellstein *et al.* [28] showed that the total reduction in skeletal mass is directly correlated with the decrease in mandibular bone density in osteoporotic women.

Kloss *et al.* [29] reported, in a study of 28 edentulous women, significantly greater bone loss in the jaw in osteoporotic women compared to those of the same age without osteoporosis.

In a 2005 study, Jeffcoat [30] assessed the risk of implant failure by separating 45 women and 18 men over 50 years of age and 48 women and 18 men under 50 years of age by age and sex. The failure rates were identical (22.2%) between men and women over 50 years of age, compared to rates of 18.8% and 11.1% respectively in women and men under 50 years of age. According to these data, on the one hand, the implant failure rate is not correlated with age or sex, and on the other hand, the risk of osteoporosis is not necessarily a risk of osteointegration.

The success of osseointegration depends partly on the condition of the recipient site [30], particularly its quality and its healing capacity. For osteoporosis to be considered a contraindication for implant therapy, it must:

- Affect the mandible and maxilla in the same way as other parts of the skeleton that allow for the diagnosis of the disease.
- Be associated with a reduced bone healing capacity around implants due to altered metabolism [30].
- A bone quality where the cancellous component clearly predominates can have consequences on the primary stability of the implant [26].

The condition of a bone to be implanted cannot be extrapolated by assessing a bone at a distance, and the risk of failure is assessed rather by radiography or bone density assessment during drilling. It would therefore be inappropriate to conclude that the maxillary and/or mandibular bone is osteoporotic in patients with vertebral or other osteoporotic fractures. The success of osseointegration depends in part on the condition of the implant bed. Osteoporosis has been emphasized, a condition considered to be associated with a decline in bone quality and quantity [30].

The hypothesis that osteoporosis represents a risk factor for osseointegration stems from the idea that the disease, associated with a defect in bone reformation, compromises the quality of bone healing and apposition at the implant interface [1].

Another hypothesis concerns changes in bone quality (architecture, mineral crystal size), which can reduce strength despite adequate mineral content, thus predisposing the bone to fracture or degradation of the implant bed [1].

We then deduce that three problems are encountered in an osteoporotic patient: low bone quantity and quality, in addition to impaired healing, which compromises the stability of dental implants in these patients. Osteoporosis therefore constitutes an absolute contraindication for dental implants.

8. Conclusions

Osteoporosis is a major public health problem in several countries (the United States, Germany, Japan, etc.). In this work, we have attempted to demonstrate the different aspects of the disease.

In the first chapter, we focused on diagnosis, the different etiological forms, risk factors, and preventive and curative treatment of the disease.

Prevention is achieved through bone densitometry examinations, allowing for early detection of the disease and the implementation of appropriate behavior.

Hormone replacement therapy and bisphosphonates are the main drug treatments prescribed for these patients. This work is based on a series of studies that deal with the management of osteoporotic subjects in dentistry. A number of consequences must be considered: these elderly and fragile patients must be treated with even more gentleness and delicacy, both morally and physically, particularly during avulsion maneuvers.

Conflicts of Interest

The authors declare no conflicts of interest.

References

[1] (1991) Consensus Development Conference: Prophylaxis and Treatment of Osteoporosis. *The American Journal of Medicine*, **90**, 107-110. https://doi.org/10.1016/0002-9343(91)90512-v

[2] NIH Consensus Development Panel on Osteoporosis Prevention, Diagnosis, and Ther-

apy (2001) Osteoporosis Prevention, Diagnosis, and Therapy. *The Journal of the American Medical Association*, **285**, 785-795. https://doi.org/10.1001/jama.285.6.785

[3] Sanfilippo, F. and Bianchi, A.E. (2003) Ostéoporsis the Effect on Maxillary Bone résorption and Therapeutic Possibilities by Means of Implant prothèse—A Literature Review and Clinical Considerations. *International Journal of Periodontics & Restorative Dentistry*, **23**, 447-457.

[4] International Osteoporosis Foundation (2010) Osteoporosis Facts and Statistics.

[5] Farman, A.G. (2005) Oral Implication of Osteoporosis. *Oral Surgery, Oral Medicine, Oral Pathology, Oral Radiology, and Endodontology*, **100**, 395-397. https://doi.org/10.1016/j.tripleo.2005.05.055

[6] Cauley, J., Suziki, B. and Weyant, R. (2005) Longitudinal Study of Periodontal Disease and Edentulism with Rates of Bone Loss in Older Women. *Journal of Periodontal Research*, **76**, 11-15.

[7] Djouajdi-Arama, F. and Barthet, P. (2004) Ménaupose et parodontites: La déficience en œstrogène peut elle affecter la sévérité d'une maladie parodontale? *Journal de Parodontologie & d'Implantologie Orale*, **21**, Article 3.

[8] El-Desouki, M.I. and Sulimani, R.A. (2007) High Prevalence of Osteoporosis in Saudi Men. *Saudi Medical Journal*, **28**, 774-777.

[9] Ronderos, M., Jacobs, D.R., Himes, J.H. and Pihlstrom, B.L. (2000) Associations of Periodontal Disease with Femoral Bone Mineral Density and Estrogen Replacement Therapy: Cross-Sectional Evaluation of US Adults from NHANES III. *Journal of Clinical Periodontology*, **27**, 778-786. https://doi.org/10.1034/j.1600-051x.2000.027010778.x

[10] Francis, R.M., Peacock, M., Marshall, D.H., Horsman, A. and Aaron, J.E. (1989) Spinal Osteoporosis in Men. *Bone and Mineral*, **5**, 347-357. https://doi.org/10.1016/0169-6009(89)90012-3

[11] Garcia, C. (1995) Bulletin du syndicat national des Chirurgiens-Dentistes homéopathes. *La Ménopausée au Cabinet Dentaire*, **4**, 4-28.

[12] Gorthi, C., Koduganti, R., Reddy, P. and Sandeep, N. (2009) Osteoporosis: A Risk Factor for Periodontitis. *Journal of Indian Society of Periodontology*, **13**, 90-96. https://doi.org/10.4103/0972-124x.55841

[13] Pagni, G., Pellegrini, G., Giannobile, W.V. and Rasperini, G. (2012) Postextraction Alveolar Ridge Preservation: Biological Basis and Treatments. *International Journal of Dentistry*, **2012**, 1-13. https://doi.org/10.1155/2012/151030

[14] National Osteoporosis Foundation (2010) Clinician's Guide to Prevention and Treatment of Osteoporosis. National Osteoporosis Foundation.

[15] Desmeules, J. (2005) Ostéonécrose des maxillaires. *Pharma-Flash*, **32**, 45-46.

[16] Benediktsdóttir, I.S., Wenzel, A., Petersen, J.K. and Hintze, H. (2004) Mandibular Third Molar Removal: Risk Indicators for Extended Operation Time, Postoperative Pain, and Complications. *Oral Surgery, Oral Medicine, Oral Pathology, Oral Radiology, and Endodontology*, **97**, 438-446. https://doi.org/10.1016/j.tripleo.2003.10.018

[17] Kozlowski, A. (2002) Tomographic Evaluation of Mastication in Women with Osteoporosis. *Annales Academiae Medicae Stetinensis*, **48**, 243-254.

[18] Gomes-Filho, I.S., Passos, J.D.S., Cruz, S.S., Vianna, M.I.P., Cerqueira, E.D.M.M., Oliveira, D.C., *et al.* (2007) The Association between Postmenopausal Osteoporosis and Periodontal Disease. *Journal of Periodontology*, **78**, 1731-1740. https://doi.org/10.1902/jop.2007.070057

[19] Esfahanian, V. and Shamami, M.S. (2012) Relationship between Osteoporosis and

Periodontal Disease: Review of the Literature. *Journal of Dental Medicine*, **9**, 256-264.

[20] Yang, M., Xu, R. and Zhou, B. (2000) Relation entre Ostéoporose et mouvement orthodontique. *West China Journal of Stomatology*, **18**, 314-316.

[21] Yarovola, J.B. and Spyroparlos, M.N. (2001) Effect of Drug in Orthodontic Movement. *Quintessence International*, **32**, 365-371.

[22] Kalia, S., Melsen, B. and Verna, C. (2004) Tissue Reaction to Orthodontic Tooth Movement in Acute and Chronic Corticosteroid Treatment. *Orthodontics & Craniofacial Research*, **7**, 26-34. https://doi.org/10.1111/j.1601-6343.2004.00278.x

[23] Montoya-Carralero, J., Parra-Mino, P., Ramirez-Fernandez, P., Morata-Murcia, I., Mompean-Gambin, M. and Calvo-Guirado, J. (2010) Dental Implants in Patients Treated with Oral Bisphosphonates: A Bibliographic Review. *Medicina Oral Patología Oral y Cirugia Bucal*, **15**, e65-e69. https://doi.org/10.4317/medoral.15.e65

[24] Yoshihara, A., Seida, Y., Hanada, N., Nakashima, K. and Miyazaki, H. (2005) The Relationship between Bone Mineral Density and the Number of Remaining Teeth in Community-Dwelling Older Adults. *Journal of Oral Rehabilitation*, **32**, 735-740. https://doi.org/10.1111/j.1365-2842.2005.01491.x

[25] Quayle, A. (2002) Aging, Osteoporosis and Dental Implants. *British Journal of Oral and Maxillofacial Surgery*, **40**, 459. https://doi.org/10.1016/s0266-4356(02)00216-4

[26] Aceard, G. and Alledtti, A.C. (2000) Renseignement posologique (Miacalcin NS) Calcitonine de saumon Synthétique.

[27] Zambonin, G., Colucci, S., Cantatore, F. and Grano, M. (1998) Response of Human Osteoblasts to Polymethylmetacrylate *in Vitro*. *Calcified Tissue International*, **62**, 362-365. https://doi.org/10.1007/s002239900445

[28] Hellstein, J.W., Adler, R.A., Edwards, B., Jacobsen, P.L., Kalmar, J.R., Koka, S., *et al.* (2011) Managing the Care of Patients Receiving Antiresorptive Therapy for Prevention and Treatment of Osteoporosis. *The Journal of the American Dental Association*, **142**, 1243-1251. https://doi.org/10.14219/jada.archive.2011.0108

[29] Kloss, F.R. and Gassner, R. (2006) Bone and Aging: Effects on the Maxillofacial Skeleton. *Experimental Gerontology*, **41**, 123-129. https://doi.org/10.1016/j.exger.2005.11.005

[30] Jeffcoat, M. (2005) The Association between Osteoporosis and Oral Bone Loss. *Journal of Periodontology*, **76**, 2125-2132. https://doi.org/10.1902/jop.2005.76.11-s.2125