



# Dry Needling in the Treatment of Chronic Cerebrospinal Venous Insufficiency (CCSVI) Associated with Cervical Muscular Dysfunctions: A Case Report

Luca Gentili<sup>1\*</sup>, Alessio Pederzoli<sup>2</sup>, Giorgio Colagrossi<sup>2</sup>, Riccardo Rosa<sup>3</sup>, Giovanna Borriello<sup>4,5</sup>

<sup>1</sup>Department of Anesthesia and Intensive Care Unit, S. Maria Goretti Hospital, Latina, Italy

<sup>2</sup>CPC Centro Polispecialistico Cancelliera, Albano Laziale, Italy

<sup>3</sup>Department of Medicine and Health Science “Vincenzo Tiberio”, University of Molise, Campobasso, Italy

<sup>4</sup>MS Center, San Pietro Fatebenefratelli Hospital, Rome, Italy

<sup>5</sup>Department of Public Health, University of Naples “Federico II”, Naples, Italy

Email: \*luca.gentili89@gmail.com

**How to cite this paper:** Gentili, L., Pederzoli, A., Colagrossi, G., Rosa, R. and Borriello, G. (2025) Dry Needling in the Treatment of Chronic Cerebrospinal Venous Insufficiency (CCSVI) Associated with Cervical Muscular Dysfunctions: A Case Report. *Open Access Library Journal*, 12: e13431.

<https://doi.org/10.4236/oalib.1113431>

**Received:** April 14, 2025

**Accepted:** May 26, 2025

**Published:** May 29, 2025

Copyright © 2025 by author(s) and Open Access Library Inc.

This work is licensed under the Creative Commons Attribution International

License (CC BY 4.0).

<http://creativecommons.org/licenses/by/4.0/>



Open Access

## Abstract

**Background:** Chronic cerebrospinal venous insufficiency (CCSVI) involves impaired venous drainage of the central nervous system. Myofascial trigger points (TrPs) in neck muscles may contribute to venous obstruction through direct compression and altered biomechanics. Dry Needling (DN) effectively deactivates TrPs and reduces muscle hypertonicity, potentially improving venous outflow. **Case:** A 40-year-old man with relapsing-remitting multiple sclerosis presented with worsening neurological symptoms following cervical trauma from a surfing accident. Physical examination revealed marked cervical anteriorization, tense and painful sternocleidomastoid muscles bilaterally with palpable trigger points, and limited cervical mobility. Echo-color Doppler confirmed CCSVI with right jugular “bottleneck”. The patient underwent 8 weekly DN sessions targeting TrPs in cervical muscles. Follow-up assessments showed progressive normalization of venous flow, reduced headache frequency, improved fatigue scores (FSS-9 from 5.6 to 3.1), enhanced sleep quality, reduced pain (VAS from 7 to 2), and improved cervical mobility (+35%). **Conclusion:** This case demonstrates that DN can improve clinical symptoms and venous outflow in selected CCSVI patients with cervical muscular dysfunction. DN appears to address CCSVI’s muscular component through reduced mechanical compression and enhanced local circulation, warranting further investigation through controlled trials.

---

## Subject Areas

Physical Medicine and Rehabilitation, Neurology, Vascular Medicine, Complementary and Alternative Medicine, Pain Management

## Keywords

Dry Needling, Cerebrospinal Venous Insufficiency, Multiple Sclerosis, Cervical Muscular Dysfunction, Myofascial Trigger Points

---

## 1. Introduction

Chronic cerebrospinal venous insufficiency (CCSVI) is characterized by impaired venous drainage of the central nervous system. While its correlation with multiple sclerosis (MS) has been debated [1], the impact of altered cerebral venous outflow on neurological symptoms remains an area of clinical interest [2]. Current evidence suggests that CCSVI is a vascular condition associated with various neurological disorders, but the scientific community has moved away from invasive treatments such as angioplasty due to their statistically limited impact on symptom severity and absence of effect on disease progression. This evolving understanding has prompted exploration of less invasive approaches that may address contributing factors to venous insufficiency. CCSVI etiology is multifactorial, including congenital venous anomalies, structural venous wall alterations, anatomical variants [3], and extrinsic mechanical compression by muscles [4] [5]. The close relationship between neck muscles (SCM and scalenes) and the jugular venous system [4] suggests that muscle tone alterations, like myofascial trigger points (TrPs), can influence venous drainage [6] [7]. TrPs, hyperirritable nodules in taut muscle bands, generate referred pain, motor dysfunction, and autonomic phenomena [4] [8], influencing venous flow through direct compression [4] [5], altered proprioception/motor control (abnormal postures) [6], and vasoactive mediator release [8]. Dry Needling (DN) inactivates TrPs [9] [10], reducing pain and hypertonicity, and restoring function [11]. In CCSVI, cervical TrP deactivation (SCM, scalenes, upper trapezius) could reduce jugular compression, improving outflow [4] [5]. DN reduces tone [10] [11], improves circulation [11], modulates neurovegetative response [12], and normalizes function [9] [10]. Cervical trauma (whiplash) can alter biomechanics [13], inducing abnormal postures, TrP formation [4] [8], hypertonicity, and vascular compression [4] [5] [13].

## 2. Case Presentation

A 40-year-old man with mild Relapsing-Remitting Multiple Sclerosis (RRMS) since 2012, with an Expanded Disability Status Scale (EDSS) score of 1.0, never treated with disease modifying treatments due to a benign evolution, presented with worsening neurological symptoms (fatigue, headache, paresthesias, muscle

heaviness) after cervical trauma occurred when surfing. Initial symptoms included debilitating fatigue (Fatigue Severity Scale [FSS-9] score of 5.6) frequent tension-type headaches (2 - 3 episodes per week lasting 4 - 6 hours), non-dermatomal paresthesias of the upper limbs, and subjective muscle heaviness affecting daily activities. Sleep quality was poor (Pittsburgh Sleep Quality Index [PSQI] score of 9), and the patient reported moderate-to-severe neck pain (Visual Analog Scale [VAS] score of 7). Symptoms worsened, leading to MS diagnosis. Past medical history reported gynecomastia, tonsillectomy, appendectomy, and varicocele. At physical examination, the patient demonstrated significant cervical anteriorization (forward head posture with a craniovertebral angle of approximately 42° compared to the normal range of 50° - 60°), bilaterally tense and painful sternocleidomastoid muscles with multiple palpable TrPs, and significant cervical mobility limitations (reduced range of motion by approximately 40% in flexion-extension and rotation) with end-range pain. Pressure pain threshold (PPT) testing of the SCM muscles revealed values decreased by approximately 45% compared to normative data. The patient, having benefited from DN for other muscular issues, and suspecting a muscular component in his CCSVI, requested DN.

### 2.1. Instrumental Examinations

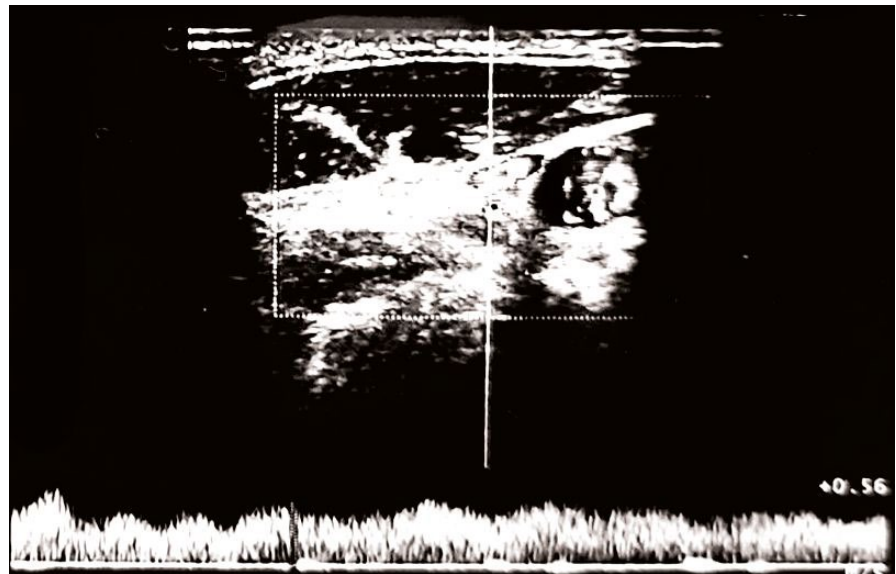
Echo-color Doppler: regular supra-aortic vessels, IMT 0.7 mm, no carotid lesions. Altered jugular system: right jugular “bottleneck” (middle third), reduced, poorly phasic flow; left jugular compressible (**Figure 1(A)**). Patent vertebral axes. Findings compatible with CCSVI.

### 2.2. Treatment

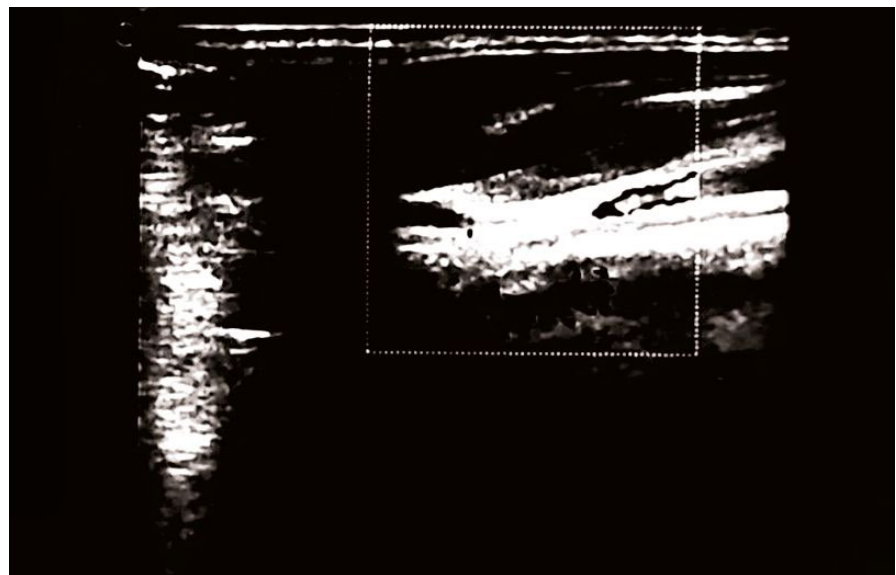
8 weekly DN sessions and bimonthly maintenance. Technique: supine/seated, chlorhexidine. Deep palpation identified TrPs (SCM, scalenes, upper trapezius). Sterile needles (0.30 × 30 mm), 7 - 10 needles inserted. DN: “pistoning” (1 - 2 Hz) until Local Twitch Response (LTR), then 10 - 15 min retention. Home exercises: alternate days (stretching, strengthening, proprioception, breathing).

### 2.3. Results

Follow-up Doppler showed progressive improvement. Initial findings are presented in **Figure 1**: right jugular “bottleneck,” reduced flow; compressible left jugular. By week four, improvement was noted in both, and after eight weeks of treatment (**Figure 1(B)**) and two additional maintenance sessions, the 16 week-follow-up (**Figure 2(A)**) venous normalization. By 24 weeks (**Figure 2(B)**): maintained normalization, stable IMT. Clinically: headache resolved (2 - 3/week to 0); FSS-9 5.6 to 3.1; PSQI 9 to 5; VAS 7 to 2; SCM PPT +45%; cervical mobility +35%. Minor side effects were reported, as mild pain (2/8 initial sessions), resolving haematomas. Maintained improvements at follow-ups, with limited exercise adherence, suggest DN’s primary benefit.

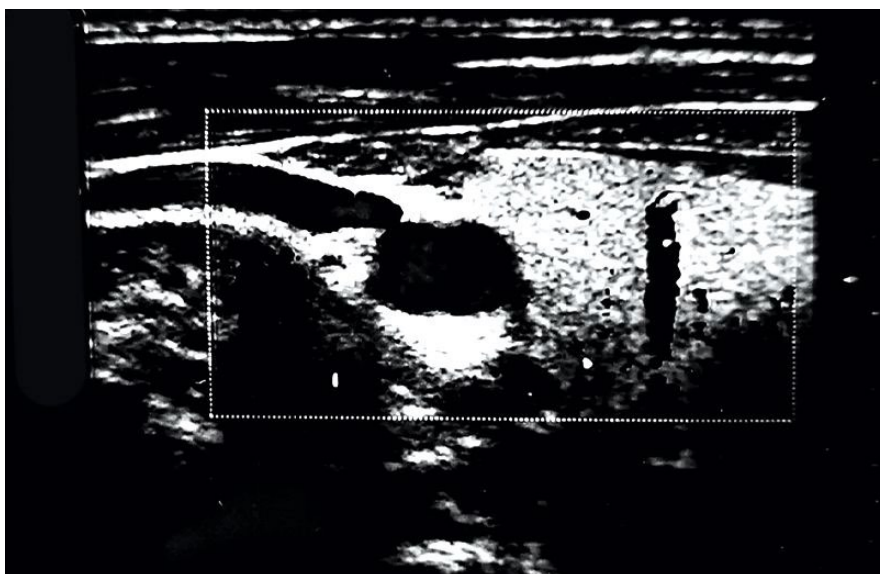


(A)

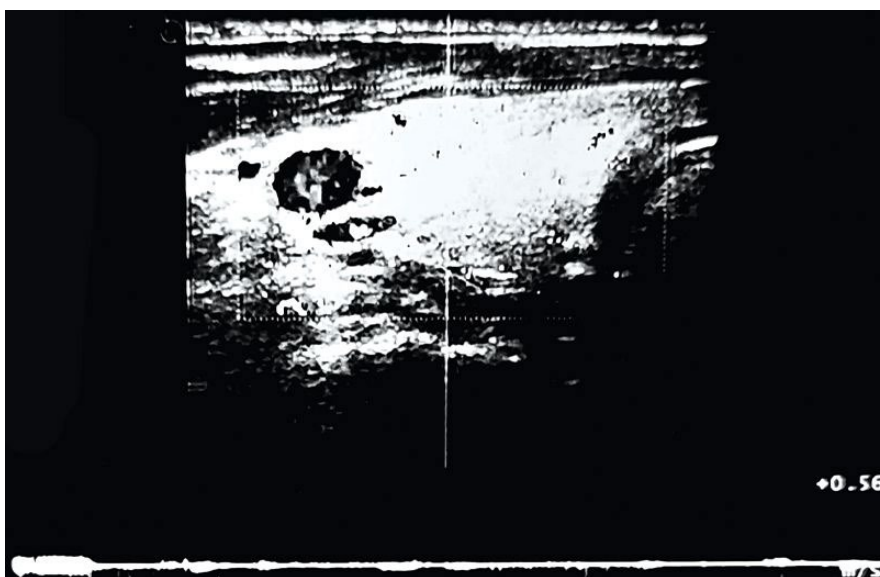


(B)

**Figure 1.** (A): At Time 0 (baseline examination, prior to the initiation of Dry Needling treatment), the carotid arteries presented with regular vascular walls, an IMT of 0.7 mm, and no significant atherosclerotic plaques. However, the jugular venous system showed signs of altered drainage. The right jugular vein exhibited an evident “bottle-neck”, or functional stenosis, in the middle third, accompanied by reduced and poorly phasic flow. The left jugular vein presented with a compressible lumen and hypodynamic flow. These findings were deemed compatible with a diagnosis of CCSVI. (B): After 8 weeks of Dry Needling treatment, a follow-up examination was conducted. The carotid arteries remained unchanged, with a stable IMT and no significant alterations. In the jugular system, the right jugular vein showed a less pronounced functional stenosis compared to Time 0, with evidence of partial flow recovery. The left jugular vein demonstrated improved compressibility and a more regular flow pattern. These findings indicated signs of improved venous drainage, specifically a reduction in the right jugular obstruction.



(A)



(B)

**Figure 2.** (A): After 16 weeks (including 8 weeks of initial treatment and two maintenance Dry Needling sessions), a follow-up examination revealed no significant variation in the carotid arteries compared to previous examinations. The jugular system, however, showed further improvement. The right jugular vein presented with a normal caliber, no signs of a bottleneck, and restored, phasic flow. The left jugular vein maintained good compressibility and adequate flow. These findings confirmed a normalization of extracranial venous circulation, which was sustained even after the conclusion of the intensive treatment phase. (B): After 24 weeks (including initial, and 4 maintenance sessions), the final examination showed an unchanged profile in the carotid arteries. The right jugular vein exhibited normal and phasic flow, with no evidence of residual obstruction. This confirmed that the clinical and hemodynamic improvements were maintained at this timepoint, with no signs of CCSVI recurrence.

### 3. Discussion

The observed clinical and ultrasound improvements strongly support the hypoth-

esis that Dry Needling (DN) can play a significant role in improving cerebral venous drainage in carefully selected patients with CCSVI, particularly when a post-traumatic muscular component is present. The close anatomical relationship between the sternocleidomastoid (SCM) and scalene muscles and the jugular veins makes these muscles prime candidates for contributing to extrinsic venous compression when affected by contractures or active TrPs [4] [5]. The whiplash injury sustained by the patient likely initiated a cascade of events, including muscle dysfunction, TrP formation, increased muscle tone, and ultimately, compromised venous outflow. DN likely exerts its beneficial effects through several interconnected mechanisms. Firstly, the deactivation of TrPs, achieved through the precise insertion and manipulation of needles, directly reduces the mechanical compression exerted on the jugular veins [4] [5]. Secondly, DN has demonstrated neurophysiological effects, including the modulation of muscle tone, an increase in the pressure pain threshold (PPT), and a potential influence on the autonomic nervous system [12] [14]. These effects can contribute to a reduction in overall muscle tension and improved local tissue homeostasis. Thirdly, the mechanical stimulation of the needle within the TrP may promote the local release of vasoactive substances, such as bradykinin and substance P, which can enhance microcirculation and contribute to the resolution of inflammation within the affected tissues [8]. This multifactorial action of DN addresses both the mechanical and biochemical aspects of the muscular dysfunction contributing to CCSVI [15].

While venous angioplasty (PTA) remains a conventional treatment for CCSVI, DN offers distinct advantages: it is minimally invasive, carries a low risk of complications, is generally well-tolerated by patients, and is relatively cost-effective. It is crucial to acknowledge, however, that the effectiveness of DN may be limited or even contraindicated in cases where congenital venous anomalies [3] or the sequelae of previous surgical interventions are the primary drivers of venous outflow obstruction. A thorough pre-treatment evaluation, including a detailed medical history and echo-color Doppler examination, is therefore essential to identify appropriate candidates for DN therapy.

#### **4. Conclusion**

This case report provides preliminary evidence to suggest that Dry Needling (DN) might be an effective treatment for improving both clinical symptoms and echo-color Doppler findings in carefully selected patients with CCSVI and a demonstrable post-traumatic cervical muscular dysfunction. The observed benefits, including improved venous outflow, reduced headache frequency, decreased fatigue, improved sleep quality, and increased cervical mobility, highlight the potential of DN to address the muscular component contributing to CCSVI. The absence of significant adverse effects further supports its safety profile. It is important to emphasize that this is an exploratory study based on a single case, and as such, cannot establish definitive efficacy or safety of DN for treating CCSVI in the broader population. Robust evidence from well-designed randomized controlled trials is absolutely nec-

essary. These trials should aim to confirm these preliminary findings, establish standardized treatment protocols, elucidate the precise mechanisms of action of DN in the context of CCSVI, and determine the long-term efficacy and safety profile of this promising therapeutic approach, and identify specific patient subgroups most likely to benefit from such interventions. It is also essential to continue exploring the complex interplay between muscular dysfunction and other potential etiological factors in CCSVI to develop comprehensive and individualized treatment strategies while maintaining a focus on evidence-based, minimally invasive interventions that prioritize patient safety and quality of life.

## Conflicts of Interest

The authors declare no conflicts of interest.

## References

- [1] Zamboni, P., Galeotti, R., Menegatti, E., Malagoni, A.M., Tacconi, G., Dall'Ara, S., *et al.* (2008) Chronic Cerebrospinal Venous Insufficiency in Patients with Multiple Sclerosis. *Journal of Neurology, Neurosurgery & Psychiatry*, **80**, 392-399. <https://doi.org/10.1136/jnnp.2008.157164>
- [2] Leone, M.A., *et al.* (2023) Current Understanding of Chronic Cerebrospinal Venous Insufficiency: A Systematic Review. *Vascular Pharmacology*, **151**, Article 107177.
- [3] Simka, M., Latacz, P., Ludyga, T., Kazibudzki, M., Swierad, M., Janas, P. and Piegza, J. (2011) Prevalence of Extracranial Venous Abnormalities: Results from a Sample of 586 Multiple Sclerosis Patients. *Functional Neurologic*, **26**, 197-203.
- [4] Grieve, R., Cranston, A., Henderson, A., John, R., Malone, G. and Mayall, C. (2013) The Immediate Effect of Triceps Surae Myofascial Trigger Point Therapy on Restricted Active Ankle Joint Dorsiflexion in Recreational Runners: A Crossover Randomised Controlled Trial. *Journal of Bodywork and Movement Therapies*, **17**, 453-461. <https://doi.org/10.1016/j.jbmt.2013.02.001>
- [5] Shah, J.P., Thaker, N., Heimur, J., Aredo, J.V., Sikdar, S. and Gerber, L. (2015) Myofascial Trigger Points Then and Now: A Historical and Scientific Perspective. *PM&R*, **7**, 746-761. <https://doi.org/10.1016/j.pmrj.2015.01.024>
- [6] Zito, G., Jull, G. and Story, I. (2006) Clinical Tests of Musculoskeletal Dysfunction in the Diagnosis of Cervicogenic Headache. *Manual Therapy*, **11**, 118-129. <https://doi.org/10.1016/j.math.2005.04.007>
- [7] Doepp, F., *et al.* (2013) Venous Drainage in Multiple Sclerosis and Healthy Controls. *Neurology*, **80**, 1774-1781.
- [8] Shah, J.P., Danoff, J.V., Desai, M.J., Parikh, S., Nakamura, L.Y., Phillips, T.M., *et al.* (2008) Biochemicals Associated with Pain and Inflammation Are Elevated in Sites near to and Remote from Active Myofascial Trigger Points. *Archives of Physical Medicine and Rehabilitation*, **89**, 16-23. <https://doi.org/10.1016/j.apmr.2007.10.018>
- [9] Fernández-de-las-Peñas, C. and Dommerholt, J. (2013) Myofascial Trigger Points: Peripheral or Central Phenomenon? *Current Rheumatology Reports*, **16**, Article No. 395. <https://doi.org/10.1007/s11926-013-0395-2>
- [10] Cagnie, B., Dewitte, V., Barbe, T., Timmermans, F., Delrue, N. and Meeus, M. (2013) Physiologic Effects of Dry Needling. *Current Pain and Headache Reports*, **17**, Article No. 348. <https://doi.org/10.1007/s11916-013-0348-5>

- [11] De Meulemeester, K.E., Castelein, B., Coppieters, I., Barbe, T., Cools, A. and Cagnie, B. (2017) Comparing Trigger Point Dry Needling and Manual Pressure Technique for the Management of Myofascial Neck/shoulder Pain: A Randomized Clinical Trial. *Journal of Manipulative and Physiological Therapeutics*, **40**, 11-20.  
<https://doi.org/10.1016/j.jmpt.2016.10.008>
- [12] Dunning, J., Butts, R., Mourad, F., Young, I., Flannagan, S. and Perreault, T. (2014) Dry Needling: A Literature Review with Implications for Clinical Practice Guidelines. *Physical Therapy Reviews*, **19**, 252-265.  
<https://doi.org/10.1179/108331913x13844245102034>
- [13] Sterling, M. (2011) Whiplash-Associated Disorder: A Review of the Past, Examination of the Present, and an Outline to the Future. *Manual Therapy*, **16**, 309-315.
- [14] Izraelski, J. (2012) Assessment and Treatment of Muscle Imbalance: The Janda Approach. *Journal of the Canadian Chiropractic Association*, **56**, 156-159.
- [15] Smith, K., *et al.* (2023) The Evolution of the CCSVI Concept in Neurological Disorders: A Critical Review. *Journal of the Neurological Sciences*, **451**, Article 120741.