

Unveiling of Tuberculosis from Colonoscopy

Bipneet Singh, Sakshi Bai, Palak Grover, Jahnvi Ethakota, Iman El Feki, Sruthi Ramanan

Internal Medicine, Henry Ford Allegiance Health, Jackson, Michigan, USA

Email: drbipneetsingh18@gmail.com

How to cite this paper: Singh, B., Bai, S., Grover, P., Ethakota, J., El Feki, I. and Ramanan, S. (2025) Unveiling of Tuberculosis from Colonoscopy. *Journal of Tuberculosis Research*, 13, 55-60.

<https://doi.org/10.4236/jtr.2025.132005>

Received: April 1, 2025

Accepted: June 21, 2025

Published: June 24, 2025

Copyright © 2025 by author(s) and Scientific Research Publishing Inc. This work is licensed under the Creative Commons Attribution International License (CC BY 4.0).

<http://creativecommons.org/licenses/by/4.0/>



Open Access

Abstract

Background: Tuberculosis (TB) colitis, an extrapulmonary manifestation of TB, presents a diagnostic challenge in the absence of pulmonary disease. This case study illuminates TB colitis, emphasizing its clinical characteristics, diagnostic methodologies, and management strategies. **Aim:** TB mimics other GI conditions including Crohn's. It is important to consider it as a differential especially in people coming from prone areas. Colonoscopy with deep biopsy proves valuable in obtaining tissue diagnosis, revealing characteristic ulcerative and hypertrophic lesions. **Case Presentation:** We report the case of a 36-year-old immigrant from India, initially presenting with rectal bleeding, subsequently agreeing to night sweats and substantial weight loss. A colonoscopy revealed Acid-fast bacilli (AFB)-positive granulomatous colitis, leading to microbiological confirmation. **Conclusion:** This case underscores the need for timely recognition and management to prevent morbidity associated with TB colitis, especially in cases with atypical presentations. Increased awareness among clinicians is crucial for improving diagnostic accuracy and ensuring prompt initiation of appropriate therapeutic measures.

Keywords

Rifampin Isoniazid, Mdr TB, Hematochezia, Tuberculosis Colitis, Tuberculosis

1. Introduction

Tuberculosis (TB) colitis, an extrapulmonary manifestation of tuberculosis, presents a diagnostic challenge due to its non-specific gastrointestinal clinical features. With rates differing by region, this TB manifestation makes up 1% to 3% of all TB cases globally and 6% to 13% of extrapulmonary TB cases [1] [2].

The ileum and ileocecal valve are commonly involved due to a narrow lumen, relatively increased stasis, low enzyme activity, and high lymph drainage through

which *Mycobacterium* can enter the portal circulation and infect the liver, spleen, and pancreas. Direct extension of infection to the peritoneum can result, as well as infected adnexa and paraspinous muscle [3]-[5].

This case study sheds light on TB colitis, emphasizing its clinical characteristics, diagnostic methodologies, and management strategies. We report the case of a 36-year-old immigrant from India, initially presenting with rectal bleeding, subsequently agreeing to night sweats and substantial weight loss. A colonoscopy revealed Acid-fast bacilli (AFB)-positive granulomatous colitis, leading to a multi-disciplinary diagnostic approach involving imaging studies and microbiological confirmation.

This case further highlights the importance of considering TB in the differential diagnosis of gastrointestinal symptoms, especially in individuals from high TB-burden regions. The discussion underscores that TB can affect the digestive tract, often mimicking other conditions like Crohn's disease. Colonoscopy with deep biopsy proves valuable in obtaining tissue diagnosis, revealing characteristic ulcerative and hypertrophic lesions.

The cornerstone of treatment involves anti-TB medication, with a follow-up colonoscopy demonstrating gut response within 3 - 4 weeks. Complications such as stricture formation may necessitate surgical intervention.

2. Case Presentation

A 36-year-old immigrant from India with no past medical history presented with rectal bleeding which was initially seen on the toilet paper and deemed to be hemorrhoidal but thereafter the patient developed frank hematochezia. On presentation, the patient had stable intake vitals. Blood work was performed showing a 3-point hemoglobin drop from 13 g/dL baseline to 10 g/dL. White cell and platelet counts were normal. Electrolytes and renal functions were at baseline as well. The patient was adequately resuscitated with intravenous fluids and one packed red cell transfusion and gastroenterology was brought on board.

Given hematochezia, a colonoscopy was planned revealing ulcers in the transverse and ascending colon in **Figure 1** and **Figure 2**. A biopsy was taken which demonstrated Acid Fast Bacilli-positive granulomatous colitis. **Figure 3** shows granuloma and **Figure 4** shows AFB.

Upon further questioning following colonoscopy, he stated that for the past 3 months, he had been experiencing exertional shortness of breath, night sweats and had endorsed 40 lb weight loss. X-ray imaging demonstrated left-sided pleural effusion. This was then followed by a CT chest re-demonstrating left-sided nodular opacities with pleural effusion as seen in **Figure 5**.

The patient did not have shortness of breath at rest but demonstrated exertional dyspnea. The patient further underwent diagnostic and therapeutic thoracentesis, with acid-fast stain and culture revealing tuberculosis. The patient's hospital course was complicated by status epilepticus prompting an MRI showing tuberculomas indicating CNS involvement (**Figure 6**). The patient was intubated during the seizure episode and further transferred to intensive care.

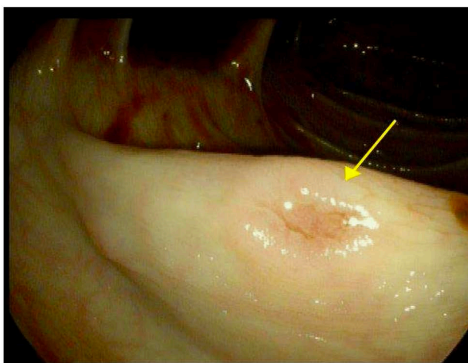


Figure 1. Ulcer in ascending colon.

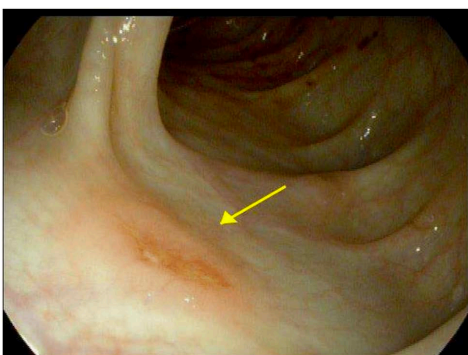


Figure 2. Ulcer in transverse colon.

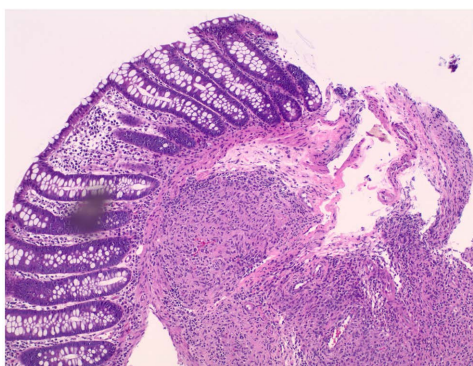


Figure 3. Granuloma in the colon.

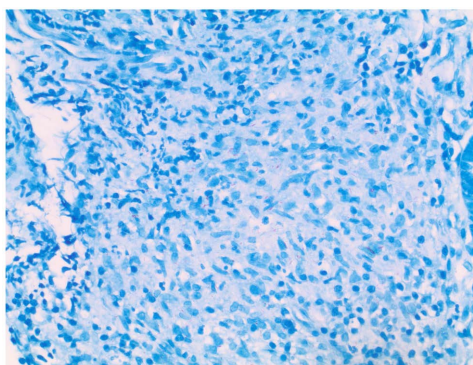


Figure 4. Red acid fast bacilli.

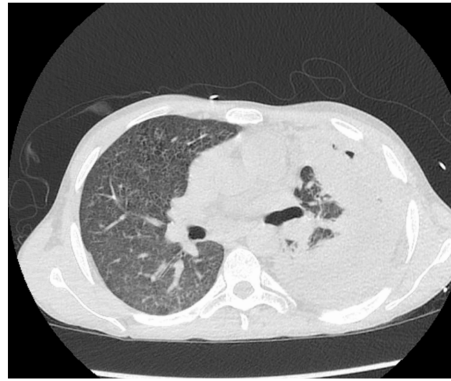


Figure 5. Left-sided pleural effusion with infiltrates.

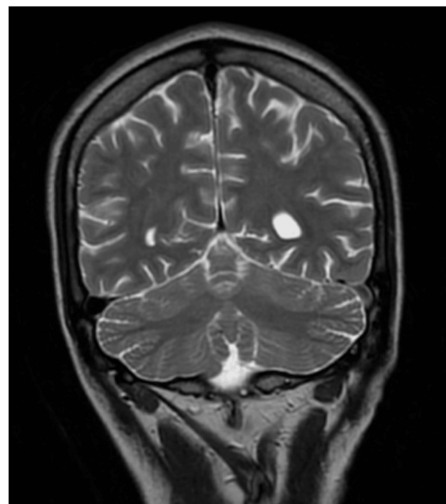


Figure 6. Tuberculoma on left side of the brain.

The patient was started on Rifampin, Isoniazid, Pyrazinamide, and Ethambutol. Sensitivities demonstrated Rifampin and Isoniazid resistance at which point the patient was put on amikacin/Zyvox/moxifloxacin/pyrazinamide.

3. Discussion

Diarrhea, constipation, blood in stools, or weight loss are examples of different presentations. However, immigrants from endemic areas should be viewed with great caution, particularly if they exhibit weight loss and nocturnal sweats.

Tuberculosis affects the digestive tract in 2% of cases [1]. Usually, the terminal ileum, the caecum, and the ascending colon are affected, mimicking Crohn's disease [2]. An ideal environment for infection is created in the ileocecal area by natural stasis and a high density of lymphoid tissue [3]-[5].

TB-related ulcers typically have a circular shape, encircled by inflammatory mucosa that has the propensity to stricture. Crohn's disease-related granulomas are usually mucosal, although TB granulomas are frequently submucosal. De Jesus *et al.* reported that stenosing left-sided TB colitis was present in 10-year-old children who were malnourished and experienced chronic abdominal pain leading to

a perforated lesion that had to be removed surgically [6]. A 37-year-old male described by Dalugama *et al.* displayed caseation and tuberculous granulomata in the appendix [7].

The following observations are more indicative of intestinal tuberculosis: nodular friable mucosa, inflammatory polyps, linear ulcers, severely distorted and edematous ileocecal valve, or distinctive granulomas [4] [5]. The classic sign of tuberculosis infection is caseating granulomas [8] [9] found in the submucosa [10].

A colonoscopy combined with a deep biopsy is helpful to gather material for histology and culture to obtain a tissue diagnosis. Intestinal lesions can take two forms: ulcerative and hypertrophic, which are frequent in the ileum/jejunum and colon, respectively, and can coexist.

AFB-positive histology increases the likelihood of a positive culture result, the gold standard but laborious procedure that takes several weeks but only works in half of the instances [11] [12]. Biopsy specimens can be used for more sensitive analysis using polymerase chain reaction, which can be beneficial [12].

Until susceptibility data are obtained, extrapulmonary TB should be treated with a 4-drug regimen like that of pulmonary TB [13]. As treatment for Crohn's uses biological therapies, it is imperative to establish an accurate diagnosis since latent tuberculosis reactivation is more likely when using infliximab.

Anti-TB medication is part of the treatment, and a gut response can be shown in 3 - 4 weeks during a follow-up colonoscopy. Stricture formation may occur during the healing process of ulcerative lesions, necessitating surgery.

4. Conclusions

Typically overshadowed by pulmonary tuberculosis, we present a comprehensive case outlining the clinical characteristics, diagnostic modalities, and management strategies for TB colitis.

Further, this case aims to urge clinicians to consider tuberculosis in the differential diagnosis of gastrointestinal symptoms, particularly in people from regions with a high TB burden.

The case also describes how widespread tuberculosis can be and the symptoms should prompt imaging to check tuberculosis in the concerned organ system.

Lastly, sensitivities need to be followed due to growing concern for drug resistance.

Conflicts of Interest

The authors had no conflicts of interest. Informed consent was obtained from the patient.

References

- [1] Haddad, A., Sebai, A., Chelly, B., Maghrebi, H., Chaker, Y., Jouini, M., *et al.* (2021) Tuberculous Severe Acute Colitis. A Case Report. *Annals of Medicine & Surgery*, **69**,

Article 102756. <https://doi.org/10.1016/j.amsu.2021.102756>

- [2] Kentley, J., Ooi, J.L., Potter, J., Tiberi, S., O'Shaughnessy, T., Langmead, L., et al. (2017) Intestinal Tuberculosis: A Diagnostic Challenge. *Tropical Medicine & International Health*, **22**, 994-999. <https://doi.org/10.1111/tmi.12908>
- [3] Marshall, J.B. (1993) Tuberculosis of the Gastrointestinal Tract and Peritoneum. *The American Journal of Gastroenterology*, **88**, 989-999.
- [4] Shah, S., Thomas, V., Mathan, M., Chacko, A., Chandy, G., Ramakrishna, B.S., et al. (1992) Colonoscopic Study of 50 Patients with Colonic Tuberculosis. *Gut*, **33**, 347-351. <https://doi.org/10.1136/gut.33.3.347>
- [5] McGee, G.S., Williams, L.F., Potts, J., et al. (1989) Gastrointestinal Tuberculosis: Resurgence of an Old Pathogen. *The American Surgeon*, **55**, 16-20.
- [6] Shi, X., Zhang, L., Zhang, Y., Liu, X. and Fei, G. (2016) Clinical and Laboratory Diagnosis of Intestinal Tuberculosis. *Chinese Medical Journal*, **129**, 1330-1333. <https://doi.org/10.4103/0366-6999.182840>
- [7] Abu-Zidan, F.M. and Sheek-Hussein, M. (2019) Diagnosis of Abdominal Tuberculosis: Lessons Learned over 30 Years: Pectoral Assay. *World Journal of Emergency Surgery*, **14**, Article No. 33. <https://doi.org/10.1186/s13017-019-0252-3>
- [8] Singh, V., Kumar, P., Kamal, J., et al. (1996) Clinicocolonoscopy Profile of Colonic Tuberculosis. *American Journal of Gastroenterology*, **91**, 565-568.
- [9] Sinan, T., Sheikh, M., Ramadan, S., Sahwney, S. and Behbehani, A. (2002) CT Features in Abdominal Tuberculosis: 20 Years Experience. *BMC Medical Imaging*, **2**, Article No. 3. <https://doi.org/10.1186/1471-2342-2-3>
- [10] Anand, B.S., Schneider, F.E., Elzaatari, F.A.K., et al. (1994) Diagnosis of Intestinal Tuberculosis by Polymerase Chain Reaction on Endoscopic Biopsy Specimens. *American Journal of Gastroenterology*, **89**, 2248-2249.
- [11] Gan, H. (2002) Differentiation between Intestinal Tuberculosis and Crohn's Disease in Endoscopic Biopsy Specimens by Polymerase Chain Reaction. *The American Journal of Gastroenterology*, **97**, 1446-1451. [https://doi.org/10.1016/s0002-9270\(02\)04042-x](https://doi.org/10.1016/s0002-9270(02)04042-x)
- [12] Saczek, K.B., Schaaf, H.S., Voss, M., Cotton, M.F. and Moore, S.W. (2001) Diagnostic Dilemmas in Abdominal Tuberculosis in Children. *Pediatric Surgery International*, **17**, 111-115. <https://doi.org/10.1007/s003830000455>
- [13] American Academy of Pediatrics (2003) Tuberculosis. In: Pickering, L.K., Ed., *Red Book: 2003 Report of the Committee on Infectious Diseases*, 26th Edition, American Academy of Pediatrics, 642-660.