

Herpes Zoster Ophthalmicus Diagnosed by an ENT Specialist during the COVID-19 Pandemic: A Case Report

Rinor Ajeti^{1*}, Afrim Ajeti¹, Vesna Petreska Dukovska²

¹Otorhinolaryngology Private Clinic, RINO Clinic, Ferizaj, Republic of Kosovo

²Remedica Hospital, Skopje, North Macedonia

Email: *rinorajeti@rino.clinic, dr.afrimajeti@gmail.com, vpetreska@remedika.com.mk

How to cite this paper: Ajeti, R., Ajeti, A. and Dukovska, V. P. (2025) Herpes Zoster Ophthalmicus Diagnosed by an ENT Specialist during the COVID-19 Pandemic: A Case Report. *International Journal of Otolaryngology and Head & Neck Surgery*, 14, 253-258.

<https://doi.org/10.4236/ijohns.2025.144027>

Received: March 18, 2025

Accepted: July 12, 2025

Published: July 15, 2025

Copyright © 2025 by author(s) and Scientific Research Publishing Inc.

This work is licensed under the Creative Commons Attribution International License (CC BY 4.0).

<http://creativecommons.org/licenses/by/4.0/>



Open Access

Abstract

Herpes Zoster Ophthalmicus (HZO), caused by varicella-zoster virus reactivation in the ophthalmic trigeminal nerve, presents with unilateral facial pain and vesicular rash. This report describes a 60-year-old woman who developed Herpes Zoster Ophthalmicus during the COVID-19 pandemic. She presented to an ENT clinic with right forehead pain and a vesicular rash sparing the nasal tip, without Hutchinson's sign or visual deficits. Diagnosed clinically, she received high-dose oral acyclovir and corticosteroids, leading to symptom resolution within four weeks. At five-year follow-up, no ocular complications or sequelae were observed. The case underscores the role of ENT specialists in managing Herpes Zoster Ophthalmicus during healthcare crises, emphasizing antiviral therapy initiated within 72 hours of symptom onset to prevent vision-threatening complications when specialist referrals are delayed.

Keywords

Herpes Zoster Ophthalmicus, Varicella-Zoster Virus, ENT Diagnosis, COVID-19, Antiviral Therapy

1. Introduction

Herpes Zoster Ophthalmicus (HZO) accounts for 4% - 20% of herpes zoster cases, primarily affecting older adults and immunocompromised individuals [1] [2]. Reactivation of varicella-zoster virus in the ophthalmic trigeminal nerve results in a painful unilateral rash along the V1 dermatome (forehead, eyelid, nasal bridge), with up to 50% risk of ocular complications such as keratitis or vision loss [3] [4]. Recent studies emphasize comprehensive protocols for early antiviral therapy and interdisciplinary care to mitigate acute symptoms and long-term complications [4].

Hutchinson's sign—vesicles at the nasal tip—predicts ocular involvement and warrants urgent ophthalmologic referral [5]. The COVID-19 pandemic disrupted healthcare access, highlighting the need for frontline providers to diagnose and manage Herpes Zoster Ophthalmicus in resource-limited settings. In such contexts, ENT specialists may be the first and only point of care, necessitating increased awareness of diagnostic signs, initial management protocols, and when to escalate care. Guidelines tailored for non-ophthalmic providers can improve outcomes during such disruptions. Timely diagnosis and empirical antiviral treatment in such environments can prevent complications when specialist access is delayed. These scenarios highlight the evolving role of frontline providers in recognizing red-flag signs and initiating protocol-driven management to bridge care gaps.

2. Case Presentation

A 60-year-old woman presented to our ENT clinic with acute right forehead pain and a vesicular rash. She had a history of childhood chickenpox but no herpes zoster vaccination. The patient denied smoking, alcohol use, or regular medication intake. Her medical history was unremarkable, with no evidence of autoimmune, hematologic, or chronic systemic disorders such as diabetes mellitus or malignancy. She had no history of immunosuppression and was not taking any immunosuppressive therapy. Family history was non-contributory. She reported no recent travel, trauma, or known exposure to COVID-19. However, she experienced transient fatigue and mild dyspnea approximately one month earlier, which resolved spontaneously and was presumed to be a mild COVID-19-like illness. On examination, grouped vesicles were noted on the right forehead, upper eyelid, and nasal bridge (midline spared; **Figure 1**), with mild eyelid swelling and conjunctival injection (**Figure 2**). No corneal haze, Hutchinson's sign, or visual deficits were observed. Nasal endoscopy revealed no sinus purulence.

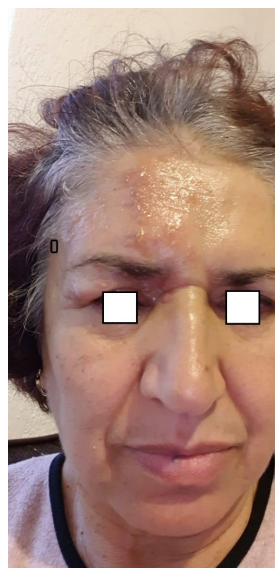

Figure 1. Initial presentation (April 14, 2020): Vesicular rash localized to the right forehead.

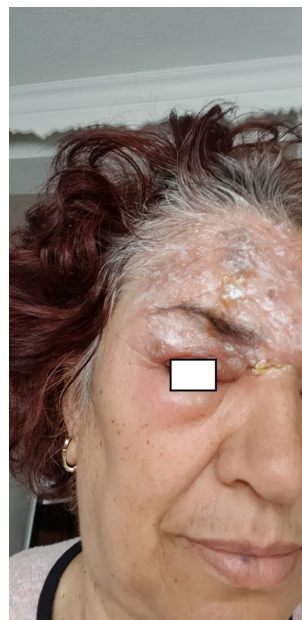

Figure 2. Early progression (April 16, 2020): Worsening periorbital swelling.

The diagnosis of Herpes Zoster Ophthalmicus was made clinically based on dermatomal rash distribution. Due to pandemic constraints, no laboratory or imaging studies were performed. Treatment included oral acyclovir (800 mg five times daily for 7 days), prednisolone (20 mg/day tapered over 8 days), analgesics, topical antibiotics, and esomeprazole for gastric protection.

By day 7, the rash began crusting (**Figure 3**). Complete resolution occurred within four weeks (**Figure 4**). At five-year follow-up, the patient had no residual scarring, neuralgia, or ocular complications (**Figure 5**).

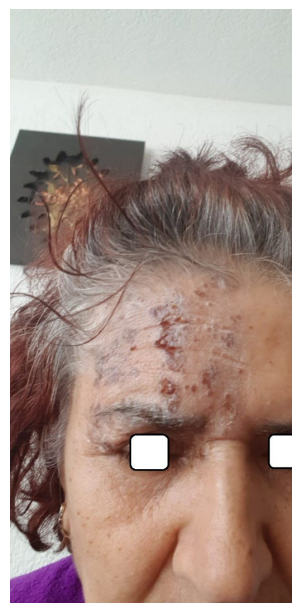

Figure 3. Clinical improvement (April 23, 2020): Day 9 follow-up showing crusting of vesicles and reduced periorbital edema.

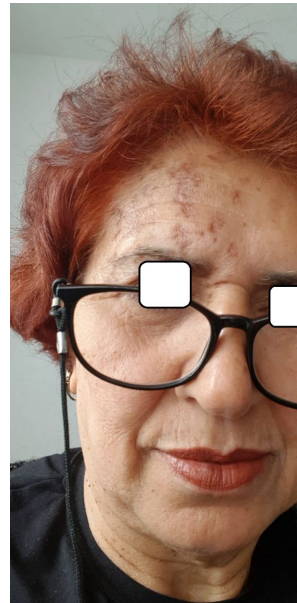

Figure 4. Subacute recovery (May 28, 2020): Resolution of active lesions.

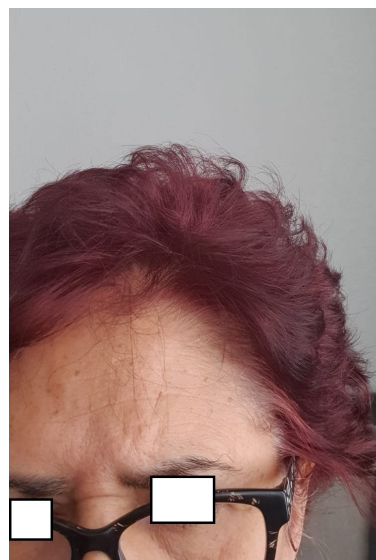


Figure 5. Five-year outcome (March 3, 2025): Complete resolution.

3. Discussion

This case illustrates three key points. First, early initiation of high-dose acyclovir within 72 hours of symptom onset is pivotal to reducing viral replication and preventing complications like postherpetic neuralgia or corneal scarring [6] [7]. Second, ENT specialists can effectively diagnose and manage Herpes Zoster Ophthalmicus in non-ophthalmologic settings, particularly when Hutchinson's sign is absent and visual symptoms are lacking. Third, the COVID-19 pandemic necessitated adaptable care models, including telemedicine and patient education on red flags (e.g., vision changes), to mitigate delays in resource-limited environments.

The decision not to refer was based on the absence of Hutchinson's sign, lack

of visual symptoms, and the constraints imposed by the pandemic, which limited access to ophthalmologic care. Recent studies emphasize structured protocols for early antiviral therapy, particularly critical during pandemic-related resource constraints [4]. While urgent ophthalmology referral is recommended in the presence of ocular findings or nasal tip involvement, this patient's presentation aligned with criteria allowing for ENT-led outpatient care. Close follow-up and patient education on vision red flags served as a safety net. This case highlights the necessity for adaptable healthcare strategies in pandemics. Although no confirmatory laboratory or imaging tests were performed, the classic dermatomal rash and history were strongly indicative of HZO. Given the pandemic context, minimizing patient movement and exposure risk justified empirical management. This approach aligns with pragmatic clinical protocols during crisis conditions. Empowering non-specialist providers through training and protocols for conditions like HZO can reduce morbidity when specialist access is delayed. Integration of telemedicine for remote follow-up and triage may also streamline care and minimize unnecessary referrals, especially in resource-constrained environments.

4. Limitations

The lack of laboratory confirmation (e.g., VZV PCR) and ophthalmologic assessment was a limitation. However, the classic dermatomal rash pattern, timing, and patient history supported a confident clinical diagnosis. During the pandemic, minimizing patient exposure and movement was prioritized, and empirical treatment was aligned with pragmatic management guidelines. This emphasizes the need for future protocols that enable point-of-care testing in such crises.

Author Contributions

Rinor Ajeti, MD: Conceptualization, study design, data collection, manuscript drafting, and final approval. **Afrim Ajeti, MD:** Interpretation of results, critical manuscript revision, and final approval. **Vesna Petreska Dukovska MD, PhD:** Review, Final approval.

Ethics

Written informed consent was obtained. IRB approval #120226 (RINO Clinic).

Data Availability

Data is freely available upon request.

Patient Consent

Written informed consent was obtained from the patient for publication of the clinical details and any accompanying images in this manuscript.

Conflicts of Interest

The authors declare no conflicts of interest regarding the publication of this paper.

References

- [1] Gnann, J.W. and Whitley, R.J. (2002) Herpes Zoster. *New England Journal of Medicine*, **347**, 340-346. <https://doi.org/10.1056/nejmcp013211>
- [2] Jung, I.G., Jung, H.J. and Shim, W.S. (2022) A Case with Herpes Zoster Ophthalmicus Mimicking Delayed Complication of Rhinoplasty. *Journal of Rhinology*, **29**, 118-121. <https://doi.org/10.18787/jr.2022.00404>
- [3] Minor, M. and Payne, E. (2023) Herpes Zoster Ophthalmicus. StatPearls.
- [4] Litt, J., Cunningham, A.L., Arnalich-Montiel, F. and Parikh, R. (2024) Herpes Zoster Ophthalmicus: Presentation, Complications, Treatment, and Prevention. *Infectious Diseases and Therapy*, **13**, 1439-1459. <https://doi.org/10.1007/s40121-024-00990-7>
- [5] Liesegang, T. (2008) Herpes Zoster Ophthalmicusnatural History, Risk Factors, Clinical Presentation, and Morbidity. *Ophthalmology*, **115**, S3-S12. <https://doi.org/10.1016/j.ophtha.2007.10.009>
- [6] Cohen, E.J. (2020) Herpes Zoster Ophthalmicus: What's New in Management? *Current Opinion in Ophthalmology*, **31**, 455-461.
- [7] Tsai, A. and Chodosh, J. (2019) Ocular Complications of Herpes Zoster. *Survey of Ophthalmology*, **64**, 205-221.