

# Modified Z-Plasty for Reconstruction of Webbed Scar Contractures

Xinfeng Huang<sup>1\*</sup>, Jiaqi Xu<sup>1\*#</sup>, Yujie Cui<sup>2</sup>, Guangjin Su<sup>1</sup>, Feifei Chen<sup>1</sup>

<sup>1</sup>Department of Burn and Plastic Surgery, The Fifth Affiliated Hospital Sun Yat-sen University, Zhuhai, China

<sup>2</sup>Department of Rheumatology, The Fifth Affiliated Hospital Sun Yat-sen University, Zhuhai, China

Email: #412359823@qq.com

**How to cite this paper:** Huang, X.F., Xu, J.Q., Cui, Y.J., Su, G.J. and Chen, F.F. (2023) Modified Z-Plasty for Reconstruction of Webbed Scar Contractures. *International Journal of Clinical Medicine*, 14, 233-238. <https://doi.org/10.4236/ijcm.2023.144019>

**Received:** February 15, 2023

**Accepted:** April 25, 2023

**Published:** April 28, 2023

Copyright © 2023 by author(s) and Scientific Research Publishing Inc.

This work is licensed under the Creative Commons Attribution International License (CC BY 4.0).

<http://creativecommons.org/licenses/by/4.0/>



Open Access

## Abstract

**Rationale:** Webbed scar contractures deformity caused by burns and other factors will lead to joint disorders and affect the mental health of patients, resulting in a severe decline in quality of life. Rapid, effective and less complicated surgical methods can help patients with post-burn rehabilitation. **Objective:** This article argues that a modified Z-plasty can quickly improve the range of motion caused by webbed scar contractures in joint areas, including surgical methods, postoperative care and prognosis. **Methods and Results:** The study took place from 2018 to 2022. Thirty-two patients with joint scar contracture deformity, with a mean age of 32.5 years, were included in the study. All patients underwent contracture scar revision and modified Z-plasty repair under anesthesia. All the flaps survived and the joint function was improved. Compared with the traditional Z-plasty, the duration of the operative procedure of the modified Z-plasty was significantly shorter, more surrounding scar tissue was mobilized, and the effectiveness of postoperative scar contracture release was better. **Discussions:** The modified Z-plasty for scar contracture deformity in joint area is simple, rapid, effective and easy to manage.

## Keywords

Modified Z-Plasty, Surgical Flaps, Contracture, Plastic Surgery Procedures

## 1. Introduction

Webbing is the skin and soft tissue linking the entire path up the digits. The distal end of the web space reaches the middle of the proximal phalanx, on the same plane as the volar skin, and forms an inclined plane with the dorsal skin. The

\*Xinfeng Huang and Jiaqi Xu contributed equally to the paper.

#Corresponding author.

normal rhombus network structure of the web between the fingers is the prerequisite for adduction, abduction, arbitrary flexion and extension [1].

The hand is a part with various tissues, joints and functions. Without scientific and appropriate treatment, second-degree burns of the hand often leave a scar and even result in contracture, which affects hand function and dexterity. Postburn contractures can lead to deformities [2]. Due to the lack of soft tissue near the contracture area, scar revision surgery, including release and defect repair, is a challenging problem.

The webbed scar of the crotch joint was released as usual using a continuous standard Z-plasty [3] [4]. The standard 5-flap Z-plasty has some limitations, such as a limited degree of scar release and extension and prolonged operative duration. At the same time, the mobilization of organizations is limited. The modified Z-plasty is an effective technique to prevent the above problems.

## 2. Materials and Methods

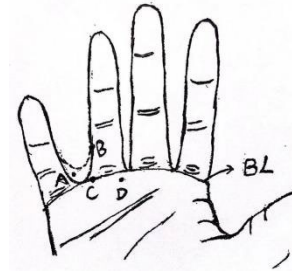
Thirty-two patients enrolled from 2018 to 2022 with joint scar contracture deformity, with a mean age of 32.5 years, were included in the study. The same surgeon, who strictly controlled the indications, performed all operations. All patients underwent incision or resection and modified Z-plasty of the scar under anesthesia. The patients suffered from contracture of the hand for at least one year, which was localized in web spaces, flexor surfaces of the digits, broad palm and extensor surfaces of the hand. The severity of contracture is classified as mild as the scar moderately restricts certain hand movements, and adequate soft tissue, according to the algorithm for releasing burn contractures described by Hudson and Renshaw [5].

### 2.1. Surgical Approach

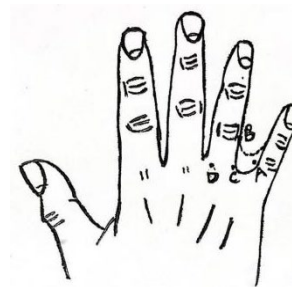
In terms of design, there are some anatomical landmarks to be addressed: the arch of the normal interdigital spaces, which is the line of articulation of the metacarpophalangeal's horizontal stripes, is called the basic line (BL). The highest point of the web space scar was designed as B and the lowest as C, taking BC as the middle arm,  $AB = BC = CD$ . Point A is on the dorsal side. Points C and D are on the volar side (Figure 1). When the flap (A-B-C) is turned to the dorsal palmar side, point B is fixed, and point A is switched with points C and D (Figure 2). The angle between ABC is 30 to 45 degrees and BCD is 90 degrees. The shaded tissue needs to be excised to avoid affecting flap transposition (Figure 3).

1) Concerning scar blood vessel density, the dorsal palmar scar tissue should be at least tender or pliable according to the modified VSS (Vancouver Scar Scale) [6].

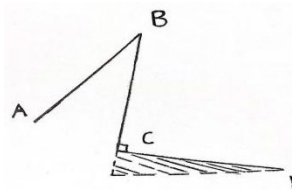
2) In some cases, the design needs to be changed slightly, which is when the metacarpophalangeal joint (MCP) is extended and flexed; it is guided by skin activity.



**Figure 1.** The highest point of the web space scar was designed as B and the lowest as C, taking BC as the middle arm,  $AB = BC = CD$ . Point A is on the dorsal side; points C and D are on the volar side.



**Figure 2.** Point B is fixed, and point A is switched with point C and D.

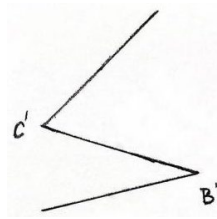


**Figure 3.** The shaded tissue needs to be excised to avoid affecting flap transposition.

A tourniquet was placed on the upper arm near the axilla to prevent intraoperative bleeding from affecting the operation. The incision was made toward A-B-C-D, and the skin and subcutaneous fascia were opened. Carefully separate the fascia layer to avoid finger blood vessels and nerve damage. Cut through the scar tissue. Haemostasis is achieved using bipolar electrocautery. Moving the flap, point B was transferred to point D, and point C was transferred to point A, and fixed with 5-0 Puling suture. The shape of the flap after transposition like reverse z-shape (**Figure 4**).

## 2.2. Postoperative Treatment

The wound was covered with a light dressing for three days. Remove blood scabs and secretions carefully during dressing change. Sutures were removed 12 - 14 days after surgery. After the sutures were removed, anti-scar treatment was performed for over half a year.



**Figure 4.** The shape of the flap after transposition.

### 3. Results

Our technique was applied to 32 patients (mostly in the upper limb) with burn contracture in the following areas: neck (5 cases), axilla (10 cases), forebreast (3 cases), thigh (2 cases), and hand (12 cases). The mean operative time for a webbed scar on the hand and other joint areas was 15 minutes and 30 minutes, respectively.

The postoperative results are shown in **Figure 5**. Sutures were removed 7 days after neck surgery, 10 days after thoracic surgery, and 12 - 14 days after limb surgery. All wounds healed well, no skin congestion, necrosis or other complications, and postoperative scar contracture was satisfactorily relieved. However, we failed to contact patients for long-term follow-up.

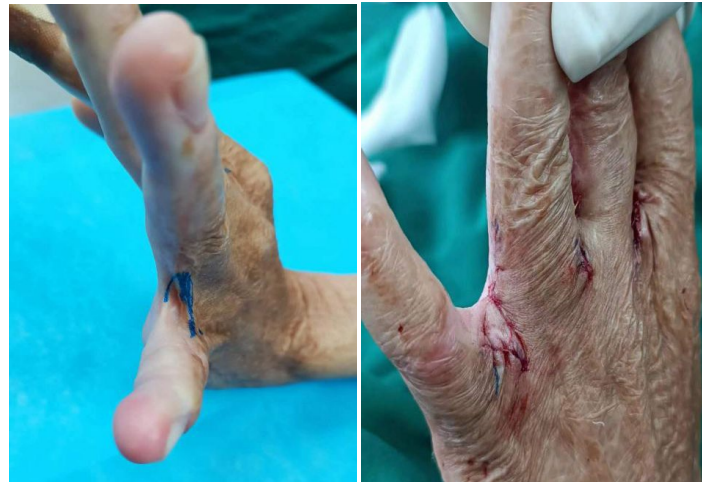### 4. Discussion

The joint is an important fulcrum for the limb to maintain good function [7]. First, the most crucial function of joints is movement, and every joint of the human body is inseparable from movement. Second, joints act as a buffer against force. Third, joints are designed to withstand gravity, supporting weight and other stresses. Fourth, the joint can act as pivots and form a lever in the human body's activities [8].

Burns, scalds or wounds across joints may cause a hypertrophic scar or contracture scar, which may affect joint function. Webbing of scar mostly develops from the cross-joint area and requires surgery to release the tension. Webbed scar revision surgery should be performed until the scar matures and softens, which can be over half a year or longer. This can ensure the best possible surgical outcomes. Especially for the burn syndactyly, the web-space scar has little impact on the flexion and extension of the finger, making it possible to wait longer.

Examining the donor scar to understand what may be underneath it is very important. The Vancouver Scar Scale is an effective method to evaluate the condition of the scar, especially in evaluating treatment effects [9]. The more flexible the scar tissue, the greater it is potential to repair all components of the interphalangeal joints: its depth, shape, groove, and inclination to the metacarpal head.

The finger blood supply is abundant due to the modification of the Z-plasty, which has a larger Angle (the minimum angle is greater than 30 degrees), providing a reliable blood supply and avoiding necrosis of the tissue flap. If the local



**Figure 5.** Comparison between preoperative and postoperative contracture deformity of the web space between the fourth and fifth fingers.

flap angle is less than 30 degrees, the probability of flap necrosis increases [10] [11].

Most of the mature webbed scars were repaired by Z-plasty, multiple Z-plastics in series or the 5-flap technique. However, due to the limitation of the included angle and the force of tension, the length of the prolonged scar is limited, so the conventional Z-plasty is ineffective in treating a webbed scar. The greater the angle of the outer arm of the Z-plasty, the longer the extension of the middle arm. The angle between the outer arms is 30 degrees, and the middle arm is extended by 25%, 60 degrees is 75%, and 90 degrees is 120% [12].

## 5. Conclusion

The modified Z-plasty has a larger angle, more surrounding scar tissue is mobilized, the postoperative scar tissue is released, and the recurrence probability is negligible. Moreover, the operative time is significantly reduced due to the single Z-plasty. With a large angle, a flap has a sufficient blood supply. The flap is oblique in design. The adjacent fingers do not interfere with each other, which is suitable for the simultaneous operations of multiple fingers.

## Conflicts of Interest

The authors declare no conflicts of interest regarding the publication of this paper.

## References

- [1] Bowers, W., Wolf Jr., J.W., Nehil, J.L., *et al.* (1980) The Proximal Interphalangeal Joint Volar Plate. An Anatomical and Biochemical Study. *Journal of Hand Surgery*, 5, 79-88. [https://doi.org/10.1016/S0363-5023\(80\)80049-9](https://doi.org/10.1016/S0363-5023(80)80049-9)
- [2] Pegahmeh, M., Hafezi, F., Naghibzadeh, B., *et al.* (2008) Multiple V-Y Advancement Flaps: A New Method for Axillary Burn Contracture Release. *Plastic and Re-*

- constructive Surgery*, **122**, 44e-45e. <https://doi.org/10.1097/PRS.0b013e31817745e5>
- [3] Hudson, D. (2000) Some Thoughts on Choosing a Z-Plasty: The Z Made Simple. *Plastic and Reconstructive Surgery*, **106**, 665-671. <https://doi.org/10.1097/00006534-200009010-00024>
- [4] Jones, L.A. and Hodges, A.H. (1985) Application of the 5-Flap Z Plasty in Digital Flexion Contractures. *Plastic and Reconstructive Surgery*, **76**, 302-308.
- [5] Hudson, D.A. and Renshaw, A. (2006) An Algorithm for the Release of Burn Contractures of the Extremities. *Burns*, **32**, 663-638. <https://doi.org/10.1016/j.burns.2006.02.009>
- [6] Bae, S.H. and Bae, Y.C. (2014) Analysis of Frequency of Use of Different Scar Assessment Scales Based on the Scar Condition and Treatment Method. *Archives of Plastic Surgery*, **41**, 111-115. <https://doi.org/10.5999/aps.2014.41.2.111>
- [7] Goldfarb, C. and Boyer, M. (2009) Soft Tissue and Joint Contracture. In: Guyuron, B., Eriksson, E. and Persing, J., Eds., *Plastic Surgery Indications and Practice*, Saunders Elsevier, Philadelphia, 1165-1171.
- [8] Kwan, P., Hori, K., Ding, J., *et al.* (2009) Scar and Contracture: Biological Principles. *Hand Clinics*, **25**, 511-528. <https://doi.org/10.1016/j.hcl.2009.06.007>
- [9] Fearmonti, R., Bond, J., Erdmann, D. and Levinson, H. (2010) A Review of Scar Scales and Scar Measuring Devices. *Eplasty*, **10**, e43.
- [10] Zhang, L., *et al.* (2014) Reversed Z-Plasty and Its Variations to Release Wide-Scar Contraction. *Burns*, **40**, 1185-1188. <https://doi.org/10.1016/j.burns.2013.12.016>
- [11] Yotsuyanagi, T., Yamashita, K., Gonda, A., *et al.* (2013) Double Combined Z-Plasty for Wide-Scar Contracture Release. *Journal of Plastic, Reconstructive & Aesthetic Surgery*, **66**, 629-633. <https://doi.org/10.1016/j.bjps.2013.01.027>
- [12] Rohrich, R.J. and Zbar, R.I. (1999) A Simplified Algorithm for the Use of Z-Plasty. *Plastic and Reconstructive Surgery*, **103**, 1513. <https://doi.org/10.1097/00006534-199904050-00024>