

Anatomical Dissection Study of the Thyroid Gland: A Report on 24 Anatomical Specimens

Ousmane Koulibaly¹, Ndeye Bigué Mar¹, Makessa Camara², Jaafar Ibn Talib Thiam¹, Aïnina Ndiaye¹, Mamadou Diop¹, Bay Karim Diallo², Cherif Mohamed Moustapha Dial³

¹Anatomy Laboratory, Cheikh Anta Diop University, Dakar, Senegal

²ENT Department, Albert Royer Hospital, Dakar, Senegal

³Pathological Anatomy Department, Idrissa Pouye General Hospital, Dakar, Senegal

Email: Koulibalyousmane8@gmail.com

How to cite this paper: Koulibaly, O., Mar, N.B., Camara, M., Thiam, J.I.T., Ndiaye, A., Diop, M., Diallo, B.K. and Dial, C.M.M. (2026) Anatomical Dissection Study of the Thyroid Gland: A Report on 24 Anatomical Specimens. *Forensic Medicine and Anatomy Research*, 14, 1-15.

<https://doi.org/10.4236/fmar.2026.141001>

Received: November 3, 2025

Accepted: December 5, 2025

Published: December 8, 2025

Copyright © 2026 by author(s) and Scientific Research Publishing Inc. This work is licensed under the Creative Commons Attribution International License (CC BY 4.0).

<http://creativecommons.org/licenses/by/4.0/>



Open Access

Abstract

Introduction: The objective of this study was to analyze the morphometry and anatomical relationships of the thyroid gland through dissection. **Materials and Methods:** This was a prospective descriptive anatomical study conducted over a 5-month period, from July 7, 2024 to November 27, 2024, involving dark-skinned anatomical subjects who met the inclusion and exclusion criteria, and were dissected in the autopsy rooms of the pathology departments of Idrissa Pouye General Hospital and Dalal Jamm Hospital. **Results:** A total of 24 anatomical subjects were dissected. There were 18 males (75%) and 6 females (25%), with a sex ratio (F/M) = 0.33. The mean thyroid diameter was 5.9 cm ± 0.57 (range: 5.1 - 7.32 cm). The mean height of the left lobe was 4.7 cm ± 0.78 (range: 3.2 - 5.4 cm), and that of the right lobe was 4.61 cm ± 0.93 (range: 2.9 - 6.3 cm). The mean height of the isthmus was 2.3 cm ± 0.74 (range: 1 - 2.41 cm). The left recurrent laryngeal nerve (RLN) passed posterior to the inferior thyroid artery in 16 cases (66.7%), transvascular in 6 (25%), and prevascular in 2 (8.3%). On the right, the RLN was retrovascular in 12 (50%), prevascular in 8 (33.3%), and transvascular in 4 (16.7%). All parathyroid glands found were posterior. Sixteen specimens (66%) had four parathyroids, while five (20%) had two. **Conclusion:** Thyroid dissection highlighted significant morphometric variability and diverse relationships with the recurrent laryngeal nerves and inferior thyroid arteries, as well as variations in parathyroid gland distribution. Awareness of these variations is critical to preventing post-thyroidectomy complications.

Keywords

Morphometry, Thyroid, Anatomical Relations

1. Introduction

The thyroid is an unpaired, median endocrine gland located at the base of the neck, beneath the larynx and in front of the trachea. Weighing about 20 - 30 g, it secretes hormones that regulate growth, basal metabolism, and thermoregulation [1].

The right lobe is usually larger than the left, and adult size is reached by age 15 [2].

Thyroid surgery is a major component in the management of both benign and malignant thyroid diseases. In Senegal, the recurrence of goiter following medical treatment has led to numerous thyroidectomies [3], which require multidisciplinary collaboration among endocrinologists, surgeons, and radiologists.

Given the rich neurovascular structures in this region, thyroid surgery carries significant risks of vital and functional complications [4]. A precise understanding of thyroid anatomy is therefore essential.

This study aimed to analyze the morphometry and anatomic relationships of the thyroid gland through dissection.

2. Materials and Methods

The study was conducted at the Laboratory of Anatomy and Organogenesis of Cheikh Anta Diop University in Dakar, and within the pathology departments of Dalal Jamm Hospital and Idrissa Pouye General Hospital in Grand Yoff.

It was a prospective descriptive anatomical study carried out over a period of five months, from July 7, 2024, to November 27, 2024.

The study involved 24 dark-skinned anatomical subjects meeting the inclusion and exclusion criteria, obtained from the autopsy rooms of the pathology departments of Idrissa Pouye General Hospital and Dalal Jamm Hospital.

All adult anatomical specimens of both sexes, without any surgical scars on the anterior aspect of the neck, were included in this study.

Exclusion criteria included decomposed specimens, children under 15 years of age, and specimens presenting a surgical scar on the anterior neck.

Unidentified anatomical specimens were preserved in the cold chambers of the pathology departments. Upon arrival at the laboratories, they were registered, and details such as the day, date, and time of entry, body habitus, and clothing were recorded. Each specimen was assigned a number and stored either in a freezer or in a refrigerator operating continuously (24 hours a day).

The materials used for the dissection included: **(Figure 1)**

Scalpel blades No. 23

Scalpel handle No. 4

Dissecting forceps without teeth

Two Kocher forceps with teeth

Two Kocher forceps without teeth

Two Farabeuf retractors

One pair of fine curved scissors with pointed ends

- One pair of curved scissors of the Metzenbaum type
- One needle holder
- A graduated measuring tape
- A 180° protractor
- Non-absorbable sutures
- Data collection sheet

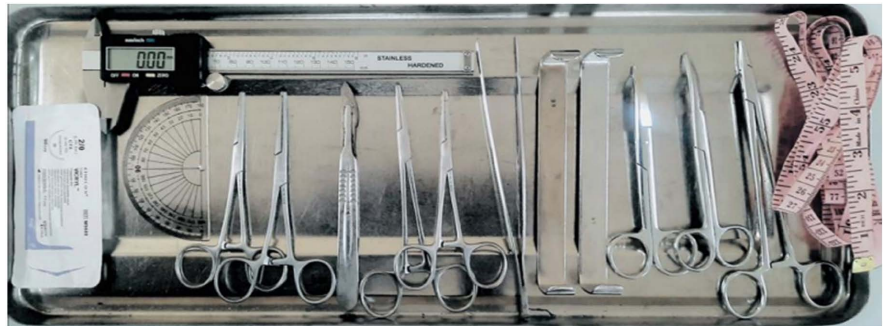

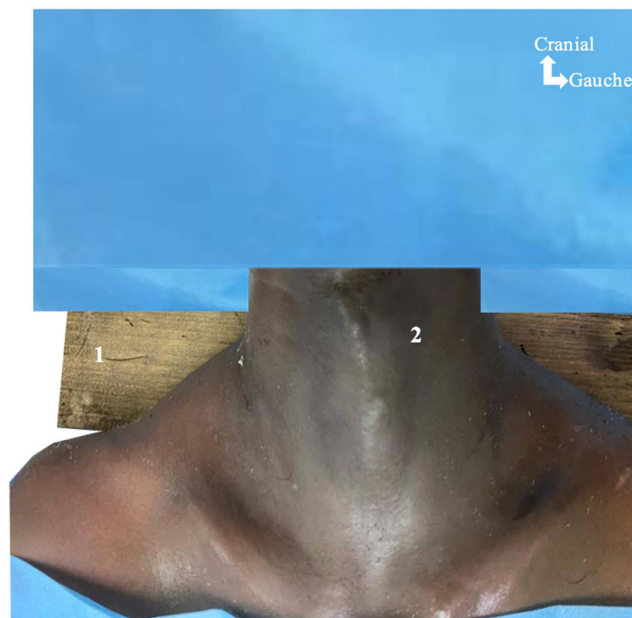
Figure 1. Equipment used for the dissection.

All the anatomical subjects were positioned following several steps:

Position: Supine position on the autopsy table;

Support: Placement of a wooden block (billot) under the scapulae to expose the anterior surface of the neck;

Draping: A surgical drape was placed over the face and thorax (**Figure 2**).



1: Wooden block (billot); 2: Anterior surface of the neck.

Figure 2. Exposure of the anterior surface of the neck in one of the anatomical specimens.

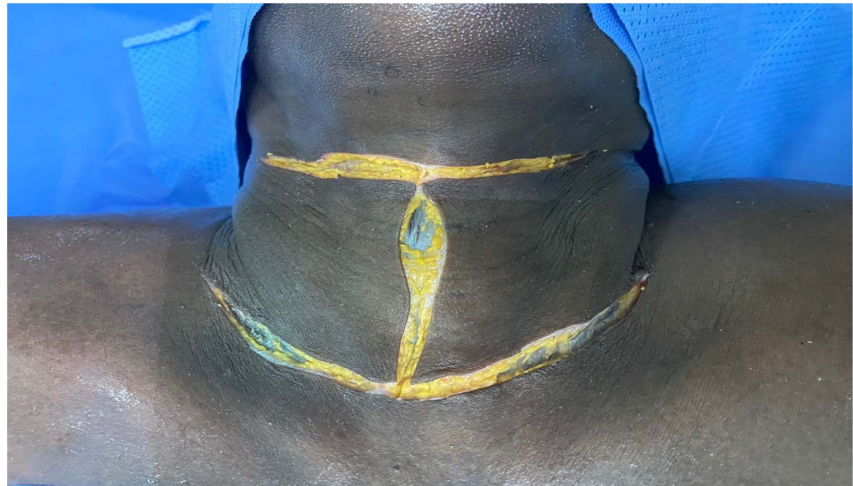The surgical approach was performed through a triple cervical incision, as

shown in **Figure 3**:

The first incision was a transverse, arc-shaped cervical incision with a superior concavity, made 2 cm (approximately two fingerbreadths) above the suprasternal notch, involving the skin;

The second incision was another transverse cervical incision, made 2 cm above the hyoid bone, also involving the skin;

The third incision was a vertical median cervical incision, joining the two previous transverse incisions.

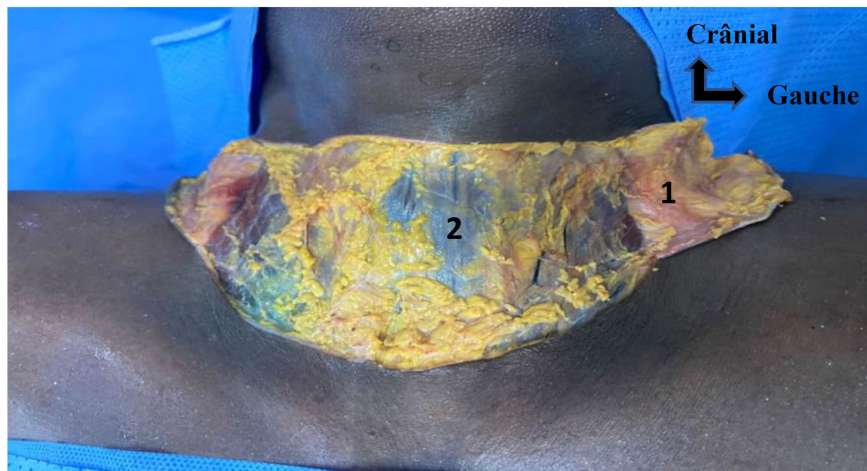


1: Inferior transverse incision (ITI); 2: Superior transverse incision (ITS); 3: Vertical incision (VI).

Figure 3. Surgical approach.

The following procedure was performed during the dissection:

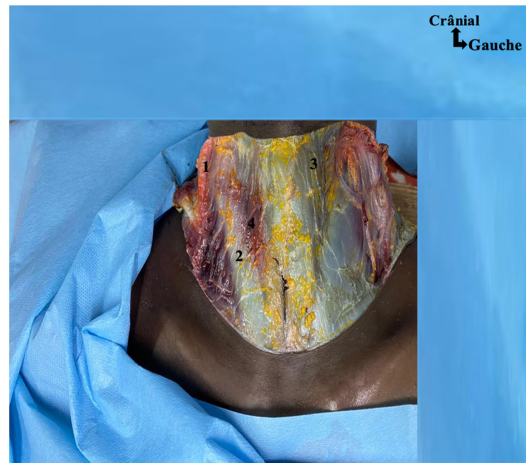Elevation of the right and left skin flaps, as illustrated in the corresponding **Figure 4**.



1: Right skin flap; 2: Muscular plane.

Figure 4. Elevation of the right and left skin flaps.

The anterior cervical muscles were then exposed, as illustrated in **Figure 5** below.



1: Platysma muscle; 2: Sternocleidomastoid muscle; 3: Thyrohyoid muscle; 4: Sternothyroid muscle.

Figure 5. Exposure of the anterior cervical muscles of an anatomical specimen (after removal of the skin and subcutaneous tissue).

A vertical incision was made along the midline through the superior and middle cervical fasciae.

The anterior cervical muscles were then dissected, with retraction of the sternocleidohyoid (SCH) muscle, allowing exposure of the thyroid compartment, as shown in **Figure 6**.

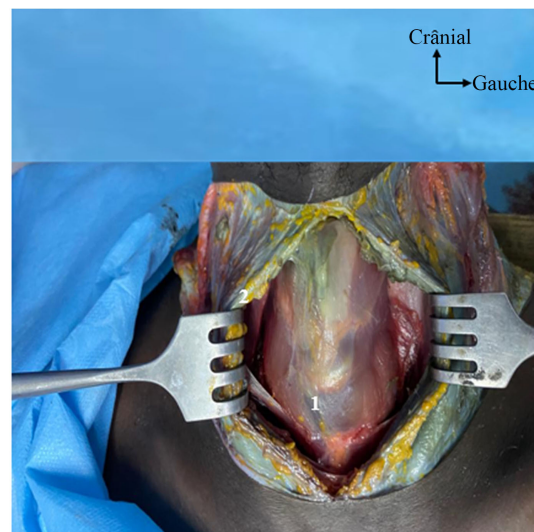
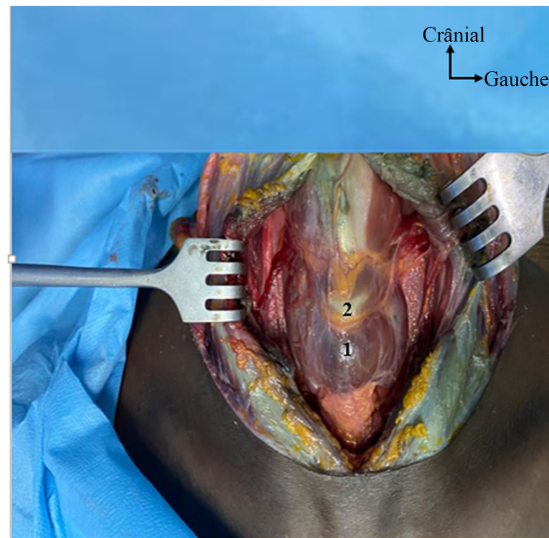


Figure 6. Muscular dissection and exposure of the thyroid compartment.

The thyroid compartment was dissected by digital separation and retraction using Farabeuf retractors.

This maneuver allowed exposure of the thyroid gland and the trachea, as illus-

trated in **Figure 7**.



1: Thyroid gland; 2: Cricoid cartilage.

Figure 7. Opening of the thyroid compartment.

Morphometric Study

Millimetric tape measurements were taken to determine the thyroid diameter, height of the lobes, and height of the isthmus.

A careful dissection was performed to identify the relationships between the recurrent laryngeal nerve and the inferior thyroid artery, as well as to locate the parathyroid glands on the posterior surface of the thyroid.

The pyramidal lobe represents an embryological remnant of the thyroglossal duct, whose persistence explains its inconsistent presence as well as its variable length and location along the cervical midline.

For each anatomical specimen, we conducted:

Anthropometric description, followed detailed morphometric and topographic anatomical study of the thyroid gland and its relations.

The following parameters were recorded:

Sex of the anatomical specimen;

Height and cervical circumference;

Thyroid diameter;

Height of the thyroid lobes;

Height of the thyroid isthmus;

Relationship of the inferior laryngeal (recurrent) nerve to the inferior thyroid artery;

Position of the superior and inferior parathyroid glands in relation to the thyroid.

Data were manually collected using pre-established data sheets and analyzed using SPSS software.

The writing and presentation were carried out using Microsoft Word, Excel,

and PowerPoint (Office 2020 suite).

3. Results

During the study period, 24 adult anatomical specimens of both sexes were dissected.

Among them, 18 were male (75%) and 6 were female (25%), giving a sex ratio (F/M) = 0.33.

The following table (**Table 1**) presents the distribution of anatomical specimens according to average height and cervical circumference.

Table 1. Distribution of anatomical specimens according to height and cervical circumference.

Height (cm)	Number	%	Cervical Circumference (cm)	Number	%
150 - 160	5	20.83	39	8	33.33
161 - 170	12	50.00	38	9	37.50
>170	7	29.17	37	4	16.67
Total	24	100	24	100	100

The mean thyroid diameter was 5.9 cm, with a standard deviation of 0.57 cm.

The extremes ranged from 5.1 cm to 7.32 cm.

Table 2 below presents the distribution of anatomical specimens according to thyroid diameters.

Table 2. Distribution of anatomical specimens according to thyroid diameters.

Thyroid diameter (cm)	Number (n)	Frequency (%)
≤6.0	9	37%
6.1 - 6.5	12	50%
>6.5	3	13%
Total	24	100%

Figure 8 below illustrates the anterior view of the thyroid gland in one of the anatomical specimens.

The mean height of the left thyroid lobes was 4.7 cm, with a standard deviation of 0.78 cm.

The minimum and maximum values were 3.2 cm and 5.4 cm, respectively.

The distribution of anatomical specimens according to the height of the left thyroid lobe is presented in **Table 3** below.

Table 3. Distribution of anatomical specimens according to the average height of the left thyroid lobe.

Height (cm)	Number (n)	Percentage (%)
≤3.5	8	33%
3.5 - 5.0	13	54%
>5.0	3	13%
Total	24	100%

The mean height of the right thyroid lobes was 4.61 cm, with a standard deviation of 0.93 cm.

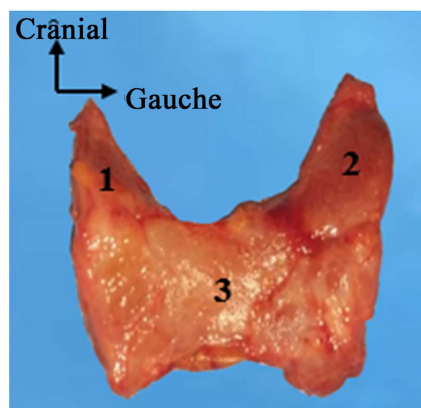
The extremes ranged from 2.9 cm to 6.3 cm.

The distribution of specimens according to the height of the right thyroid lobe is summarized in **Table 4**.

Table 4. Distribution of anatomical specimens according to the average height of the right thyroid lobe.

Height (cm)	Number (n)	Percentage (%)
≤4.0	9	38%
4.0 - 4.5	7	29%
4.5 - 5.0	5	20%
>5.0	3	13%
Total	24	100%

Figure 8 below shows the posterior view of a specimen, illustrating the average height of the right thyroid lobe



1: Right lobe—4.2 cm; 2: Left lobe—5.0 cm; 3: Isthmus—2.0 cm.

Figure 8. Anterior view of a dissected specimen showing average measurements.

The mean height of the thyroid isthmus was 2.3 cm, with a standard deviation of 0.74 cm.

The minimum and maximum values were 1.0 cm and 2.41 cm, respectively.

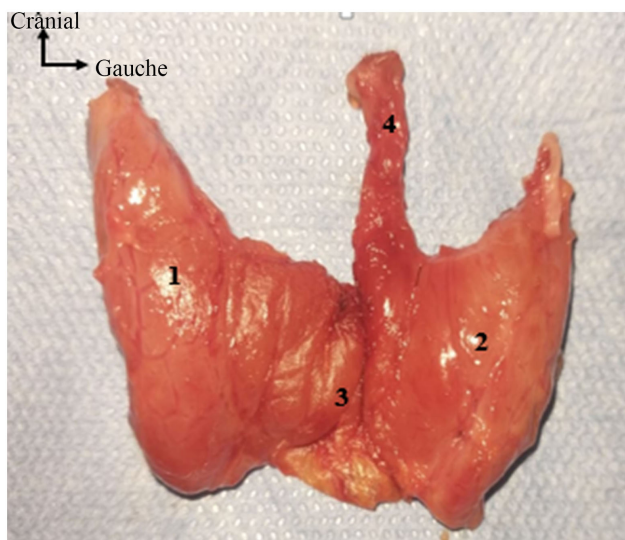
The distribution of anatomical specimens according to the average height of the isthmus is presented in **Table 5** below.

Table 5. Distribution of anatomical specimens according to the height of the isthmus.

Isthmus height (cm)	Number (n)	Percentage (%)
≤1.0	5	21%
1.0 - 1.5	4	16%
>1.5	15	63%
Total	24	100%

The distribution of Anatomical Specimens According to the Presence or Absence of the Median (Pyramidal) Lobe

In our sample, 20% of the specimens presented a median lobe, also known as the pyramidal lobe, as illustrated in **Figure 9** below.



1: Right lobe; 2: Left lobe; 3: Isthmus; 4: Pyramidal lobe.

Figure 9. Posterior view of the thyroid gland showing the pyramidal lobe.

After the dissections, it was observed that all identified parathyroid glands were located on the posterior surface of the thyroid.

They were cranial and caudal when four glands were present, and cranial only when there were two or a single gland.

The majority of specimens (16; 66%) contained four parathyroid glands, followed by five specimens (20%) with two glands, and one specimen (4%) with a single gland.

In two specimens, no parathyroid glands were identified.

We also found that in 16 subjects (66.7%), the left recurrent laryngeal nerve (RLN) passed posterior to the ipsilateral inferior thyroid artery (retrovascular type).

In six subjects (25%), the nerve crossed the artery from anterior to posterior (transvascular type), and in two subjects (8.3%), it passed anterior to the artery (prevascular type).

These findings are summarized in **Table 6** below.

Table 6. Distribution of specimens according to the relationship between the left recurrent laryngeal nerve and the left inferior thyroid artery.

Left-side relationship	Number (n)	Percentage (%)
Retrovascular	16	66.7%
Transvascular	6	25.0%
Prevascular	2	8.3%
Total	24	100%

The relationship between the right recurrent laryngeal nerve and the right inferior thyroid artery was also studied.

We found that 12 specimens (50%) exhibited a retrovascular arrangement, 8 (33.3%) were prevascular, and 4 (16.7%) were transvascular (**Figure 10**).

These findings are detailed in **Table 7** below.

Table 7. Distribution of specimens according to the relationship between the right recurrent laryngeal nerve and the right inferior thyroid artery.

Right-side relationship	Number (n)	Percentage (%)
Retrovascular	12	50.0%
Prevascular	8	33.3%
Transvascular	4	16.7%
Total	24	100%

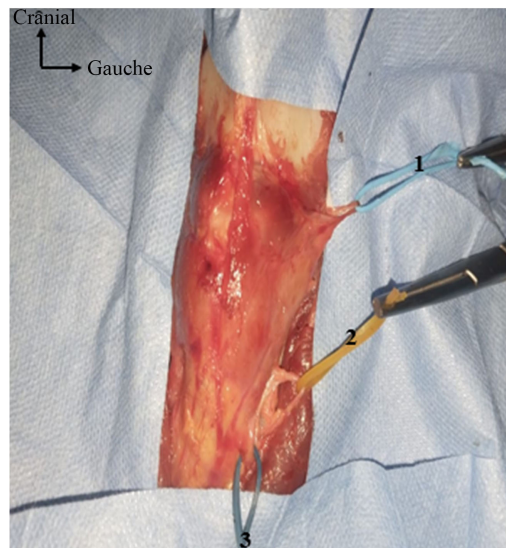


Figure 10. Relationship between the left recurrent laryngeal nerve and the left inferior thyroid artery.

4. Discussion

Our study presents the morphometric characteristics of the thyroid gland and some of its anatomical relationships, emphasizing their anatomical variations. The data were obtained from the dissection of 24 specimens collected from fresh melanodermic anatomical subjects.

We used anatomical dissection to determine the morphometric and morphological variations of the thyroid gland. The choice of dissection was justified by the limited availability of anatomical data derived from human specimens in our region. In addition, anatomical dissection allows a direct three-dimensional visualization of fine structures that are difficult to identify through imaging, particularly the terminal branches of the inferior thyroid artery in close relationship with the recurrent laryngeal nerve, as well as their topographic variations, which are

crucial for reducing the risk of intraoperative nerve injury.

Dissection allows direct observation, a fundamental step in anatomical study, making it possible to identify the pyramidal lobe, to perform direct measurements of the lobes and the isthmus, and to study their anatomical relationships.

The thyroid gland is a superficial organ, which makes it easily accessible to ultrasound examination, explaining why some authors, such as N'DRI *et al.* [4], chose imaging-based approaches. They reported that real-time ultrasonography provides an accuracy comparable to MRI, with important implications for surgical decision-making, particularly in procedures involving the tricuspid valve.

Similarly, Tsujio [5] used three-dimensional echocardiography to assess the embryology, size, and morphology of the thyroid gland.

We preferred the dissection method to study anatomical variations, unlike those authors [4] [5] who opted for indirect imaging methods. Dissection remains a direct and realistic approach, despite the difficulties in specimen availability.

The thyroid gland is known for its marked variability in size and structure [6]. Most of these anatomical variations result from variable persistence of the embryonic thyroglossal duct [7].

Thyroid diseases such as goiter, thyrotoxicosis, adenoma, and carcinoma are typically associated with thyroid enlargement, requiring medical and surgical intervention [6].

In our study, the mean thyroid diameter was 5.9 cm. Most authors measured the lateral lobes and isthmus separately. According to classical anatomical references, the lateral lobes measure 5 cm in length, 3 cm in width, and 2 cm in thickness [8].

The mean height of the left thyroid lobe in our study was 4.7 cm, while that of the right lobe was 4.61 cm. This finding contrasts with the commonly reported observation that the right lobe is slightly larger than the left [9] [10]. A comparison of our findings with those from the literature is summarized in **Table 8** below.

Table 8. Comparison of lateral lobe sizes.

Study	DT	LG	LD
Our study	6.7	4.20	4.58
Joshi <i>et al.</i> [10]	–	4.22	4.32
Dessie <i>et al.</i> [11]	–	4.08	4.24
Prakash <i>et al.</i> [12]	–	2.54	2.63
Dixit <i>et al.</i> [13]	–	4.95	5.29
Asha <i>et al.</i> [14]	–	4.74	5.32

In this study, all subjects had an isthmus, unlike the findings of Dessie *et al.* [11], who reported absence of the thyroid isthmus in 7.5% of cadavers, and Rajkonwar and Kurse [9] [13], who found 21.25% absence.

Thyroid isthmus agenesis is defined as the complete congenital absence of the

isthmus [15]. A high division of the thyroglossal duct may produce two separate lobes without an isthmus [13].

The median (pyramidal) lobe was found in 5 specimens (20%) in our series. Kulkarni *et al.* [16] and Asha *et al.* [14] did not observe a pyramidal lobe in their dissections of 20 and 15 specimens, respectively.

Our results are comparable to those of Begum *et al.* [17], who reported the pyramidal lobe in 26.7% of subjects, but lower than those of Rajkonwar and Kurse [9], who found 38.75%, and other authors who reported 58%, 41%, and 46%, respectively [7] [18] [19].

The frequency of pyramidal lobe identification in cadaveric studies appears to increase proportionally with sample size. The pyramidal lobe is a remnant of the thyroglossal duct, explaining its inconsistent presence and variable location.

In our series, four parathyroid glands were identified in 16 subjects (66%), consistent with Hojaij *et al.* [19], who found four glands in 78.6% of cases and two glands in 1.8%.

Although most individuals have four parathyroid glands, supernumerary glands (five or more) are occasionally observed, often located near the thymic region [20]-[22].

Lefevre *et al.* [23] reported four glands in 80% - 84%, three glands in 3% - 13%, and five or more in 2.2% - 20% of cases. Instances of two or six glands were rare [23].

The anatomical relationship between the recurrent laryngeal nerve (RLN) and the inferior thyroid artery (ITA) is highly variable. The ITA generally arises from the thyrocervical trunk and supplies the thyroid gland, while the RLN, a mixed branch of the vagus nerve, typically passes anterior to the ITA on the right and posterior to it on the left. Occasionally, the nerve crosses between the arterial branches [24], a relationship confirmed by multiple studies [25] [26].

Our findings support these observations: the left RLN was retrovascular in 16 cases (66.3%), and the right RLN was prevascular in 8 cases (33.3%).

These results are comparable to those reported by Kaisha *et al.* [27], who found the nerve anterior to the ITA in 37% and posterior in 51.4% of cases.

Ozguner and Suker [26] classified the RLN-ITA relationship into seven types:

Type 1: RLN posterior to the artery;

Type 2: RLN anterior to the artery (right 40.5%, left 22.5%);

Type 3: RLN parallel to the artery (right 11.5%, left 7%);

Type 4: RLN located between the arterial branches (right 1%, left 3.5%);

Type 5: Extralaryngeal branch of the RLN identified before crossing the artery (right 4.5%, left 0%);

Type 6: ITA located between the two branches of the RLN (right 0%, left 0.5%);

Type 7: RLN branches interspersed among the arterial branches (right 0%, left 0.5%).

The challenges encountered in this study were primarily related to the transportation of anatomical specimens from the hospital to the anatomy laboratory, a

process complicated by growing security concerns in our setting. Additional limitations include the small sample size. Furthermore, a prolonged waiting period was required to obtain the specimens, as the study exclusively involved unidentified bodies, which were subject to mandatory medico-legal and administrative procedures prior to being released for anatomical dissection.

5. Conclusions

Our study revealed a significant morphometric diversity of the thyroid gland, as well as a variability in the relationships between the recurrent laryngeal nerve and the inferior thyroid artery. We observed a retrovascular course on the left and a prevascular course on the right in 66.7% and 33.3% of cases, respectively, illustrating the absence of a single consistent anatomical configuration.

Furthermore, the variability in the number of parathyroid glands identified highlights the need for increased vigilance during surgical dissections, in order to minimize the risk of postoperative hypoparathyroidism.

Because of its proximity to essential neurovascular structures and the parathyroid glands, the thyroid region represents an area of particular surgical importance. The anatomical relationships between the thyroid, the recurrent laryngeal nerves, and the inferior thyroid arteries, as well as the position of the parathyroid glands, vary from one individual to another. These variations can make procedures such as thyroidectomy delicate and potentially risky.

These findings may have a direct impact on thyroid surgery, especially regarding the preservation of the recurrent laryngeal nerves and parathyroid glands. A comprehensive understanding of these anatomical variations is essential to reduce postoperative complications, notably dysphonia due to nerve injury or hypocalcemia following parathyroid damage.

Conflicts of Interest

The authors declare no conflicts of interest regarding the publication of this paper.

References

- [1] Schaffler, A., Menche, N. and Prudhomme, C. (2004) *Anatomie Physiologie Biologie*. 2e Édition, Maloine.
- [2] Larsen, W. and Dhem, A. (2003) *Embryologie Humaine*. 2e Édition, de Boeck SUP.
- [3] Niang, F., Loum, B. and Diouf, M. (2023) Morphologie et rapports du nerf laryngé inférieur avec l'artère thyroïdienne inférieure à propos de 40 thyroïdectomies. *RECAC*, **4**, 15-22.
- [4] N'dri, K., Konaté, I., Abby, B.C., *et al.* (2006) Les dimensions normales de la thyroïde à l'échographie. *Revue Internationale du Collège d'Odonto-Stomatologie Africain et de Chirurgie Maxillo-Faciale*, **13**, 19-23.
- [5] Tsujio, M., Watahiki, Y., Yoshioka, K. and Mutoh, K. (2007) Morphology of Thyroid Follicular Cells of Methimazole-treated Rats. *Anatomia, Histologia, Embryologia*, **36**, 290-294. <https://doi.org/10.1111/j.1439-0264.2007.00764.x>
- [6] Muktyaz, D.H., Birendra, D.Y., Dhiraj, D.S., *et al.* (2013) Anatomical Variations of

- Thyroid Gland and Its Clinical Significance in North Indian Population. *Global Journal of Biology Agriculture Health Sciences*, 2, 12-16.
- [7] Ranade, A.V., Rai, R., Pai, M.M., *et al.* (2008) Anatomical Variations of the Thyroid Gland: Possible Surgical Implications. *Singapore Medical Journal*, **49**, 831-834.
- [8] (2005) Gray's Anatomy 39th Edition: The Anatomical Basis of Clinical Practice. *American Journal of Neuroradiology*, **26**, 2703-2704.
- [9] Rajkonwar, A.J. (2016) Morphological Variations of the Thyroid Gland among the People of Upper Assam Region of Northeast India: A Cadaveric Study. *Journal of Clinical and Diagnostic Research*, **10**, AC01-AC03. <https://doi.org/10.7860/jcdr/2016/19395.8966>
- [10] Joshi, S.D., Joshi, S.S., Daimi, S.R., *et al.* (2010) The Thyroid Gland and Its Variations: A Cadaveric Study. *Folia Morphologica*, **69**, 47-50.
- [11] Dessie, M.A. (2018) Anatomical Variations and Developmental Anomalies of the Thyroid Gland in Ethiopian Population: A Cadaveric Study. *Anatomy & Cell Biology*, **51**, 243-250. <https://doi.org/10.5115/acb.2018.51.4.243>
- [12] Prakash, Rajini, T., Ramachandran, A., Savalgi, G.B., Venkata, S.P. and Mokhasi, V. (2011) Variations in the Anatomy of the Thyroid Gland: Clinical Implications of a Cadaver Study. *Anatomical Science International*, **87**, 45-49. <https://doi.org/10.1007/s12565-011-0115-9>
- [13] Dixit, D., Shilpa, M., Harsh, M. and Ravishankar, M. (2009) Agenesis of Isthmus of Thyroid Gland in Adult Human Cadavers: A Case Series. *Cases Journal*, **2**, Article No. 6640. <https://doi.org/10.1186/1757-1626-2-6640>
- [14] Asha, S., Dixit, D., Shirol, V., *et al.* (2013) Study of Absence of Isthmus of Thyroid Gland with Its Developmental and Surgical Implications in Adult Human Cadavers: A Case Series. *Medical Innovations*, **3**, 50-52.
- [15] Vázquez, J.F.P., Verona, J.A.G. and Cachorro, M.B. (2006) Agenesis of the Thyroid Isthmus. *European Journal of Anatomy*, **10**, 83-84.
- [16] Kulkarni, V.V., Sreepadma, S. and Deshpande, S.K. (2012) Morphological Variations of the Thyroid Gland. *Medica Innovativa*, **1**, 36-38.
- [17] Begum, M., Khatun, M., Kishwara, S., Ahmed, R. and Naushaba, J. (1970) A Post-mortem Study of the Pyramidal Lobe of the Thyroid Gland in Bangladeshi People. *Journal of Dhaka Medical College*, **18**, 120-123. <https://doi.org/10.3329/jdmc.v18i2.6270>
- [18] Nurunnabi, A.S.M., Alim, A., Mahub, S., Kishwara, S., Begum, M., Khatun, M., *et al.* (1970) Morphological and Histological Study of the Pyramidal Lobe of the Thyroid Gland in Bangladeshi People—A Postmortem Study. *Bangladesh Journal of Anatomy*, **7**, 94-100. <https://doi.org/10.3329/bja.v7i2.6095>
- [19] Hojaij, F., Vanderlei, F., Plopper, C., Rodrigues, C.J., Jácomo, A., Cernea, C., *et al.* (2011) Parathyroid Gland Anatomical Distribution and Relation to Anthropometric and Demographic Parameters: A Cadaveric Study. *Anatomical Science International*, **86**, 204-212. <https://doi.org/10.1007/s12565-011-0111-0>
- [20] Elgazzar, A.H. (2001) The Pathophysiologic Basis of Nuclear Medicine. Springer.
- [21] Veerahanumaiah, S., Dakshayani, K.R. and Menasinkai, S.B. (2017) Morphological Variations of the Thyroid Gland. *International Journal of Research in Medical Sciences*, **3**, 53-57. <https://doi.org/10.5455/2320-6012.ijrms20150110>
- [22] Grassetto, G., Alavi, A. and Rubello, D. (2007) PET and Parathyroid. *PET Clinics*, **2**, 385-393. <https://doi.org/10.1016/j.cpet.2008.04.005>
- [23] Lefevre, J.H., Tresallet, C., Leenhardt, L., Jublanc, C., Chigot, J. and Menegaux, F.

- (2007) Reoperative Surgery for Thyroid Disease. *Langenbeck's Archives of Surgery*, **392**, 685-691. <https://doi.org/10.1007/s00423-007-0201-6>
- [24] Noussios, G., Chatzis, I., Konstantinidis, S., Filo, E., Spyrou, A., Karavasilis, G., *et al.* (2020) The Anatomical Relationship of Inferior Thyroid Artery and Recurrent Laryngeal Nerve: A Review of the Literature and Its Clinical Importance. *Journal of Clinical Medicine Research*, **12**, 640-646. <https://doi.org/10.14740/jocmr4296>
- [25] Sultana, S., Khan, M., Rahman, H., Hossain, A., Sultana, S., Hasan, N., *et al.* (2007) Morphological Study of Recurrent Laryngeal Nerve in Relation to Thyroid Gland. *Mymensingh Medical Journal*, **15**, 192-196. <https://doi.org/10.3329/mmj.v15i2.43>
- [26] Özgüner, G. and Sulak, O. (2014) Arterial Supply to the Thyroid Gland and the Relationship between the Recurrent Laryngeal Nerve and the Inferior Thyroid Artery in Human Fetal Cadavers. *Clinical Anatomy*, **27**, 1185-1192. <https://doi.org/10.1002/ca.22448>
- [27] Kaisha, W., Wobenjo, A. and Saidi, H. (2011) Topography of the Recurrent Laryngeal Nerve in Relation to the Thyroid Artery, Zuckerkandl Tubercle, and Berry Ligament in Kenyans. *Clinical Anatomy*, **24**, 853-857. <https://doi.org/10.1002/ca.21192>