

Endobronchial Cocaine Packet Aspiration Managed via Flexible Bronchoscopy

Gary Azzopardi, Ishana Chatlani, Sean Pace^{ORCID}, David Bilocca

Department of Medicine, Mater Dei Hospital, Msida, Malta

Email: gary.azzopardi@gov.mt

How to cite this paper: Azzopardi, G., Chatlani, I., Pace, S. and Bilocca, D. (2026) Endobronchial Cocaine Packet Aspiration Managed via Flexible Bronchoscopy. *Case Reports in Clinical Medicine*, 15, 100-106. <https://doi.org/10.4236/crcm.2026.153014>

Received: February 1, 2026

Accepted: March 6, 2026

Published: March 10, 2026

Copyright © 2026 by author(s) and Scientific Research Publishing Inc. This work is licensed under the Creative Commons Attribution International License (CC BY 4.0). <http://creativecommons.org/licenses/by/4.0/>



Open Access

Abstract

In this report, we discuss the case of a 55-year-old male, who presented to Accident & Emergency with worsening shortness of breath. This gentleman is a known case of Chronic Obstructive Pulmonary Disease (COPD) and is a regular cocaine and heroin user. During the admission, he was noted to have persistent hypoxia despite being managed as a COPD exacerbation. His chest x-ray was normal, and further investigation with CT pulmonary angiography identified a left sided 12 mm × 9 mm × 12 mm dense area at the level of bifurcation of the left main bronchus, suspicious of a foreign body aspiration. Flexible bronchoscopy revealed a cocaine packet made of aluminium foil and his symptoms resolved upon removal. To our knowledge this is one of the few encountered cases where aspiration of cocaine packets has occurred. This case highlights the need for a high index of suspicion in patients with a history of substance use who present with acute respiratory symptoms.

Keywords

Cocaine, Foreign Body Aspiration, Flexible Bronchoscopy

1. Introduction

Cocaine abuse is associated with a wide spectrum of pulmonary complications, ranging from acute bronchospasm to diffuse alveolar haemorrhage and non-cardiogenic pulmonary oedema. While these systemic and inhalational effects are well-documented, the direct endobronchial aspiration of cocaine remains an exceedingly rare clinical entity.

Such cases present unique diagnostic and therapeutic challenges, as they mimic other forms of airway obstruction or acute pneumonitis. We report a rare instance of cocaine aspiration and describe its successful management through flexible bronchoscopy, highlighting the importance of early endoscopic inter-

vention.

2. Case Summary

We present the case of Mr. Y, a 55-year-old male and active smoker with a 40 pack-year history. He is a regular heroin and cocaine user who presented to the emergency department with a one-day history of worsening shortness of breath. The patient stated that the dyspnoea occurred shortly after smoking heroin. He has a known history of chronic obstructive pulmonary disease (COPD) but has been non-adherent to his prescribed inhalers. This has resulted in a longstanding history of productive cough spanning several years, which was unchanged in volume and character on presentation. He denied other symptoms, such as weight loss, fever, or haemoptysis.

On examination, the patient was noted to have a diffuse wheeze with sparse crackles. Vital signs showed an SpO₂ of 93% on room air, a respiratory rate of 33 breaths per minute, and a low-grade fever of 37.4°C.

Arterial blood gases (ABGs) obtained on room air demonstrated mild type 1 respiratory failure (pH: 7.38, pCO₂: 44.9 mmHg, pO₂: 66.7 mmHg).

3. Investigations

Upon admission to the Emergency Department, laboratory investigations revealed leucocytosis ($19 \times 10^9/L$; Range: $4.3 - 11.4 \times 10^9/L$) with an elevated C reactive protein at 171 mg/L (Range: <5 mg/L). Chest X-ray was also done which was unremarkable.

Despite four days of antibiotic therapy, the patient remained persistently hypoxic. Consequently, a D-dimer was obtained, which was mildly elevated at 588 ng/mL (Range: <500 ng/mL). To rule out pulmonary embolism, a CT pulmonary angiogram (CTPA) was performed; this identified a $12 \times 9 \times 12$ mm dense area at

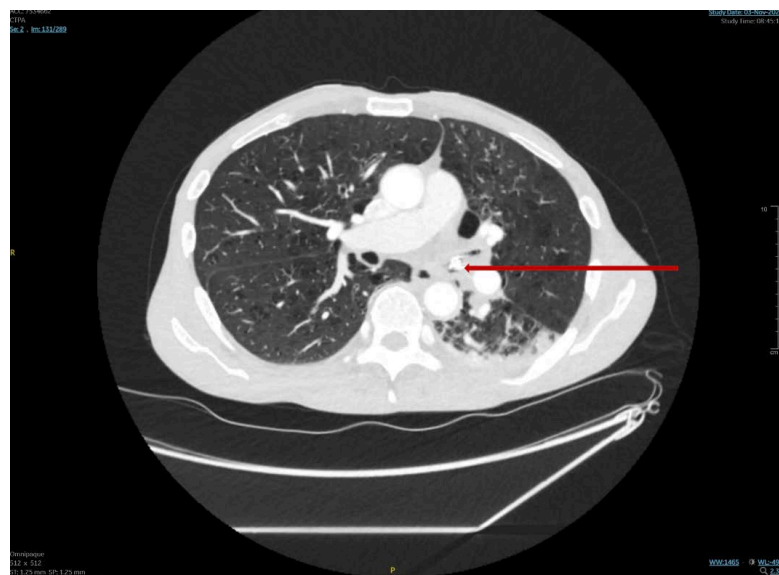


Figure 1. CT-PA showing foreign body in the left main bronchus.

the level of the bifurcation of the left main bronchus suspicious of a foreign body (**Figure 1**).

Sputum samples taken during admission subsequently grew *Pseudomonas aeruginosa* and *Klebsiella pneumoniae*, both of which were sensitive to the initiated antibiotic regime.

4. Differential Diagnosis

At the Emergency department the initial differential diagnosis was of an infective exacerbation of COPD. This was supported by elevated inflammatory markers (elevated leucocytosis and CRP), acute onset shortness of breath and audible wheeze.

However, the diagnosis was reassessed when the patient failed to improve clinically despite standard treatment. Computed tomography (CT) subsequently identified a foreign body, confirming the need for a different approach. The patient later admitted to aspirating a heroin/cocaine packet wrapped in aluminium foil, and urgent plans for its removal were initiated.

5. Treatment and Outcome

The patient was initially treated with intravenous co-amoxiclav and clarithromycin, alongside nebulized salbutamol and ipratropium bromide, targeting a presumed infective exacerbation of COPD. Regular chest physiotherapy was also initiated to facilitate airway clearance.

Due to minimal clinical improvement and the subsequent identification of a bronchial foreign body, an urgent bronchoscopy was scheduled. Following informed consent, the patient was sedated with propofol under the supervision of a senior anaesthetist. Respiratory support was maintained via high-flow nasal cannulation (HFNC). Given the risk of acute toxicity should the packet rupture during retrieval, the Intensive Therapy Unit (ITU) was placed on standby.

A flexible bronchoscope was introduced orally and advanced to the left main bronchus. Upon visualization of the foreign body (**Figure 2**), biopsy forceps were used to carefully grasp and dislodge the aluminium foil package.

Once the package was successfully dislodged from the airway, the bronchoscope and forceps were withdrawn en bloc, allowing complete retrieval of the foreign body (**Figure 3, Figure 4**).

Upon successful retrieval, the patient was transitioned to a monitored setting for 24 hours of telemetry and hemodynamic surveillance for potential delayed cocaine toxicity. Regular ECGs were also performed to ensure close surveillance. Respiratory recovery was prompt, with the patient returning to ambient air on day one and maintaining oxygen saturations above 98%. Subsequent management included chest physiotherapy to mobilize retained secretions distal to the site of obstruction and antibiotic therapy for bacterial clearance.

At the two-week outpatient follow-up, the patient remained clinically stable with no delayed sequelae from potential drug exposure and no recurrence of dyspnoea.

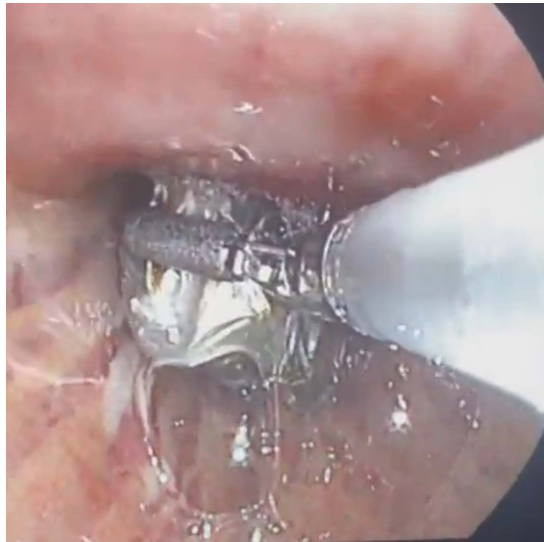

Figure 2. Biopsy forceps attempting to dislodge foreign body.

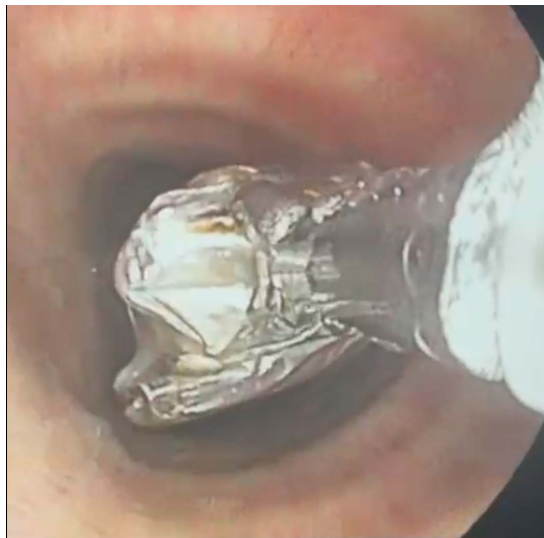

Figure 3. Withdrawal of bronchoscope together with foreign body.



Figure 4. Package following retrieval.

6. Discussion

Foreign body aspiration (FBA) in adults is an uncommon but well-recognized clinical entity and is frequently underdiagnosed due to its nonspecific presentation. Unlike in children, adult cases often lack a clear choking episode and may present with chronic or subacute respiratory symptoms such as cough, wheeze, dyspnoea, or recurrent respiratory infections [1] [2]. This can lead to diagnostic delay, particularly in patients with significant smoking histories, in whom symptoms are often attributed to chronic obstructive pulmonary disease or malignancy [3].

In this case, the patient's six-month history of productive cough with acute worsening of dyspnoea occurred in the context of a 40 pack-year smoking history, making alternative diagnoses such as infection, pulmonary embolism, or lung cancer more likely considerations. The absence of abnormalities on chest radiography is consistent with previous reports, as plain radiographs may be normal in up to 25% - 30% of adult FBA cases, particularly when the foreign body is radio-lucent or causes partial airway obstruction [1] [2]. This highlights the limited sensitivity of chest radiography in excluding endobronchial pathology.

CT pulmonary angiography proved pivotal in this case. Computed tomography has superior sensitivity compared to chest radiography for detecting endobronchial foreign bodies and associated secondary findings such as focal airway obstruction, air trapping, atelectasis, or post-obstructive infection [2] [4]. Endobronchial foreign bodies may also mimic neoplastic lesions on CT imaging, particularly when centrally located or surrounded by granulation tissue, reinforcing the importance of bronchoscopic evaluation when imaging findings are indeterminate [1] [3].

Flexible bronchoscopy remains both a diagnostic and therapeutic modality in adult FBA and is often successful in removal, particularly for small or distally located objects [4] [5]. In this patient, bronchoscopy revealed a foil-wrapped packet of cocaine lodged at the bifurcation of the left main bronchus. Aspiration of illicit drug packets is rare and is more commonly described within the gastrointestinal tract in the context of concealment ("body packing" or "body stuffing"). Aspiration into the tracheobronchial tree is exceedingly uncommon, with only isolated case reports described in the literature [5] [6]. The foil wrapping likely contributed to the radiodensity observed on CT imaging and may have reduced drug leakage, potentially preventing acute systemic toxicity.

Foreign bodies aspirated into the tracheobronchial tree are more commonly found in the right bronchial system due to anatomical factors, including the wider diameter, shorter length, and more vertical orientation of the right main bronchus compared with the left [1] [2]. Consequently, right-sided foreign body aspiration is reported in the majority of adult cases. However, left-sided aspiration, as demonstrated in this case, is well described and may occur depending on patient positioning at the time of aspiration, the size and shape of the foreign body, air-flow dynamics, or transient alterations in bronchial anatomy during respiration

or coughing [2].

The foreign body in this patient was lodged at the bifurcation of the left main bronchus, an atypical but clinically significant location. This may have contributed to the subtle and chronic nature of symptoms by allowing partial airflow around the obstruction, thereby delaying clinical suspicion and diagnosis. This case highlights that although right-sided involvement is more common, clinicians should maintain a high index of suspicion for foreign body aspiration in either bronchial tree, particularly when imaging reveals focal endobronchial abnormalities and clinical features remain unexplained [2] [4].

This case highlights several important learning points. Foreign body aspiration should remain a differential diagnosis in adults with unexplained or persistent respiratory symptoms, even in the absence of a witnessed aspiration event. Normal chest radiography does not exclude clinically significant airway obstruction. CT imaging, often performed for alternative indications, may reveal unexpected but clinically significant endobronchial findings, and bronchoscopy should be pursued promptly to confirm diagnosis and facilitate management, thereby preventing long-term complications such as recurrent infection, bronchiectasis, or airway stenosis [1] [4].

7. Conclusion

This case highlights the diagnostic challenges of foreign body aspiration in adults, particularly in the absence of a clear aspiration history and with normal chest radiography. It underscores the importance of maintaining clinical suspicion in patients with persistent or unexplained respiratory symptoms, even when alternative diagnoses appear more likely. The atypical left-sided location and unusual nature of the foreign body further emphasize that airway pathology may be overlooked without cross-sectional imaging and bronchoscopic evaluation, both of which remain essential for accurate diagnosis and definitive management.

Conflicts of Interest

The authors declare no conflicts of interest regarding the publication of this paper.

References

- [1] Bajaj, D., Agrawal, A., Gupta, S., *et al.* (2021) Foreign Body Aspiration. *Journal of Thoracic Disease*, **13**, 5159-5175. <https://doi.org/10.21037/jtd.2020.03.94>
- [2] Hong, P.Y., Zhang, X.Y., Li, J., *et al.* (2024) Clinical Characteristics and Removal Approaches of Tracheal and Bronchial Foreign Bodies in Elderly Adults. *Scientific Reports*, **14**, 60307. <https://doi.org/10.1038/s41598-024-60307-z>
- [3] Georgakopoulou, V.E., Koulouris, C., Damaskos, C., *et al.* (2024) Foreign Body in the Tracheobronchial Tree as a Cause of Hemoptysis in an Adult without Risk Factors for Aspiration: A Case Report. *Cureus*, **16**, e38707. <https://doi.org/10.7759/cureus.57596>
- [4] Goyal, R., Sehgal, I.S. and Agarwal, R. (2025) Foreign Body Removal. *Current Opinion in Pulmonary Medicine*, **32**, 63-73.

- [5] Al Bshabshe, A. and Al Qout, M. (2025) Fiber-Optic Bronchoscopy for the Removal of an Impacted Foreign Body in the Left Mainstem Bronchus: A Case Report with Review of Literature. *Journal of Surgical Case Reports*, **2025**, rjaf254. <https://doi.org/10.1093/jscr/rjaf254>
- [6] Sarubbi, D., *et al.* (2024) I-gel® as Airway Management in a Challenging Adult Tracheobronchial Foreign Body Aspiration. *Indian Journal of Thoracic and Cardiovascular Surgery*, **40**, 473-475. <https://doi.org/10.1007/s12055-023-01676-4>