

# Pancreatic Adenocarcinoma and Brain Mets: Literature Review

Sakshi Bai<sup>1</sup>, Jahnvi Ethakota<sup>1</sup>, Fnu Payal<sup>2</sup>, Oboseh John Ogedegebe<sup>3</sup>, Akshay Kumar<sup>4</sup>,  
Olanipekun Lanny Ntukidem<sup>3</sup>, Fnu Sagar<sup>5</sup>, Bipneet Singh<sup>1</sup>, Akhil Rahman<sup>1</sup>

<sup>1</sup>Henry Ford Jackson Hospital, Jackson, USA

<sup>2</sup>Monmouth Medical Center, Long Branch, USA

<sup>3</sup>Trinity Health Ann Arbor, Ypsilanti, USA

<sup>4</sup>Jersey City Medical Center, New Jersey, USA

<sup>5</sup>Jinnah Sindh Medical University, Karachi, Pakistan

Email: sakshibai1997@gmail.com

**How to cite this paper:** Bai, S., Ethakota, J., Payal, F., Ogedegebe, O.J., Kumar, A., Ntukidem, O.L., Sagar, F., Singh, B. and Rahman, A. (2025) Pancreatic Adenocarcinoma and Brain Mets: Literature Review. *Case Reports in Clinical Medicine*, **14**, 290-302.  
<https://doi.org/10.4236/crcm.2025.146039>

**Received:** April 14, 2025

**Accepted:** June 23, 2025

**Published:** June 26, 2025

Copyright © 2025 by author(s) and  
Scientific Research Publishing Inc.

This work is licensed under the Creative  
Commons Attribution International  
License (CC BY 4.0).

<http://creativecommons.org/licenses/by/4.0/>



Open Access

## Abstract

Brain metastases from pancreatic ductal adenocarcinoma (PDAC) are extremely rare (incidence < 1%) but have serious clinical implications and a dismal prognosis. We present two cases of PDAC with brain metastases and review the literature. The first case was a 62-year-old woman who presented with aphasia and was found to have an ischemic stroke plus a ring-enhancing brain lesion; imaging and biopsy confirmed metastatic PDAC with pancreatic, liver, and brain involvement, and she was managed with corticosteroids and palliative cranial radiotherapy. The second patient was a 60-year-old woman who presented with confusion and a hemorrhagic brain mass; the workup revealed a pancreatic head carcinoma with widespread metastases. Her condition deteriorated rapidly and she died shortly after diagnosis, reflecting the aggressive course of PDAC once the central nervous system was involved. Reported clinical presentations of PDAC brain metastases range from incidental findings to severe neurological deficits (commonly headaches, seizures, focal deficits, or altered mental status). Diagnosis relies on brain MRI and confirmatory pathology when needed, especially if the pancreatic primary is not yet identified. There are no standardized treatment guidelines—management is individualized and multidisciplinary, often combining surgical resection of isolated lesions, radiotherapy (stereotactic or whole-brain), and systemic therapy, along with supportive care (e.g., corticosteroids for edema). Prognosis remains poor: median survival after a PDAC brain metastasis diagnosis is only ~2 - 5 months, and very few patients survive beyond one year. Molecular profiling indicates that PDAC tumors causing brain metastases to harbor common mutations (e.g., KRAS, TP53) like typical PDAC, while rarely actionable alterations (such as ALK or NTRK fu-

---

sions or BRAF mutations) have enabled targeted therapies with CNS activity in select cases. Emerging treatments, including novel KRAS inhibitors and other targeted agents, are under investigation and offer hope for improved systemic and intracranial disease control.

## Keywords

Adenocarcinoma, Pancreas, Brain Mets, Prognosis, Stroke Like Presentation

---

## 1. Introduction

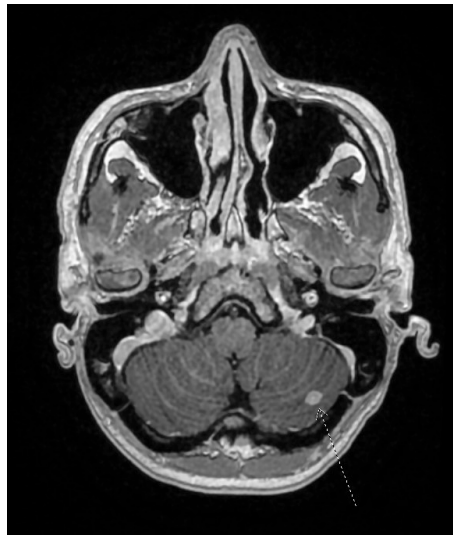
Pancreatic ductal adenocarcinoma (PDAC) is among the most lethal malignancies, with a five-year survival rate below 5% for metastatic disease. It typically metastasizes to the liver, lungs, and lymph nodes. Brain metastases have been considered exceedingly rare, with reported incidences around 0.2% - 0.6% [1]. This rarity has historically been attributed to the short survival time of PDAC patients. However, the use of combination chemotherapies such as FOLFIRINOX and gemcitabine + nab-paclitaxel has modestly extended survival, leading to increased detection of central nervous system (CNS) metastases [2].

The growing number of reported cases highlights the need to better understand this rare presentation. Brain metastases from PDAC often occur late in the disease course and significantly impact clinical management. This paper presents two such cases, followed by a detailed review of the literature on the epidemiology, diagnosis, treatment, and future directions for managing PDAC with CNS involvement.

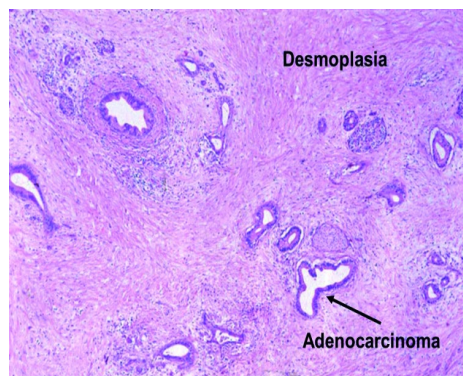
## 2. Case Presentations

**Case 1:** A 62-year-old female with no significant medical history presented with acute-onset word-finding difficulty. Her symptoms began five days prior with watery diarrhea and abdominal cramps, followed by progressive fatigue. On the day of admission, she developed expressive aphasia prompting evaluation. Brain MRI confirmed an acute ischemic stroke and a well-defined ring-enhancing lesion in the brain (Figure 1). A transthoracic echocardiogram revealed a large patent foramen ovale (PFO), and Doppler ultrasound showed a deep vein thrombosis (DVT), raising concern for paradoxical embolism as the stroke mechanism. During hospitalization, the patient reported abdominal pain, leading to further imaging. Abdominal CT revealed a pancreatic mass with liver lesions, which MRI confirmed as liver metastases. Endoscopic ultrasound-guided biopsy of the pancreatic lesion showed pancreatic adenocarcinoma, confirming the primary cancer. She was referred to oncology for further management (systemic therapy). Neurologically, her stroke deficits were managed supportively. Given her disseminated disease and stroke, the brain lesion was presumed metastatic and managed non-surgically with corticosteroids for edema and plans for palliative radiotherapy. Histopathology confirmed the diagnosis of adenocarcinoma (Figure 2).

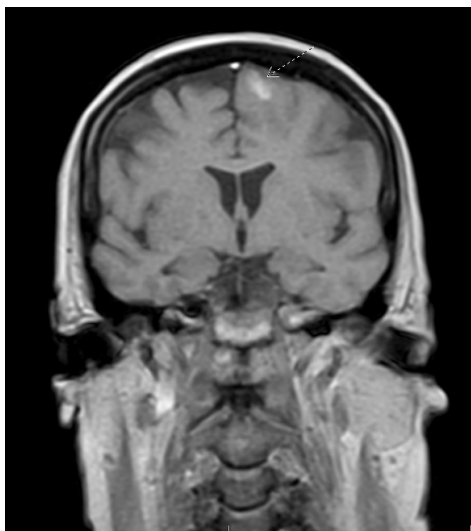
**Case 2:** A 60-year-old female (history of type 2 diabetes, anemia, and obesity) presented with acute confusion, mumbling speech, and visual hallucinations. The family reported a week of unsteady gait and a few days of worsening diarrhea prior to admission. She endorsed intermittent night sweats and unintentional weight loss (~60 pounds over one year). Workup revealed an intracerebral hemorrhagic mass with surrounding edema on head CT, and brain MRI showed a lesion suspicious for metastasis with hemorrhage (**Figure 3**). She started high-dose steroids for edema control. Concurrently, imaging uncovered a pancreatic head mass. Endoscopic retrograde cholangiopancreatography (ERCP) with biopsy yielded a preliminary diagnosis of pancreatic adenocarcinoma. CT scans also showed innumerable bilateral pulmonary nodules concerning metastatic disease. Unfortunately, shortly after diagnosis the patient's clinical status deteriorated. Given the extensive systemic disease burden and poor performance status, only supportive care was pursued. She died shortly thereafter, illustrating the aggressive course of PDAC once CNS involvement occurs.



**Figure 1.** Left frontal lobe 7 mm × 9 mm × 8 mm enhancing lesion consistent with hemorrhagic metastasis. There is also surrounding mild edema.



**Figure 2.** Invasive, disorganized glandular and ductal structures embedded in a prominent desmoplastic stroma.



**Figure 3.** Left frontal metastatic lesion with increase in size, surrounding edema and enhancement of adjacent cerebral convexity and gyral leptomeningeal enhancement.

These cases reflect the diverse clinical manifestations, diagnostic challenges, and poor outcomes associated with PDAC with brain metastases. In the following sections, we expand on the epidemiology, diagnosis, management, and prognosis of this uncommon clinical entity, incorporating recent literature and studies up to 2025.

### 3. Discussion

Brain metastases from PDAC are exceptionally rare. Large database studies indicate that less than 1% of pancreatic cancer patients will develop brain metastasis [3]. An analysis of the SEER registry found an incidence of approximately 0.6% among over 13,000 stage IV PDAC patients. Single-institution series have reported similar frequencies—for example, a 2024 analysis from a cancer center identified 19 patients with PDAC brain metastases out of ~6000 PDAC cases (0.3%) [4]. Autopsy studies also support the rarity; one review noted only about 0.33% of pancreatic cancers had brain involvement on post-mortem examination [5]. By comparison, brain metastases are much more common in other solid tumors like lung cancer, breast cancer, or melanoma.

Notably, the incidence of PDAC brain metastases appears to be rising as overall survival improves. Improved combination chemotherapies (e.g., FOLFIRINOX, gemcitabine + nab-paclitaxel) have extended median survival in metastatic PDAC by a few months, allowing some patients to live long enough for CNS metastases to emerge. Indeed, a recent case series in 2023 emphasized that with better systemic control, the incidence of brain metastasis may increase, and clinicians should remain vigilant [2] [3] [6]. Patients who develop brain metastases tend to be those with relatively prolonged disease courses. In a 2025 study of 44 PDAC patients with brain metastasis, the median time from initial PDAC diagnosis to brain metastasis detection was about 24 months significantly longer than the typical sur-

vival of PDAC with only visceral metastases [4]. This suggests that brain metastasis in PDAC often represents a late complication in patients with initially better response or slower tumor biology.

There are no clear demographic predispositions, but some series note that patients with PDAC brain metastases may be younger on average (often in their 50s - 60s) and more likely to have lung metastases as a part of their disease spectrum [4] [5]. Lung metastases were present in 58% - 71% of patients who eventually developed brain metastases in two cohorts, suggesting a possible pattern of spread (hematogenous dissemination to lungs followed by seeding to the brain). Still, given the overall rarity, definitive risk factors for brain metastasis in PDAC are not well established [4] [7].

Patients with PDAC-derived brain metastases can present with a range of neurologic symptoms or occasionally have no symptoms at all. The most common presentations include headaches, seizures, focal neurological deficits (such as muscle weakness or speech difficulties), dizziness, or altered mental status. Seizures and aphasia were observed in the above case vignettes, reflecting how metastatic lesions can provoke cortical irritation or impair language centers. Raised intracranial pressure from edema or hydrocephalus (if metastases obstruct CSF pathways) can lead to headaches, nausea/vomiting, or papilledema. In some patients, personality changes or cognitive decline may be noted if frontal lobes are involved.

A subset of cases is incidentally discovered. For instance, asymptomatic metastases might be found on surveillance imaging or during workup for something else. But more often, the onset of new neurologic symptoms in a pancreatic cancer patient prompts an evaluation for brain lesions. Rarely, brain metastasis may be the first manifestation of pancreatic cancer before the primary tumor is diagnosed [8]. This scenario is uncommon because PDAC typically causes abdominal symptoms or metastasizes to more common sites earlier; however, it has been reported and poses a diagnostic challenge if the patient presents with an isolated brain lesion and no known cancer history.

Given PDAC's propensity to cause a hypercoagulable state (Trousseau's syndrome), stroke can be part of the differential diagnosis when neurologic symptoms arise. In fact, Case 1 above initially presented with an ischemic stroke. Clinicians must maintain a high index of suspicion for concurrent metastasis in a cancer patient with neurological signs—in that case, neuroimaging revealed a metastatic lesion alongside the stroke. In general, any PDAC patient with new focal neurological symptoms or unexplained altered mental status should undergo prompt brain imaging to evaluate for metastasis or other intracranial pathology.

#### 4. Diagnostic Strategies

**Imaging:** Magnetic resonance imaging (MRI) with gadolinium contrast is the preferred modality for detecting brain metastases. Metastatic lesions typically appear as round or ring-enhancing masses with vasogenic edema. On MRI, pancreatic cancer metastases can sometimes show ring enhancement and central necrosis (like

other adenocarcinoma metastases) [8]. Multiple lesions are common, though solitary metastasis can occur. In cases of hemorrhagic presentation (like Case 2), metastasis may appear as an intra-parenchymal bleed on CT; MRI can then identify the tumor underlying the hemorrhage. **Figure 1** illustrates an example of PDAC brain metastases on MRI, demonstrating irregular ring enhancement and surrounding edema on T1 post-contrast images. Radiographically, these lesions must be differentiated from primary brain tumors (e.g., high-grade gliomas) or other metastatic cancers; clinical context is crucial, as is histological confirmation if there's any doubt.

**Confirmation and Work-Up:** If a brain lesion is found in a patient with known pancreatic cancer, it is usually presumed metastatic. However, in patients without a known primary, further work-up is needed. A whole-body CT or PET-CT can search for a primary tumor in the pancreas or other sites [8]. Biopsy of the brain lesion or surgical resection for pathology can confirm the diagnosis. Histologically, metastatic PDAC in the brain appears as adenocarcinoma like the primary tumor. Immunohistochemical staining can help pinpoint the origin (for example, PDAC metastases are typically positive for CK7 and CA19-9, and negative for TTF-1 or GCDFP-15, helping distinguish from lung or breast primary). In practice, if the patient already carries a PDAC diagnosis, tissue confirmation of a suspected brain metastasis is often not pursued unless atypical features are present. Lumbar puncture may be considered if leptomeningeal metastasis is suspected (e.g., cranial neuropathies or multiple enhancing nodules in meninges on MRI).

**Screening:** Routine screening brain MRI for all PDAC patients is not recommended given the low yield. Diagnostic imaging is driven by symptoms. Nonetheless, clinicians should be aware that prolonged survival in PDAC (especially with lung metastases or controlled systemic disease) raises the possibility of CNS spread. Early MRI at the onset of neurologic symptoms can lead to timely intervention.

## 5. Treatment Approaches

There are no standardized treatment protocols for PDAC brain metastases due to their rarity; management is usually individualized and extrapolated from approaches in other cancers. A multidisciplinary strategy involving oncologists, neurosurgeons, and radiation specialists is recommended. Key treatment modalities include surgical resection, radiotherapy, and systemic therapy, often used in combination when appropriate. Supportive care measures are also essential. Below, we outline these approaches:

- **Surgical Resection:** For patients with a limited number of accessible brain metastases and good performance status, surgical resection can be beneficial. Metastasectomy provides immediate cytoreduction and tissue for diagnosis. In PDAC, surgery is usually considered if there is a single (or few) metastasis and controlled extracranial disease. Even though long-term control is rare, case series suggest surgery can prolong survival and improve neurological function

in selecting patients. A pooled analysis identified neurosurgical intervention as a positive prognostic factor, recommending it be pursued when feasible. Outcomes from a recent cohort showed that patients who underwent brain metastasectomy had a median overall survival of ~8 - 9 months after brain metastasis, significantly longer than those managed with radiotherapy alone [4]. Thus, surgery offers the best chance of meaningful extension of survival when applicable.

- **Radiotherapy:** Radiation is a mainstay for brain metastases, especially when lesions are multiple or unresectable. Two principal options are whole-brain radiotherapy (WBRT) and stereotactic radiosurgery (SRS). WBRT treats the entire brain and is useful for widespread metastases or prophylaxis but carries risks of neurocognitive side effects. SRS (e.g., Gamma Knife or LINAC-based) delivers high-dose focal radiation to the metastasis with minimal normal tissue exposure, suitable for up to several lesions. In reported PDAC cases, SRS has been used after resection (to sterilize the cavity) or as primary treatment for small metastases. For example, Law and Lomma (2023) described patients treated with combinations of surgery and SRS for limited brain mets [3]. Radiotherapy can palliate symptoms and is associated with improved survival compared to no CNS-directed therapy. In the aforementioned cohort, patients receiving SRS (without surgery) had a post-BM median survival of around 3.3 months, and those receiving WBRT alone about 2.8 months—indicating radiation has benefit, though not as much as surgery in appropriate cases. Generally, SRS is favored for 1 - 3 metastases <3 - 4 cm size, while WBRT is reserved for numerous lesions or leptomeningeal disease.
- **Systemic Therapy:** Treating PDAC systemically in the setting of brain metastasis is challenging due to the blood-brain barrier (BBB). Most conventional chemotherapies (e.g., gemcitabine) have poor CNS penetration. Nonetheless, continuing an active chemotherapy regimen can help control extracranial disease and potentially slow CNS progression if the drugs have some BBB permeability. Some fluoropyrimidine-based regimens (like FOLFIRINOX, which includes 5-FU) may have slight activity in the brain, and newer agents or targeted therapies (discussed below) might cross the BBB. In practice, if a patient with PDAC brain metastases is otherwise fit, oncologists often continue or modify chemotherapy based on prior responses. There is no dedicated clinical trial data for PDAC brain metastases, so decisions are case-by-case. It's reasonable to treat systemic disease per standard PDAC protocols, especially if the patient had a good response to a regimen before CNS involvement. Importantly, patients with known CNS disease should be monitored for CNS-specific response, as systemic therapy alone is rarely sufficient for active brain metastases.
- **Supportive Care:** Given the poor prognosis, supportive measures are crucial for quality of life. Corticosteroids (e.g., dexamethasone) are commonly used to reduce peritumoral brain edema and alleviate symptoms like headache or focal deficits. Anti-epileptic drugs are indicated if seizures have occurred (seizure

prophylaxis may be considered in those with cortical lesions). Careful attention to neurologic status, physical therapy for any deficits, and counseling are needed. In patients with widespread disease and limited expected survival, palliative care involvement is appropriate to manage pain and symptoms and to guide end-of-life care. In the present cases, for example, aggressive interventions were forgone in favor of comfort measures due to the overall disease burden and condition of the patients.

Because there are no guidelines specific to PDAC brain metastases, clinicians often follow principles used for brain mets from other primaries (like lung cancer): localized therapy for local control when possible, systemic therapy for overall disease control, and palliative care integration early for symptomatic relief. Each patient's plan should be individualized, weighing factors such as number of lesions, symptoms, performance status, extent of systemic disease, and molecular tumor characteristics.

## 6. Prognosis

The prognosis for PDAC patients who develop brain metastases remains dismal. Median survival after diagnosis of brain metastasis is typically only on the order of a few months. Several literature reviews and series converge on a post-brain metastasis median overall survival of around 2 - 5 months. A Surveillance, Epidemiology, and End Results (SEER) analysis of 508 PDAC patients with brain metastases reported a median survival of approximately 2 months. Similarly, Gouton *et al.* (2024) found a median of 2.9 months after brain metastasis in a pooled analysis. In our institution's two cases, survival after CNS involvement was very short (weeks to a few months), reflecting these grim statistics. Without treatment, survival is at the lower end of this range, often under 2 months due to rapid neurological decline.

Nevertheless, there is a spectrum of outcomes, and a few patients achieve longer survival. In rare instances, patients have survived 12 months or more after aggressive management of brain metastases. Factors associated with better or worse prognosis are beginning to be understood. Adverse prognostic factors include older age (>65 years) and the presence of active, uncontrolled systemic metastases (especially liver metastases). These factors likely reflect overall tumor aggressiveness and patient resilience. Conversely, patients who are younger, have a single brain lesion, and have otherwise controlled disease (or favorable tumor biology) tended to survive longer. For example, patients with isolated brain metastasis that can be resected and who have no progression elsewhere may achieve survival on the order of several extra months and occasional reports of beyond a year. In one review, long-term survival was seen in a patient whose primary tumor was well-treated. Treatment interventions can modestly improve survival outcomes compared to supportive care alone. Multivariate analyses indicate that receipt of chemotherapy, radiation, or surgery is associated with prolonged survival relative to doing nothing. Among these, surgical resection of brain metastases appears to confer the

greatest benefit in selected patients, as noted earlier (median ~8 - 9 months vs ~3 months with radiation only) [4]. Patients who only receive palliative measures typically succumb quickly due to neurologic deterioration or systemic progression. Leptomeningeal metastasis portends an especially poor outcome; in the MD Anderson series, patients with leptomeningeal spread had among the worst survivals, often just 1 - 2 months [9].

Overall, however, even with maximal therapy, the prognosis is poor. Most patients with PDAC brain metastases will die from their disease within a year of CNS involvement, with many not surviving beyond 6 months. This underscores the aggressive nature of pancreatic cancer even when metastases are treated. It also highlights the need for novel therapies that could better control both systemic and CNS diseases.

## 7. Molecular Markers and Emerging Treatments

**Molecular Profile of PDAC:** Molecular characterization of pancreatic adenocarcinoma has revealed key driver genes and potential therapeutic targets. KRAS mutation is the hallmark of PDAC—over 90% of cases harbor activating mutations in KRAS [4]. The vast majority of these are at codon 12 (commonly KRAS<sup>G12D</sup>, G12V, G12R); KRAS<sup>G12C</sup>, which is targetable in other cancers, is present in only ~1% - 2% of PDAC [4]. Other common mutations in PDAC include tumor suppressors: TP53 (mutated in ~50% - 75% of cases), CDKN2A/p16 (about 50%), and SMAD4 (about 30% - 50%) [7]. These four genes (KRAS, TP53, CDKN2A, SMAD4) represent the core genomic alterations in most pancreatic cancers.

Brain metastases from PDAC appear to arise from tumors with similar molecular profiles as typical PDAC. In the largest genomic analysis of PDAC brain metastases to date (44 patients, MD Anderson 2025), KRAS was mutated in 94% of tested cases, TP53 in 71%, and CDKN2A in 18% [4]. This aligns with known frequencies. Notably, all three patients with **BRCA1/2** mutations in that cohort had developed brain metastases, and these were germline mutations. Some studies suggest germline BRCA, and other DNA repair mutations may be overrepresented in PDAC patients with atypically long survival or unusual metastatic patterns (like CNS spread). It's hypothesized that this association might be due to the better chemotherapy responsiveness (to platinum agents) in BRCA-mutated PDAC, allowing patients to live long enough to manifest brain metastases. However, more data is needed to confirm if BRCA or other mutations truly predispose to brain metastatic behavior, or if they simply extend survival.

Importantly, a small subset of PDAC tumors lack KRAS mutations—these are the cases where *actionable* oncogenic drivers are sometimes found. KRAS-wildtype PDAC (perhaps ~5% - 10% of cases) may harbor alterations such as ALK, NTRK, ROS1, RET, or BRAF gene fusions/mutations [10]. Identification of these is critical because they open the door to targeted therapies. For instance, a recent case report described a young patient with ALK-rearranged, KRAS-wildtype pancreatic cancer who had a remarkable response to the ALK inhibitor crizotinib, and upon

developing brain metastases, was effectively treated with alectinib (a CNS-penetrant ALK inhibitor) [7]. This patient achieved an unusually prolonged survival, illustrating the value of comprehensive molecular testing and targeted therapy in select PDAC cases. Similarly, NTRK gene fusions, though rare in PDAC, are treatable with TRK inhibitors (larotrectinib or entrectinib) which have CNS activity. BRAF V600E mutations (~1% of PDAC) can be treated with BRAF/MEK inhibitors, and ROS1 fusions with ROS1 inhibitors, potentially benefiting brain lesions given some of these drugs cross the BBB.

**Emerging Targeted Therapies:** Historically, KRAS was considered “undruggable,” but that paradigm is changing. KRAS<sup>G12C</sup>-specific inhibitors (sotorasib, adagrasib) have shown some efficacy in KRAS<sup>G12C</sup>-mutant PDAC, although this mutation is very uncommon in pancreas cancer [11]. More relevant, new agents targeting the more prevalent KRAS mutations are in development. A novel KRAS<sup>G12D</sup> inhibitor, MRTX1133, has demonstrated promising preclinical results and is being evaluated in clinical trials. Additionally, a “pan-KRAS” inhibitor RMC-6236 is in trials aiming to target multiple KRAS mutation variants [12]. If these agents prove effective, they could significantly impact PDAC treatment, especially if they have activity against brain metastatic disease. One consideration will be achieving sufficient drug penetration into the CNS; the blood-brain barrier may limit some large or hydrophilic molecules. However, designing KRAS inhibitors that cross the BBB or using them in conjunction with techniques to improve CNS delivery could benefit patients with brain mets in the future [4].

Beyond RAS, other targeted therapy avenues include inhibitors of downstream signaling pathways (MEK, ERK inhibitors) and stroma-targeting agents. While MEK inhibitors alone have had limited success in PDAC, combinations are being tested. Antiangiogenic agents have not shown much benefit in PDAC, likely due to the unique dense stroma and low vascularity of these tumors. Efforts to disrupt the desmoplastic stroma (for example, hyaluronidase PEGPH20 in trials) aimed to improve drug delivery, though results have been mixed.

For patients with **DNA damage repair** mutations like *BRCA1/2* or *PALB2*, **PARP inhibitors** have emerged as an important therapy. The PARP inhibitor olaparib is approved as maintenance therapy in metastatic PDAC with germline BRCA mutation after platinum-based induction, based on the POLO trial. PARP inhibitors are oral agents that could potentially help control micrometastatic disease in the CNS if they cross the BBB. While olaparib has limited CNS penetration, other PARP inhibitors (e.g., niraparib, talazoparib) have some brain penetration and are being explored. The concept of a “brain-penetrant PARP inhibitor” is especially relevant for BRCA-mutant PDAC patients who develop brain mets [4]. If CNS-active PARP inhibitors were available, they might improve outcomes for this subset by treating both systemic and intracranial disease. Ongoing research is needed in this area.

**Immunotherapy:** PDAC has long been considered a poorly immunogenic tumor (“cold” tumor). Checkpoint inhibitors like pembrolizumab have shown ben-

efit only in rare PDAC cases with high microsatellite instability (MSI-H) or mismatch-repair deficiency (~1% of patients). For the vast majority of PDAC (MSI-stable), single-agent immunotherapy has not been effective [7]. Emerging approaches aim to overcome the immunosuppressive tumor microenvironment of PDAC. These include agonistic CD40 antibodies (to activate antigen-presenting cells), which in combination with chemotherapy have shown some promise in early studies, and trials of CAR T-cell therapy targeting antigens like mesothelin. Vaccines (e.g., GVAX, algenpantucel-L) and Listeria-based immunotherapy have also been tested to stimulate immune responses against PDAC. Thus far, these immune therapies have yielded only incremental benefits, but research is ongoing. In the context of brain metastases, immunotherapy could be double-edged—for example, checkpoint inhibitors can cause inflammation that might worsen edema in the brain, yet they could potentially control microscopic CNS disease if effective systemically. At present, no immunotherapy is specifically indicated for PDAC brain metastases, but patients with MSI-H tumors should receive checkpoint blockade given the dramatic responses seen in that subgroup.

**Other Novel Approaches:** A few additional treatments under investigation deserve mention. *Tumor Treating Fields* (TTF), which are alternating electric fields delivered non-invasively to disrupt cancer cell division, have been approved for glioblastoma and are being studied in other cancers including pancreatic cancer; their role in metastatic disease is not defined, but conceivably TTF to the head could help with brain mets (this is speculative and unproven for PDAC) [13]. *Convection-enhanced delivery* or intra-thecal delivery of chemotherapy for leptomeningeal disease is another area of interest, though there are no established protocols for PDAC.

In summary, while current treatment for PDAC with brain metastases is largely palliative, emerging therapies targeting the molecular underpinnings of PDAC offer hope for future improvement. Comprehensive molecular profiling is recommended in advanced PDAC—including those with unusual metastatic patterns—as it may uncover actionable mutations or enrollment opportunities in clinical trials [7]. As therapies improve systemically, the incidence of CNS metastases may further rise, making it imperative to also focus on treatments that can cross the BBB or otherwise address brain involvement. The integration of targeted therapies (KRAS inhibitors, PARP inhibitors, etc.) and immunotherapies into multimodal management, alongside surgery and radiation, will hopefully yield better outcomes for this rare and challenging manifestation of pancreatic cancer.

## 8. Conclusions

Brain metastases from pancreatic adenocarcinoma, though rare, are being recognized with increasing frequency due to prolonged survival of some PDAC patients on modern therapies. Their presence portends a very poor prognosis and poses unique management challenges. Early recognition is key—clinicians should consider brain metastasis in any pancreatic cancer patient with new neurological symp-

toms. MRI of the brain is the diagnostic modality of choice. Management requires a case-by-case approach: surgical resection and/or radiosurgery can provide local control and symptom relief, and appear to extend survival in select patients, while systemic therapy should be continued or tailored based on tumor biology and prior response. Supportive care remains essential to address symptoms and maintain quality of life.

Recent literature (including retrospective analyses and case series up to 2025) provides deeper insight into this entity. The epidemiology confirms an incidence well below 1%, typically occurring late in the disease course. Outcomes remain dismal with median survival around 3 - 4 months after CNS involvement, although multimodal treatment can offer modest improvements. Molecular profiling of PDAC has unraveled common mutations (KRAS, TP53, etc.) and identified subsets with targetable aberrations. While these advances have yet to dramatically change the outlook for PDAC brain metastases, they lay the groundwork for future therapies. Agents targeting KRAS and DNA repair pathways, and novel immunotherapeutic strategies, are on the horizon and hold promises especially if they can be effective in the CNS.

In conclusion, pancreatic cancer with brain metastases represents an ominous development in an already aggressive disease. A multidisciplinary approach is required to optimize outcomes, and referral to specialized centers or clinical trials should be considered. Ongoing research into the molecular characteristics of PDAC with atypical metastases will hopefully yield new avenues for therapy. Until then, clinicians must extrapolate from available data to manage this condition, striving to balance aggressive treatment of cancer with the goals of care and comfort for the patient.

## Conflicts of Interest

The authors declare no conflicts of interest regarding the publication of this paper.

## References

- [1] Ryan, D.P., Hong, T.S. and Bardeesy, N. (2014) Pancreatic Adenocarcinoma. *New England Journal of Medicine*, **371**, 1039-1049. <https://doi.org/10.1056/nejmra1404198>
- [2] Haggstrom, L., Chan, W.Y., Nagrial, A., Chantrill, L.A., Sim, H., Yip, D., *et al.* (2024) Chemotherapy and Radiotherapy for Advanced Pancreatic Cancer. *Cochrane Database of Systematic Reviews*, No. 12, CD011044. <https://doi.org/10.1002/14651858.cd011044.pub3>
- [3] Law, N.C. and Lomma, C. (2023) Pancreatic Adenocarcinoma with Brain Metastases. *BMJ Case Reports*, **16**, e253557. <https://doi.org/10.1136/bcr-2022-253557>
- [4] Yousef, M., Hurd, M.W., Yousef, A., *et al.* (2025) Clinical and Molecular Characteristics of Patients with Brain Metastasis Secondary to Pancreatic Ductal Adenocarcinoma. *The Oncologist*, **30**, oyae182. <https://pmc.ncbi.nlm.nih.gov/articles/PMC11783327/> <https://doi.org/10.1093/oncolo/oyae182>
- [5] Gouton, E., Gilibert, M., Launay, S., Loir, E., Tyran, M., Rochigneux, P., *et al.* (2024)

- Management and Outcomes of Brain Metastases from Pancreatic Adenocarcinoma: A Pooled Analysis and Literature Review. *Frontiers in Oncology*, **13**, Article 1326676. <https://doi.org/10.3389/fonc.2023.1326676>
- [6] Paik, W.H., Jang, D.K. and Lee, J.K. (2018) The Role of Genetic Mutation in the Pathogenesis of Pancreatitis. *The Korean Journal of Pancreas and Biliary Tract*, **23**, 49-53. <https://doi.org/10.15279/kpba.2018.23.2.49>
- [7] Ou, K., Liu, X., Li, W., Yang, Y., Ying, J. and Yang, L. (2021) ALK Rearrangement-positive Pancreatic Cancer with Brain Metastasis Has Remarkable Response to ALK Inhibitors: A Case Report. *Frontiers in Oncology*, **11**, Article 724815. <https://doi.org/10.3389/fonc.2021.724815>
- [8] Matsumoto, H. and Yoshida, Y. (2015) Brain Metastasis from Pancreatic Cancer: A Case Report and Literature Review. *Asian Journal of Neurosurgery*, **10**, 35-39. <https://doi.org/10.4103/1793-5482.151507>
- [9] Ramalingam, S., Skoulidis, F., Govindan, R., Velcheti, V., Li, B., Besse, B., et al. (2021) P52.03 Efficacy of Sotorasib in *KRAS* p.G12C-Mutated NSCLC with Stable Brain Metastases: A Post-Hoc Analysis of Codebreak 100. *Journal of Thoracic Oncology*, **16**, S1123. <https://doi.org/10.1016/j.jtho.2021.08.547>
- [10] Go, P.H., Klaassen, Z., Meadows, M.C. and Chamberlain, R.S. (2011) Gastrointestinal Cancer and Brain Metastasis. *Cancer*, **117**, 3630-3640. <https://doi.org/10.1002/cncr.25940>
- [11] Sarantis, P., Koustas, E., Papadimitropoulou, A., Papavassiliou, A.G. and Karamouzis, M.V. (2020) Pancreatic Ductal Adenocarcinoma: Treatment Hurdles, Tumor Microenvironment and Immunotherapy. *World Journal of Gastrointestinal Oncology*, **12**, 173-181. <https://doi.org/10.4251/wjgo.v12.i2.173>
- [12] He, C., Huang, X., Zhang, Y., Lin, X. and Li, S. (2021) The Impact of Different Metastatic Patterns on Survival in Patients with Pancreatic Cancer. *Pancreatology*, **21**, 556-563. <https://doi.org/10.1016/j.pan.2021.01.014>
- [13] Sasaki, T., Sato, T., Nakai, Y., Sasahira, N., Isayama, H. and Koike, K. (2019) Brain Metastasis in Pancreatic Cancer: Two Case Reports. *Medicine*, **98**, e14227. <https://doi.org/10.1097/md.000000000014227>