

The Effects of Mild-Hyperbaric Oxygen Therapy on Cognitive Function and Symptom Relief in a 35-Year-Old Male with Post-Concussive Symptoms Following a Motor Vehicle Accident: A Case Report

Daniel Bricker^{1,2*}, William Sealy Hambright², Julian Alberto¹, Syed Asad¹

¹Universal Neurological Care, Jacksonville, Florida, USA

²Base State Longevity, Aspen, Colorado, USA

Email: *daniel.bricker@universalneurocare.com

How to cite this paper: Bricker, D., Hambright, W.S., Asad, S. and Alberto, J. (2025) The Effects of Mild-Hyperbaric Oxygen Therapy on Cognitive Function and Symptom Relief in a 35-Year-Old Male with Post-Concussive Symptoms Following a Motor Vehicle Accident: A Case Report. *Case Reports in Clinical Medicine*, 14, 15-24. <https://doi.org/10.4236/crcm.2025.141003>

Received: December 2, 2024

Accepted: January 7, 2025

Published: January 10, 2025

Copyright © 2025 by author(s) and Scientific Research Publishing Inc. This work is licensed under the Creative Commons Attribution International License (CC BY 4.0).

<http://creativecommons.org/licenses/by/4.0/>



Open Access

Abstract

This case report examines the impact of mild hyperbaric oxygen therapy (mHBOT) on cognitive function and symptom relief in a 35-year-old male presenting with concussive symptoms (CS) following a motor vehicle accident (MVA). The patient underwent 10 mHBOT sessions over five weeks (40 minutes per session at 1.5 ATA with 32% oxygen). Post-treatment assessments revealed significant improvements, including an increase in P300 voltage from 4.2 μ V to 9.2 μ V, aligning with the normative range of 8 - 21 μ V. Electroencephalogram (EEG) analysis demonstrated enhanced alpha and theta band activity, reflecting improved cognitive processing and attentional regulation. Clinically, the patient reported reduced headache severity, improved sleep quality, and decreased pain intensity. These findings suggest that mHBOT may support neuroplasticity, mitigate inflammation, and restore cognitive function in patients with CS. Further research, including randomized controlled trials (RCTs), is warranted to validate mHBOT's efficacy and explore its long-term benefits in traumatic brain injury (TBI) rehabilitation.

Keywords

Mild-Hyperbaric Oxygen, Post-Concussion Syndrome, Holistic Intervention, Cognitive Recovery, Traumatic Brain Injury

1. Introduction

Traumatic brain injury (TBI) represents a significant public health challenge and

is a leading cause of persistent cognitive and neurological impairments [1]. According to the Centers for Disease Control and Prevention (CDC), approximately 2.87 million TBI-related emergency department visits, hospitalizations, and deaths occur annually in the United States, underscoring its prevalence and societal burden [2]. Concussive symptoms (CS) are a frequent consequence of TBI, manifesting as persistent headaches, memory deficits, mood disturbances, and sleep disruptions that collectively diminish quality of life [1]. Despite the widespread occurrence of CS, current treatment options remain limited, often addressing only symptomatic relief rather than the underlying pathophysiological mechanisms [1].

Mild hyperbaric oxygen therapy (mHBOT) has emerged as a promising intervention for CS and TBI. Under normal conditions (1.0 ATA), air contains approximately 20% oxygen: in this study, mHBOT increased oxygen concentration to 32% at 1.5 ATA in a pressurized chamber. This protocol enhances oxygen delivery to hypoxic tissues, promoting neuroplasticity, angiogenesis, and cellular repair [3]-[5]. Preliminary evidence suggests that mHBOT can improve cognitive function, reduce neuroinflammation, and alleviate symptoms of CS, with significant improvements observed in post-concussive symptoms and quality of life in a small cohort of military veterans with TBI [6]. However, while these findings are encouraging, additional research is needed to validate mHBOT's efficacy and establish standardized treatment protocols.

This case report investigates the therapeutic potential of mHBOT in a 35-year-old male with CS, evaluating both objective neurophysiological measures (P300 and EEG analyses) and subjective symptom improvements to assess treatment efficacy.

2. Case Presentation

The patient is a 35-year-old African American male who sought treatment after a motor vehicle accident in June 2024. The patient was still experiencing post-concussive symptoms one month after the injury. Having symptoms more than 1 month after brain injury indicates someone will more than likely experience long-term symptoms. The accident resulted in significant head trauma, although there was no loss of consciousness. In the weeks following the incident, the patient developed persistent symptoms, including daily headaches, cognitive impairment (difficulty concentrating and memory lapses), and musculoskeletal pain, particularly in the lower back. Additionally, the patient reported fragmented sleep patterns, including frequent nighttime awakenings and difficulty initiating and maintaining sleep. The patient was a healthy individual with no significant past medical history, pre-existing conditions, or use of medications prior to the onset of post-concussive symptoms.

Before initiating hyperbaric oxygen therapy (mHBOT), the patient was undergoing physical therapy for musculoskeletal pain but had not pursued pharmacological treatments for his cognitive symptoms or other issues. On initial assessment, the patient reported severe headache intensity (9/10 on the pain scale), substantial cognitive dysfunction that interfered with daily activities, and significant lower

back pain (9/10). Sleep quality was also markedly poor and fragmented.

Given these findings, a treatment plan was developed to include 10 mHBOT sessions to evaluate its potential impact on cognitive function and symptom relief. Each session consisted of 40 minutes of oxygen therapy at a pressure of 1.5 ATA, administered twice weekly over five weeks. No additional interventions were introduced during the treatment period, allowing for focused monitoring of symptom progression and cognitive performance changes.

3. Methods

Rationale for mHBOT Protocol

The mHBOT protocol utilized in this study delivered 32% oxygen at 1.5 ATA, a concentration naturally achieved due to the increased ambient pressure within the chamber. This level of oxygen concentration enhances oxygen diffusion into tissues, promoting neurogenic activity and aiding in the recovery of neural function post-trauma. The pressure setting of 1.5 ATA was chosen based on its established safety profile and efficacy in addressing post-concussive symptoms. The protocol of 10 sessions aligns with the clinic's minimum standard, designed to ensure sufficient exposure for therapeutic benefits while remaining practical for patients. This combination of pressure, oxygen concentration, and session frequency provides an optimal balance for recovery from TBI.

Assessments

To evaluate cognitive function and brain activity, pre- and post-treatment assessments were conducted using the WAVi EEG system. Electroencephalographic (EEG) data were collected using the WAVi EEG system. This system was chosen for its comprehensive spectrum of analyses, allowing for a detailed evaluation of cortical function and adaptability following traumatic brain injury (TBI). It provided valuable insights into neurophysiological changes associated with cognitive processes, making it particularly well-suited for assessing the impact of mild hyperbaric oxygen therapy (mHBOT). Given the neurogenic and oxygenation benefits associated with mHBOT, the WAVi EEG system enabled the capture of potential improvements in cortical recovery and cognitive flexibility.

The P300 test, an event-related potential (ERP) assessment, measured cognitive processing speed and working memory. Low P300 amplitudes are commonly associated with cognitive impairment, whereas increases in amplitude after treatment suggest enhanced attention and memory processing [7].

The Flanker Task evaluated cognitive flexibility and inhibitory control by requiring the patient to focus on a central target while disregarding distractors. Performance was assessed through reaction times and error rates, providing insights into attentional regulation and the ability to inhibit irrelevant stimuli [8].

The Trail Making Test assessed processing speed, cognitive flexibility, and executive function. Part A involved sequentially connecting numbers, while Part B required alternating between numbers and letters, measuring task-switching abilities and flexible thinking [9].

The Eyes Open Resting State Test established a baseline measure of brain activity. This test recorded the patient's brain wave patterns while in a relaxed state, offering insights into overall neural efficiency and cognitive functioning [1] [10].

In addition to these objective measures, subjective symptom reports were collected verbally from the patient throughout the treatment period. Weekly evaluations assessed headache severity, sleep quality, pain intensity, and cognitive challenges such as concentration and memory difficulties.

4. Results

The patient's baseline P300 voltage was recorded at 4.2 μV , below the reference range of 8 - 21 μV , indicating cognitive processing deficits. Following 10 sessions of mild Hyperbaric Oxygen Therapy (mHBOT), the P300 voltage increased to 9.2 μV , within the reference range, reflecting significant improvement in cognitive processing.

Performance on the Flanker Task also showed notable improvements. The patient demonstrated faster reaction times and fewer errors after mHBOT, indicating enhanced cognitive flexibility and attentional control [11].

The Trail Making Test revealed a 23% improvement in completion time for Part A and a 30% faster completion time for Part B, with a reduction in errors. These results suggest enhanced cognitive flexibility and processing speed [9].

Resting-state EEG recordings indicated increased alpha and theta wave activity after treatment, signifying improved cognitive processing and neural efficiency [11] [12]. The post-treatment EEG demonstrated greater brain wave stability and more regulated responses, highlighting the positive effects of mHBOT on brain function.

In terms of subjective symptom relief, the patient reported a significant reduction in headache severity, from 9/10 to 3/10, and a decrease in lower back pain, from 9/10 to 4/10. Sleep quality improved markedly, with fewer nocturnal awakenings and longer periods of restorative sleep. Cognitive difficulties, including issues with focus and memory, were alleviated, enabling the patient to perform daily activities more effectively.

Significant changes were observed in the Central-Parietal (CZ, PZ, CPZ) regions, where post-treatment amplitude increases were most pronounced. This shift indicates enhanced neural activity and improved cortical efficiency in these areas, which are critical for cognitive integration, decision-making, and sustained attention [1]. The frontal regions (FP1, FP2, FZ) also exhibited amplitude gains, suggesting broader improvements in executive functions such as task prioritization and response regulation [12].

The accompanying neural activity map reveals a global pattern of improvement following treatment, with regions previously exhibiting low activity transitioning to higher activation states. These changes align with the functional benefits observed, including enhanced attentional focus, memory recall, and processing speed [7]. The visual map serves to complement the quantitative findings in **Table 1**, further validating the efficacy of the intervention.

Table 1. Pre- and post-treatment magnitude band values (theta and alpha).

LOC	Pre-Treatment Alpha (μV)	Post-Treatment Alpha (μV)	Pre-Treatment Theta (μV)	Post-Treatment Theta (μV)
FP1	11	17	8	14
FP2	10	18	7	13
F3	11	20	6	12
F4	11	20	6	12
F7	9	15	5	10
F8	9	16	5	11
C3	11	19	7	14
C4	12	19	8	14
P3	15	28	10	22
P4	13	28	9	22
O1	18	31	12	25
O2	14	27	11	24
T3	9	14	5	9
T4	9	16	5	10
T5	15	25	8	16
T6	11	27	7	17
FZ	11	21	7	15
CZ	12	23	8	16
PZ	16	33	11	22

This table displays the quantitative changes in theta (4.5 - 7.5 Hz) and alpha (8.0 - 13.0 Hz) magnitude bands across 19 electrode sites, recorded during sessions in August and September 2024. The values represent the total peak-to-peak microvolts (μV) within each frequency band, comparing baseline (Session 1) and post-intervention (Session 2) recordings.

Key trends highlight significant increases in both alpha and theta activity following treatment, particularly in the parietal (P3, P4, PZ) and occipital (O1, O2) regions, with some areas showing over a 70% increase in alpha activity. Similarly, theta activity in the central-parietal (CZ, PZ) regions exhibited a 100% rise, indicating substantial neural changes after the intervention [11] [12].

These enhancements suggest improved attentional focus, cognitive flexibility, and memory integration. Theta activity is associated with working memory and emotional processing, while alpha activity is linked to relaxation, creative problem-solving, and task engagement [7]. Notably, changes in the frontal (FP1, FP2) regions underscore the broader impact of the intervention on executive functions and self-regulation [7].

The accompanying color map visually highlights the magnitude of these changes, with warmer hues indicating increases compared to baseline. The table provides a solid numerical foundation for interpreting these shifts in brain activity, reinforcing the intervention's efficacy in enhancing cortical efficiency and cognitive processing [11].

Alpha band activity, which is primarily linked to relaxed wakefulness, attention regulation, and memory integration, showed significant post-treatment increases, especially in the parietal (P3, P4, PZ) and occipital (O1, O2) regions [5]. These results, as shown in **Figure 1**, highlight improvements in cognitive efficiency and an enhanced capacity to maintain focused attention during task performance, with some areas demonstrating increases exceeding 70% [7].

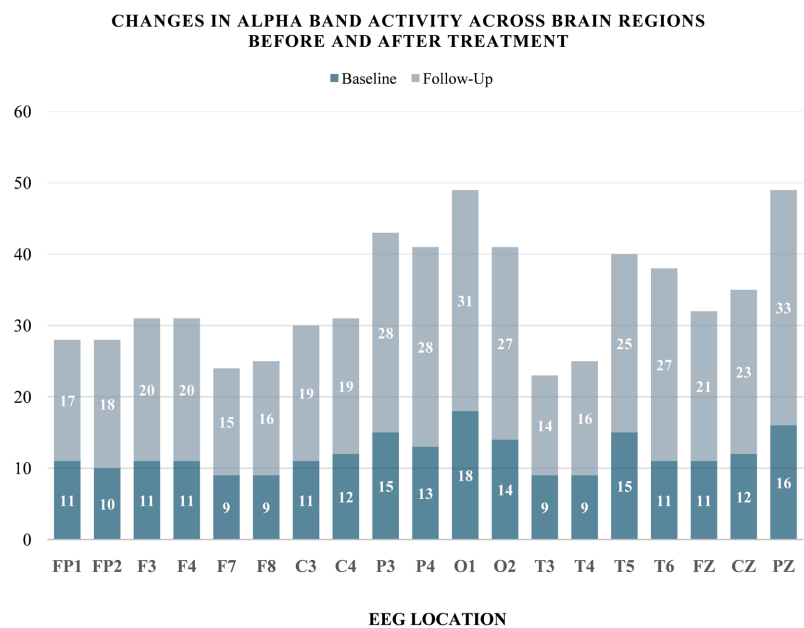


Figure 1. Alpha band activity across brain regions (pre- and post-treatment). This figure presents the changes in alpha band magnitudes across 19 brain regions, comparing EEG measurements recorded pre- and post-treatment.

Theta band activity, which is linked to memory encoding, emotional regulation, and problem-solving, demonstrated an even more pronounced improvement, with increases exceeding 100% in the central (CZ, C3, C4) and parietal (P3, PZ) regions. These findings, as illustrated in **Figure 2**, reflect heightened cortical engagement and integration, which are critical for tasks requiring deep cognitive processing and memory recall [11] [12].

The post-treatment gains in both bands were observed across the majority of regions, with particularly strong effects in regions critical for integrating sensory input and higher-order processing [11] [12]. The results visually reinforce the study's findings that mHBOT contributes to measurable neural improvements, enhancing cognitive flexibility, attentional focus, and memory consolidation [11].

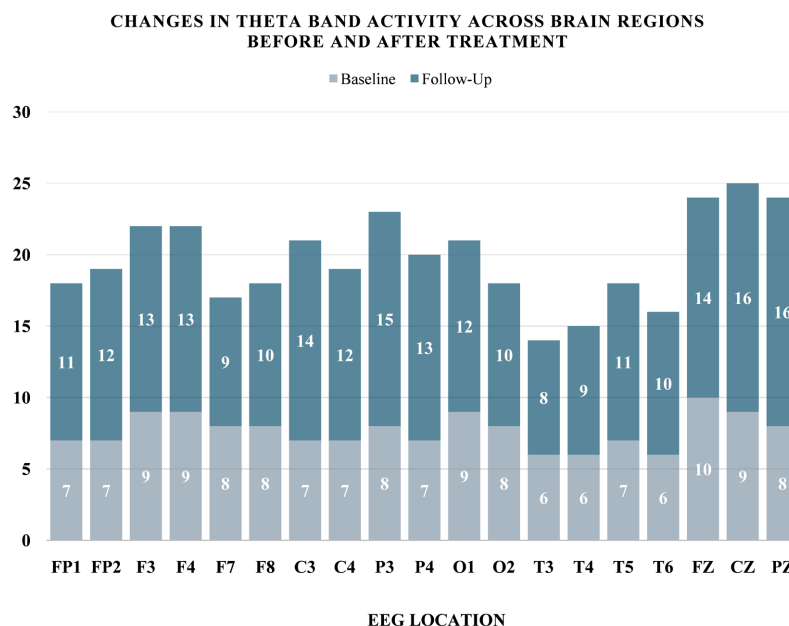


Figure 2. Theta band activity across brain regions (pre- and post-treatment). This figure illustrates the changes in theta band magnitudes across 19 brain regions as measured by EEG before and after treatment.

5. Symptom Improvement

In addition to the neurophysiological improvements, the patient reported significant subjective symptom relief. The severity and frequency of headaches decreased significantly, with pain intensity dropping from 9/10 to 3/10 by the end of the treatment period. Sleep quality also improved, with reduced nocturnal awakenings and increased total sleep time. Additionally, the patient's lower back pain decreased from 9/10 to 4/10, indicating alleviation of musculoskeletal symptoms as well.

6. Discussion

The 118% increase in P300 voltage, from 4.2 μ V to 9.2 μ V, is a notable improvement that reflects better cognitive efficiency. P300 amplitude is associated with attention, memory, and cognitive resource allocation [7]. This increase in voltage suggests enhanced processing speed, working memory, and attentional capacity, consistent with the patient's reported improvements in mental clarity and task recall [13].

The significant rise in alpha band activity across all brain regions, especially in the parietal and occipital areas, suggests enhanced cortical efficiency and attentional regulation [11] [12]. The alpha band is generally associated with calm, focused attention, which likely contributed to the patient's improvements in cognitive clarity and attention. Additionally, the rise in theta band activity, particularly in the central and parietal regions, further supports the idea that mHBT contributed to enhanced working memory and cognitive integration [13]. These

neurophysiological changes reflect the benefits of mHBOT in promoting neuroplasticity and cognitive recovery following traumatic brain injury [1].

Beyond the objective findings, the patient reported significant relief from headaches, reduced pain intensity, and improved sleep quality. These subjective improvements, especially in sleep and pain, suggest that mHBOT not only enhanced cognitive function but also alleviated physical symptoms typically associated with concussive symptoms [14].

The mechanisms behind the cognitive and symptom relief observed are likely multifactorial. mHBOT increases oxygen delivery to the brain, which may reduce inflammation, promote neuronal repair, and enhance neurogenesis [14]. Furthermore, mHBOT's effects on improving mitochondrial function and promoting cellular repair may contribute to the observed cognitive improvements [15].

While this case report demonstrates significant improvements following ten sessions of mHBOT, long-term follow-up at intervals such as 3, 6, and 12 months would provide valuable insights into the durability of treatment effects. Such follow-up is recommended for future studies to evaluate the sustained impact of mHBOT on post-concussive symptoms.

7. Conclusions

This case report demonstrates the significant benefits of mHBOT in improving cognitive function and providing relief from symptoms in a patient with concussive symptoms following a motor vehicle accident. The increase in P300 voltage and magnitude band activity, particularly in the alpha and theta bands, indicates that mHBOT can enhance neurocognitive function [2] [9]. These findings are further validated by the patient's subjective reports of reduced headache frequency, pain intensity, and enhanced sleep quality. The observed neurophysiological changes likely reflect improvements in neuroplasticity and brain repair, facilitated by increased oxygenation through mHBOT [3].

While this case report is limited by the absence of a control group, it provides compelling evidence for the potential of mHBOT as an adjunctive treatment for concussive symptoms. Further research, particularly randomized controlled trials with larger sample sizes and higher oxygen concentrations, is needed to confirm these findings and explore the long-term effects of mHBOT on cognitive recovery and symptom management in concussive symptoms.

Limitations

This study was limited by a small sample size, a lack of long-term follow-up, and the focus on a single intervention modality, which may limit generalizability. Further research with larger sample sizes and a control group is recommended to validate the findings.

Consent

Written informed consent was obtained from the patient for the publication of

this case report, including the use of clinical data and accompanying figures.

Acknowledgements

The authors wish to acknowledge the contributions of the patient for his participation and cooperation throughout the course of treatment.

Data Availability Statement

The data that support the findings of this study are available from the corresponding author upon reasonable request.

Conflicts of Interest

The authors declare no conflicts of interest regarding the publication of this paper.

References

- [1] Barry, R.J., Clarke, A.R., Johnstone, S.J., Magee, C.A. and Rushby, J.A. (2007) EEG Differences between Eyes-Closed and Eyes-Open Resting Conditions. *Clinical Neurophysiology*, **118**, 2765-2773. <https://doi.org/10.1016/j.clinph.2007.07.028>
- [2] Bennett, M.H., Trytko, B. and Jonker, B. (2012) Hyperbaric Oxygen Therapy for the Treatment of Traumatic Brain Injury: A Systematic Review of Randomized Controlled Trials. *CNS Neuroscience & Therapeutics*, **18**, 208-216.
- [3] Bowie, C.R. and Harvey, P.D. (2006) Administration and Interpretation of the Trail Making Test. *Nature Protocols*, **1**, 2277-2281. <https://doi.org/10.1038/nprot.2006.390>
- [4] Dang, B., Chen, W., He, W. and Chen, G. (2017) Rehabilitation Treatment and Progress of Traumatic Brain Injury Dysfunction. *Neural Plasticity*, **2017**, Article ID: 1582182. <https://doi.org/10.1155/2017/1582182>
- [5] Harch, P.G., Andrews, S.R., Fogarty, E.F., Amen, D., Pezzullo, J.C., Lucarini, J., *et al.* (2012) A Phase I Study of Low-Pressure Hyperbaric Oxygen Therapy for Blast-Induced Post-Concussion Syndrome and Post-Traumatic Stress Disorder. *Journal of Neurotrauma*, **29**, 168-185. <https://doi.org/10.1089/neu.2011.1895>
- [6] Kinder, K.T., Buss, A.T. and Tas, A.C. (2022) Tracking Flanker Task Dynamics: Evidence for Continuous Attentional Selectivity. *Journal of Experimental Psychology: Human Perception and Performance*, **48**, 771-781. <https://doi.org/10.1037/xhp0001023>
- [7] Klimesch, W. (1999) EEG Alpha and Theta Oscillations Reflect Cognitive and Memory Performance: A Review and Analysis. *Brain Research Reviews*, **29**, 169-195. [https://doi.org/10.1016/s0165-0173\(98\)00056-3](https://doi.org/10.1016/s0165-0173(98)00056-3)
- [8] Mckee, A.C. and Daneshvar, D.H. (2015) The Neuropathology of Traumatic Brain Injury. *Handbook of Clinical Neurology*, **127**, 45-66. <https://doi.org/10.1016/b978-0-444-52892-6.00004-0>
- [9] Ortega, M.A., Fraile-Martinez, O., García-Montero, C., Callejón-Peláez, E., Sáez, M.A., Álvarez-Mon, M.A., *et al.* (2021) A General Overview on the Hyperbaric Oxygen Therapy: Applications, Mechanisms and Translational Opportunities. *Medicina*, **57**, Article 864. <https://doi.org/10.3390/medicina57090864>
- [10] Polich, J. (2020) P300 Clinical Applications: A Review. *Journal of Clinical Neurophysiology*, **37**, 431-436.
- [11] Qu, C., Xu, M., Lorenzo, S., Huang, P., Rao, Z., Geng, X., *et al.* (2024) Effects of Mild

- Hyperbaric Oxygen Therapy on Timing Sequence Recovery of Muscle Fatigue in Chinese University Male Athletes. *Journal of Exercise Science & Fitness*, **22**, 305-315.
<https://doi.org/10.1016/j.jesf.2024.04.005>
- [12] Rueda, M. R., Posner, M. I., & Rothbart, M. K. (2004). Attentional control and self-regulation. In: Baumeister, R.F. and Vohs, K.D., Eds., *Handbook of Self-Regulation: Research, Theory, and Applications*, The Guilford Press, 284-299.
<https://psycnet.apa.org/record/2004-00163-013>
- [13] Shandley, S., Wolf, E., Schubert-Kappan, C.M., *et al.* (2017) Increased Circulating Stem Cells and Better Cognitive Performance in Traumatic Brain Injury Subjects Following Hyperbaric Oxygen Therapy. *Frontiers in Psychology*, **8**, Article 896.
- [14] Smith, E.E., Tenke, C.E., Deldin, P.J., Trivedi, M.H., Weissman, M.M., Auerbach, R.P., *et al.* (2019) Frontal Theta and Posterior α in Resting EEG: A Critical Examination of Convergent and Discriminant Validity. *Psychophysiology*, **57**, e13483.
<https://doi.org/10.1111/psyp.13483>
- [15] Taylor, C.A., Bell, J.M., Breiding, M.J. and Xu, L. (2017) Traumatic Brain Injury-related Emergency Department Visits, Hospitalizations, and Deaths—United States, 2007 and 2013. *MMWR. Surveillance Summaries*, **66**, 1-16.
<https://doi.org/10.15585/mmwr.ss6609a1>